

EUROSON 2023

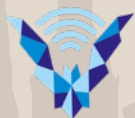ABSTRACT BOOK



Latvijas
Ultrasonogrāfistu
asociācija

EFSUMB

European Federation of Societies for Ultrasound in Medicine and Biology



STUDENT IUSC

WWW.EUROSON2023.COM

Table of contents

Correlation of 3D Ultrasound and Histopathology on Ex-vivo Tongue Tumor Specimen	17
<i>Fatemeh Makouei</i> , Department of Otorhinolaryngology, Head and Neck Surgery & Audiology, Rigshospitalet University of Copenhagen, Denmark, Copenhagen, Denmark, Denmark	
Mn-based conjugated mimetic enzyme combines HIFU forenhanced histotripsy to treat hepatocellular carcinoma	19
<i>Liao Min Liao</i> , West China Hospital of Sichuan University, China	
2D Versus 3D Dynamic Contrast-Enhanced Ultrasound for Early Assessment of Treatment Response in Metastatic Liver Lesions	20
<i>Ahmed El Kaffas</i> , Stanford University, United States of America	
HCCs lacking arterial phase hyperenhancement (APHE) on CEUS – findings from the prospective multicentre DEGUM CEUS HCC trial	21
<i>Deike Strobel</i> , Department of Internal Medicine 1, Erlangen University Hospital, Friedrich Alexander University (FAU) Erlangen-Nurnberg, Germany	
Endoscopic ultrasound as a perfect solution for pancreatic cancer	22
<i>Benahmed Amina</i> , University of mostaganem Faculty of biology, Algeria	
Pancreatic neuroendocrine tumors: Correlation between dynamic contrast enhanced ultrasound and pathological tumor grades	23
<i>Yi Dong</i> , Department of Ultrasound, Xinhua Hospital affiliated to Shanghai Jiaotong University School of Medicine, China	
An unusual ultrasound discovery – MALT lymphoma of the terminal ileum	24
<i>Mihaela Tanco</i> , Ovidius University of Constanta, Romania	
Kinetic Modeling to Estimate Uptake Rate of Microbubbles in Axillary Sentinel Lymph Nodes Using Lymphosonography	25
<i>Priscilla Machado</i> , Thomas Jefferson University, United States of America	
Rabbit's lung hemorrhage induced by ultrasound with long pulse duration	26
<i>Iwaki Akiyama</i> , Doshisha University, Japan	
Energy consumption of ultrasound devices and the potential to save energy in German hospitals	27
<i>Mark M. Haenle</i> , Ulm University Hospital, Department of Internal Medicine I, Ulm, Germany	
Spinal Device for Ultrasound-Triggered Drug Release Evaluated in Small and Large Animal Models	28
<i>Flemming Forsberg</i> , Thomas Jefferson University, United States of America	

PRELIMINARY RESULTS OF A HYBRID APPLICATION OF ULTRASOUND WITH AN ADVANCED SYSTEM FOR CUSTOMIZED REHABILITATION	29
<i>Alexandra André</i> , Polytechnic of Coimbra, Health School, Rua 5 de Outubro, 3045-043 Coimbra, Portugal, Portugal	
Development of an artificial intelligence procedure for detecting and classifying ultrasound artifacts in real-time	31
<i>Kollmann Christian</i> , Center for Medical Physics & Biomedical Engineering, Medical University of Vienna, Waehringer Guertel 18-20, 1090 Vienna, Austria, Austria	
Characterizing the Status of Sentinel Lymph Nodes with Lymphosonography and Deep-Learning Compared to Radiologist's	32
<i>Priscilla Machado</i> , Thomas Jefferson University, United States of America	
Ultrasound-Triggered Drug Release System to Combat Post-Surgical Infections: In Vitro Evaluations	33
<i>Flemming Forsberg</i> , Thomas Jefferson University, United States of America	
Has lung ultrasound become the new game changer?	34
<i>Rafal Rajski</i> , Faculty of Medicine of the University of Opole, Poland	
The use of ultrasound in battlefield environment during the Russian invasion of Ukraine	35
<i>Vitalii Lukianchuk</i> , Ministry of Defense of Ukraine, military hospital, Ukraine	
Musculoskeletal Ultrasound – The Advantages of Ultrasound in Fractures Management	38
<i>Stoicescu Emil Robert</i> , Discipline of Radiology and Medical Imaging, "Victor Babes" University of Medicine and Pharmacy Timisoara, Romania	
Noninvasive Ultrasound Techniques to Diagnose Chronic Exertional Compartment Syndrome: A Pilot Clinical Trial	41
<i>Corinne E. Wessner</i> , Department of Radiology, Thomas Jefferson University, Philadelphia, PA, 19107,, United States of America	
Ultrasonic Time-Harmonic Shear Wave Elastography of the Vastus Medialis	42
<i>Pascal Engl</i> , Merseburg University of Applied Sciences, Eberhard-Leibnitz-Str. 2, 06217 Merseburg, Germany, Germany	
Ultrasound imaging of the combat-related soft tissue trauma in Ukrainian soldiers	43
<i>Kitija Nulle</i> , Riga East Clinical University hospital, Latvia	
Characterization of Complex ovarian masses on Ultrasound Molecular Imaging and Correlation with Surgical Histopathology	45
<i>Ahmed El Kaffas</i> , Stanford University, United States of America	
Shear wave ultrasound elastography of malignant breast lesions: Measured values with different region of interest and lesion size	46
<i>Antonio Bulum</i> , University hospital Dubrava, Zagreb, Croatia, Croatia	

Unnecessary Biopsy Rates of BIRADS-4a Lesions: Can Elastography Decrease the Rates?	48
<i>Düzgün CanŞenbil</i> , Erzincan Binali Yıldırım University Faculty of medicine, Turkey	
ULTRASOUND SHARE WAVE ELASTOGRAPHY (2D-SWE) IN THE DIAGNOSIS AND EVALUATION OF VITEX AGNUS-CASTUS TREATMENT MYSTODYNIA AND MASTOPATHY	49
<i>Zhanna Makarova</i> , Director, Ukraine	
Breast Cancer of Young Women. Prevention, Problems of Pregnancy and Lactation. Retrospective study	50
<i>Jana Slobodníková</i> , radiologist, Slovakia	
Protocol of breast cancer prevention model with addition of breast ultrasound to routine gynecological visits in patients 25-49 years old.	51
<i>Marcin Sniadecki</i> , Medical University of Gdańsk, Poland	
Dynamic ultrasound imaging of the ulnar nerve movement at the level of elbow: sonoanatomy and associated findings	52
<i>Kitija Nulle</i> , RAKUS "Gaiļezers", Latvia	
Ultrasonographic evaluation of post-traumatic changes in carotid and vertebral arteries.	54
<i>Mateusz Cheda</i> , Department of Interventional Radiology and Neuroradiology, Medical University of Lublin, Poland	
Carotid Plaque Instability and Neovascularization Assessment with Contrast - Enhanced Ultrasound (CEUS) and Superb Microvascular Imaging	55
<i>Andrejs Lioznovs</i> , Pauls Stradins Clinical University Hospital, Riga, Latvia; Riga Stradins University, Riga, Latvia, Latvia	
Analysis of neovascularization in carotid atherosclerotic plaque in patients with cerebral infarction by contrast-enhanced ultrasound	58
<i>Juan Cheng</i> , Xinhua Hospital Affiliated to Shanghai Jiaotong University School of Medicine, China	
DOPPLER ULTRASOUND IN PARENCHYMAL EMERGENCIES: KNOW-HOW AND INTERPRETION	59
<i>Francesca De Chiara</i> , Department of Medicine and Health Sciences "V. Tiberio", University of Molise, Campobasso, Italy	
Ultrasound Diagnosis of Gastroesophageal Reflux Disease	60
<i>Elene Khmaladze</i> , Tbilisi State University Clinic Vivamed, Georgia	
Advanced 3D transrectal ultrasound for evaluation of perianal fistulas, tumors and anal sphincters.	62
<i>Nerijus Teresius</i> , Vilnius University Hospital Santaros Clinics, Lithuania	

Contrast-enhanced ultrasound compared with endoscopy in Crohn's disease	64
<i>Kim Nylund</i> , National Centre for Ultrasound in Gastroenterology, Haukeland University Hospital, Bergen, Norway, Norway	
Ultrasound shear wave elastography based non-invasive diagnosis of Chronic Pancreatitis: a prospective cohort feasibility	65
<i>Carlo Felix Maria Jung</i> , Gastroenterology and Digestive Endoscopy Unit, Forlì-Cesena Hospitals, AUSL Romagna, Forlì-Cesena, Italy. , Italy	
Ultrasound assessment of the cholecystolithotomy effect on the structural and functional properties of the gallbladder	67
<i>Oleksandr Babii</i> , Department of Surgery of digestive organs, SI "Institute of gastroenterology of NAMS of Ukraine", Dnipro., Ukraine	
Ultrasound features of Helicobacter Pylori related gastritis	68
<i>Fulvia Terracciano</i> , IRCCS CASA SOLLIEVO DELLA SOFFERENZA, Italy	
Acute pathology of the gallbladder, its ultrasound diagnosis and the most common pitfalls	70
<i>Dovile Volodkoviciene</i> , Vilnius University hospital Santaros Klinikos, Lithuania	
Could venous impedance index be more helpful than arterial resistive index in the evaluation of renal obstruction? Preliminary results	71
<i>Dalila De Lucia</i> , Department of Medicine and Health Sciences "V.Tiberio" University of Molise, Italy	
Evaluation of intra- and interobserver variability attenuation coefficient measurement (ACM) for the assessment of hepatic steatosis	72
<i>Maksym Zhaivoronok</i> , Department of Nuclear Medicine, Radiation Oncology and Radiation Safety of Shupyk National Healthcare University of Ukraine, Kyiv, Ukraine, Ukraine	
Focal liver observations not visualized on grayscale ultrasound prior to performing CEUS: Analysis from a prospective multicenter trial	73
<i>Corinne Wessner</i> , Thomas Jefferson University Hospital, Philadelphia PA, United States of America	
Terminology of multiparametric ultrasound (mp-US) of chronic diffuse liver diseases (CDLD)	74
<i>Oleh Dynnyk</i> , "Institute of elastography" Medical center LLC, Kyiv, Ukraine, Ukraine	
Assessment of New Ultrasound-based Methods for Liver Steatosis Quantification as compared to Controlled Attenuation Parameter	75
<i>Alina Popescu</i> , "Victor Babes" University of Medicine Timisoara. 2Center for Advanced Hepatology Research of the Academy of Medical Sciences, Timișoara , Romania	
Liver steatometry: possibilities of implementation for patients with gallstone disease.	76
<i>Olga Pushkarenko</i> , Uzhhorod National University, Ukraine	

CLINICAL VALIDATION OF CEUS LI-RADS IN PROSPECTIVE MULTI-CENTER STUDY	78
<i>Andrej Lyshchik</i> , Thomas Jefferson University Hospital, United States of America	
FATTY LIVER QUANTIFICATION USING ULTRASOUND DERIVED FAT FRACTION (UDFF) AS COMPARED TO CONTROLLED ATTENUATION PARAMETER	79
<i>Sporea Ioan</i> , Department of Gastroenterology and Hepatology Victor Babes Timisoara, Romania	
Thoracic Ultrasound in Neonatal Respiratory Pathologies -A Challenging Technique	80
<i>Stoicescu Emil Robert</i> , Discipline of Radiology and Medical Imaging, "Victor Babes" University of Medicine and Pharmacy Timisoara, Romania	
Ultrasound differential diagnosis of bone lesions in children.	82
<i>Pawel Walisiewicz</i> , University Medical Center in Gdańsk, Poland	
Accessory kidney artery as a cause of extrinsic uretero-pelvic junction obstruction (UPJO) in children with hydronephrosis.	85
<i>Anna Moczulska</i> , Jagiellonian University Medical College, Dpt. of Pediatric Nephrology and Hypertension, Krakow, Poland	
Quantitative Ultrasound Fatty Liver evaluation in a Pediatric Population: comparison with Magnetic Resonance.	88
<i>Pacini Patrizia</i> , Policlinico Umberto I, Sapienza-University of Rome, Italy	
Diagnostic success of ACR TI-RADS and solid protruding component in partially cystic thyroid nodules	90
<i>Serkan Guneyli</i> , Department of Radiology, Bakircay University School of Medicine, Turkey	
Contrast-enhanced ultrasound in the evaluation of TI-RADS 3,4 and 5 thyroid nodules	91
<i>Mihaela-Maria Vlad</i> , Discipline of Endocrinology, "Victor Babes" University of Medicine and Pharmacy, Timisoara, Romania	
Diagnostic accuracy of multiparametric ultrasound in the differential diagnosis of parotid lesions compared with MRI examination	92
<i>Vincenzo Dolcetti</i> , Università degli studi di Roma - La Sapienza, Italy	
Role of US in preoperative parathyroid localization and in evaluating thyroid nodules in patients with primary hyperpara	93
<i>Alper Özel</i> , UHS Istanbul Sisli Hamidiye Etfal Health Research Center, Department of Radiology, Turkey	
Multimodal ultrasound diagnostic in hyperthyroidism cases	94
<i>STOIAN DANA</i> , Victor BABes University of MEdicine and Pharmacy, Timisoara, Romania	

The utility of Virtual Touch Imaging Quantification (VTIQ) in the thyroid nodules monitoring	95
<i>Vancu Mihaela</i> , The Center of Excellence in Ultrasonography DOCTOR VANCU, Romania	
Head and neck ultrasound training improves the diagnostic performance of otolaryngology residents	98
<i>Jens Jessen Warm</i> , Department of Otorhinolaryngology, Head and Neck Surgery & Audiology, Copenhagen University Hospital Rigshospitalet, Denmark., Denmark	
Novel elastography techniques identify fibrosis in chronic glomerulonephritis patients	99
<i>Maralescu Felix-Mihai</i> , 1.Division of Nephrology, Department of Internal Medicine II, "Victor Babeş" University of Medicine and Pharmacy, 300041 Timișoara, Romania 2. Centre for Molecular Research in Nephrology and Vascular Disease, "Victor Babeş" University of Medicine and Pharmacy, 300041 Timișoara, Romania, Romania	
Evaluation of perfusion of the transplanted kidney by CEUS and structural analysis using native MRI after transplantation.	100
<i>Dalia Mitraitė</i> , Lithuanian University of Health Sciences Kaunas Clinics hospital Radiology department, Lithuania	
Diagnostic Performance of the Bosniak 2019 Classification in Comparison with CEUS in Cystic Renal Lesions as Incidental Finding	101
<i>Giovanni Del Gaudio</i> , Sapienza University of Rome, Italy	
Practice Makes Perfect: The Effect of Work Experience in Determining Accidental Kidney Calculi	102
<i>Jurgis Petkevicius</i> , Lithuanian University of Health Sciences Kaunas Clinics, Lithuania	
Radiographers' individual perspectives on sonography - A survey of European Federation of Radiographer Societies (EFRS)	103
<i>Malene Roland Pedersen</i> , Sygehus Lillebaelt, Vejle Hospital, Beriderbakken 4, DK-7100 Vejle, Denmark	
Multiseptate "honeycomb" gallbladder - diagnostic value of contrast-enhanced ultrasound	104
<i>Katerina Lyoncheva-Kaneva</i> , Acibadem City Clinic Tokuda Hospital - Department of Gastroenterology, Bulgaria	
Sonographic diagnosis of a Pott's Puffy Tumor in a 5-year-old girl	106
<i>Dr. Marie Brandt</i> , Department of Otorhinolaryngology, Head and Neck Surgery, University Hospital of Regensburg, Germany, Germany	
Jaundice in a newborn? Ultrasound diagnosis confirmed: Biliary atresia	107
<i>Ioan Tiberiu Tofolean</i> , Ovidius University of Constanta, Romania	
Incidental Detection of Accessory Left Renal Polar Vein during Abdominal USG	108
<i>Enes Serbetci</i> , Istanbul Education and Research Hospital, Radiology Department, Turkey	

Contrast enhanced ultrasound (CEUS) for imaging and surgical planning of a second branchial cleft fistula	109
<i>Maximilian Rink</i> , Klinik und Poliklinik für Hals-, Nasen- und Ohrenheilkunde, Universitätsklinikum Regensburg, Germany	
CEUS IN THE DIAGNOSIS OF A PARATHYROID ADENOMA – CASE REPORT	110
<i>Andreea-Daniela Toma</i> , “Victor Babes” University of Medicine and Pharmacy Timisoara, Romania, Romania	
Rhabdomyolysis after intense exercise in ultrasound - case report.	113
<i>Paweł Walisiewicz</i> , University Medical Center in Gdańsk, Poland	
Thyroid volume measurement with freehand three-dimensional ultrasound compared to two-dimensional ultrasound	115
<i>Klara Bay Rask</i> , Department of Otorhinolaryngology, Head and Neck Surgery & Audiology, Rigshospitalet, Copenhagen, Denmark	
The first 5 targeted trans-perineal prostate biopsies diagnose the majority of PROMIS criteria cancer in patients with a Likert 4 or 5 score on mpMRI	116
<i>Adam Morrell</i> , Department of Radiology, St James’s University Hospital, Leeds Teaching Hospitals NHS Trust, Leeds, England , United Kingdom	
Renal elastography to predict the therapeutic response of the nephrological patient	117
<i>Nicoletta Mancianti</i> , Department of Emergency-Urgency and Transplantation, Nephrology, Dialysis and Transplantation Unit, University Hospital of Siena, Siena, Italy, Italy	
Multi-aperture ultrasound imaging and elastography of the abdominal aorta: from bench to bedside	119
<i>Vera H.J. van Hal</i> , Photoacoustics & Ultrasound Laboratory Eindhoven (PULS/e), dept. of Biomedical Engineering, Eindhoven University of Technology, De Rondom 70, 5612 AP Eindhoven, The Netherlands, Netherlands	
Infarction of regenerative nodules in liver cirrhosis after implantation of Transjugular Intrahepatic Portosystemic Shunt (TIPS)	120
<i>Fleur Sophie Gittinger</i> , Klinikum St. Georg Leipzig, Department of Gastroenterology and Hepatology, Delitzscher Str. 141, 04129 Leipzig, Germany, Germany	
Beyond Localization of Parathyroid: CEUS as Gateway to Morphology	123
<i>Sergejs Pavlovics</i> , Radiology Research Laboratory, Riga Stradins University, LV-1007 Riga, Latvia.2. Diagnostic Radiology Institute, Pauls Stradins Clinical University Hospital, LV-1002 Riga, Latvia, Latvia	
Focused lung ultrasound for in-home assessment of older adults; a pilot and feasibility study	124
<i>Siri Aas Smedemark</i> , Dept. of Geriatric Medicine, Odense University Hospital. Dept. of Clinical Research, University of Southern Denmark, Denmark	

Sonographic assessment of the transplantation-related complications in renal graft recipients	125
<i>Maryla Kuczyńska</i> , Department of Interventional Radiology and Neuroradiology, Medical University of Lublin, Lublin, Poland, Poland	
Auto Point Shear Wave Elastography and Ultrasound Derived Fat Fraction: are they promising tools to detect liver fibrosis and steatosis	126
<i>Isabel Garrido</i> , Serviço de Gastreenterologia, Centro Hospitalar Universitário de São João, Porto, Portugal, Portugal	
Liver steatosis assessment by new ultrasound-based quantitative methods	127
<i>Camelia Foncea</i> , Department of Gastroenterology and Hepatology, Department of Internal Medicine II, Center for Advanced Research in Gastroenterology and Hepatology "Victor Babes" University of Medicine and Pharmacy Timisoara , 2Center for Advanced Hepatology Research of the Academy of Medical Sciences, Timișoara. , Romania	
Aberrant right subclavian artery should not be used as a surrogate marker for aneuploidy after a normal first trimester	129
<i>Marianna Chatzioannou</i> , Alexandra Maternity Hospital, Athens University, Greece	
SonoTEAM – student networking for better ultrasound skills.	130
<i>Monika Zbroja</i> , Students' Scientific Society at the Department of Interventional Radiology and Neuroradiology, Medical University of Lublin, Poland	
Identifying advantages and disadvantages in ultrasound training of students in Germany	131
<i>Nils Daum</i> , Charité–Universitätsmedizin Berlin, corporate member of Freie Universität Berlin and Humboldt Universität zu Berlin, Germany, Germany	
Undergraduate ultrasound education in Germany – a students' perspective	132
<i>Sophie-Luise Saenger</i> , 1Technische Universität Dresden, Faculty of Medicine Carl Gustav Carus, Fetscherstr. 74, 01307 Dresden, Germany, Germany	
MOBILE OUTPATIENT ULTRASOUND DIAGNOSTICS (HHUS) IN SPECIALIZED OUTPATIENT PALLIATIVE CARE (SAPV) PERFORMED BY QUALIFIED NURSES	133
<i>David Boten Boten</i> , Brandenburg Medical University, Institut Clinical Ultrasound / BICUS Neuruppin, Germany, Germany	
Implementation of a national register for interventional ultrasound (INVUS) in Germany	134
<i>Nils Daum</i> , Brandenburg Institute for Clinical Ultrasound (BICUS), Medical University Brandenburg "Theodor Fontane", Faculty of Health Sciences, Neuruppin, Germany	
The influence of cardiovascular concomitant diseases on plaque vulnerability in CEUS assessment	135
<i>Marcin Czezelewski</i> , Students Scientific Society at the Department of Interventional Radiology and Neuroradiology, Medical University of Lublin, Poland	

Pitfalls in ADPKD complications - cyst hemorrhage diagnosed with CEUS	136
<i>Elvira-Ioana Buda</i> , George Emil Palade University of Medicine, Pharmacy, Science, and Technology of Targu Mures, Romania	
IOTA methods to distinguish between benign and malignant adnexal lesions discovered by ultrasonography	137
<i>Andreea Puiu</i> , State University of Medicine and Pharmacy "Nicolae Testemitanu", Moldova	
Gallbladder polyp - ultrasound diagnosis and management	138
<i>Danielius Nepomniščis</i> , Vilnius University Faculty of Medicine, Lithuania	
Basics of knee ultrasound examination and interesting cases from residential experience	139
<i>Monika Mikeliūnė</i> , Vilnius University Hospital Santaros Klinikos, Lithuania	
From mouth to anus – ultrasound as the leading imaging modality in the pediatric clinical setting	140
<i>Monika Zbroja</i> , Students' Scientific Society at the Department of Pediatric Radiology, Medical University of Lublin, Poland	
The use of ultrasonography in diagnosis of the most common gastrointestinal tumor in children.	141
<i>Veronika Mielnik</i> , Students' Scientific Society at the Department of Pediatric Radiology, Medical University of Lublin, Poland	
Neurosonography in neonate patients: anatomy, technique, indications and most common findings	142
<i>Ligita Bespalovaite</i> , Lithuanian University of Health Sciences, Lithuania	
Acute abdomen in pregnancy	144
<i>Giedrius Ledas</i> , Vilnius University, Lithuania	
Ultrasound BI-RADS classification	145
<i>Indrė Lekienė</i> , Vilnius University Faculty of Medicine, Lithuania	
The BICUS Ultrasound Certificate– how Students in Brandenburg can have their Ultrasound Skills Certified in the near Future	146
<i>Tamy Borbe</i> , Brandenburg Medical University Theodor Fontane, Brandenburg Institute for Clinical Ultrasound / BICUS, Neuruppin, Germany, Germany	
To puncture or not to puncture: profit-loss balance of the transplant renal biopsy. US assessment of the procedure-related complications	147
<i>Olga Pustelniak</i> , Students' Scientific Society at the Department of Interventional Radiology and Neuroradiology, Medical University of Lublin, Lublin, Poland, Poland	
INCIDENCE AND CLINICAL RELEVANCE OF INCIDENTAL FINDINGS IN UPPER GASTROINTESTINAL ENDOSCOPIC ULTRASOUND EXAMINATIONS (IFEUS)	148
<i>Isabell Zeiger</i> , Medical University Brandenburg "Theodor Fontane", Neuruppin, Germany and Brandenburg Institute for Clinical Ultrasound (BICUS), Neuruppin, Germany, Germany	

Ultrasound training in e-learning format. Is it practicable?	149
<i>David Boten</i> , Brandenburg Medical School Theodor Fontane (MHB), Campus Neuruppin, Fehrbelliner Straße 38, 16816 Neuruppin, Germany, Germany	
Analysis of the Subharmonic Response of Definity, Sonazoid, and Lumason in an In Vitro Flow System	151
<i>Hailee Mayer</i> , Department of Radiology, Thomas Jefferson University, United States of America	
Correlation between visceral and subcutaneous fat and epicardial fat in diabetics and non-diabetics – ultrasound study	152
<i>Alexandra André</i> , Polytechnic of Coimbra, Health School, Rua 5 de Outubro, 3045-043 Coimbra, Portugal, Portugal	
The assessment of liver Shear Wave Dispersion (ViPLUS) in a healthy cohort	155
<i>Alexandru Popa</i> , Division of Gastroenterology and Hepatology, Department of Internal Medicine II, Center for Advanced Research in Gastroenterology and Hepatology, “Victor Babes” University of Medicine and Pharmacy, E. Murgu Square, Nr. 2, 300041 Timisoara, Romania, Romania	
The role of breast ultrasound in breast cancer screening	157
<i>Iacob Roxana</i> , Victor Babes University of Medicine and Pharmacy Timisoara, Discipline of Radiology and Medical Imaging, Romania	
Quantification of Liver Viscosity In Type 2 Diabetes Mellitus Patients Using Ultrasound Shear Wave Dispersion (Viscosity)	159
<i>Alexandru Popa</i> , Division of Gastroenterology and Hepatology, Department of Internal Medicine II, Center for Advanced Research in Gastroenterology and Hepatology, “Victor Babes” University of Medicine and Pharmacy, E. Murgu Square, Nr. 2, 300041 Timisoara, Romania	
A national register for interventional ultrasound (INVUS) in Germany: preliminary results of a pilot study	160
<i>Eder Nicole</i> , Krankenhaus Märkisch-Oderland, Department of Internal Medicine, Strausberg/Wriezen, Germany; Brandenburg Institute for Clinical Ultrasound (BICUS), Medical University Brandenburg “Theodor Fontane”, Faculty of Health Sciences, Neuruppin, Germany, Germany	
Multiparameter contrast enhanced ultrasound is useful for detecting diffuse and focal liver lesions in patients with diabetes mellitus	162
<i>Rostyslav Bubnov</i> , Clinical Hospital “Pheophania” of State Affairs Department, Ukraine	
Ultrasound and MR neurography features of upper limb nerve injuries	163
<i>Mahesh Prakash Prakash</i> , PGIMER, India	
Shear-wave elastography and viscosity assessment in patients with chronic autoimmune thyroiditis	165
<i>Dana Stoian</i> , University of Medicine and Pharmacy Victor BAbes Timisoara, Romania	

Non-alcoholic fatty liver disease and subclinical peripheral atherosclerosis in a population affected by Familial Hypercholesterole	166
<i>Alberto Mondelli</i> , AOU Modena, Medicina Interna, Modena, Italy, Italy	
Thyroid viscosity assessment in a healthy population – a promising novel elastography-based evaluation	167
<i>Andreea Borlea</i> , University of Medicine and Pharmacy Victor Babes Timisoara, Dep Internal Medicine 2, Romania	
The place of contrast-enhanced ultrasound in assessing thyroid cartilage invasion in laryngeal cancer	168
<i>Milda Pucetaite</i> , Lithuanian University of Health Sciences, Lithuania	
Ultrasonography and contrast-enhanced ultrasonography in gastrointestinal acute graft-versus-host-disease severity quantification	169
<i>Ioanutescu Elena Simona</i> , „Carol Davila” University of Medicine and Pharmacy, Bucharest; Internal Medicine Clinic, Fundeni Clinical Institute, Bucharest, Romania	
Combined duplex ultrasound and elastography in patients with cervical lymph nodes and Covid-19 mild infection	170
<i>Doina Georgescu</i> , “V Babes” University of Medicine and Pharmacy, Timisoara, Romania	
Deep learning-based detection of vessels assisting vein cannulation procedure under ultrasound guidance	171
<i>Andrius Sakalauskas</i> , TELEMED, Ultrasound Medical Systems, Savanoriu pr. 178A, Vilnius, LT –03154, Lithuania	
A rare cause of neck mass in an adult woman-cervical thymic cyst-case report	172
<i>Golu Ioana</i> , University of Medicine and Endocrinology “Victor Babes” Timisoara, Department II, Endocrinology, Romania	
Dynamics of ultrasound parameters of carotid atherosclerosis in patients with moderate SCORE risk: 7-year follow-up data	173
<i>Olga Pogorelova</i> , NATIONAL MEDICAL RESEARCH CENTRE OF CARDIOLOGY NAMED AFTER ACADEMICIAN E.I.CHAZOV., Russia	
CEUS LI-RADS and quantification software: evaluation of the agreement in classifying liver nodules into LI-RADS classes	174
<i>Alice Giamperoli</i> , Department of Medical and Surgical Sciences, University of Bologna, 40138 Bologna, Italy., Italy	
Carotid subclinical atherosclerosis and adverse cardiovascular events: data from a 10-year follow-up	175
<i>Olga Pogorelova</i> , NATIONAL MEDICAL RESEARCH CENTRE OF CARDIOLOGY NAMED AFTER ACADEMICIAN E.I.CHAZOV., Russia	
Echogenicity of atherosclerotic plaques of carotid arteries and prognosis of cardiovascular events	176
<i>Maria Tripoten</i> , NATIONAL MEDICAL RESEARCH CENTRE OF CARDIOLOGY NAMED AFTER ACADEMICIAN E.I.CHAZOV., Russia	

Effect of Nano-Scale Phase Change Contrast Agent Activation on Hepatocellular Carcinoma Tumor Environment	178
<i>John Eisenbrey</i> , Thomas Jefferson University, United States of America	
Liver and spleen shear-wave elastography in the diagnosis and severity staging of Philadelphia-negative Myeloproliferative diseases and Myelofibrosis	179
<i>Vito Sansone</i> , Division of Internal Medicine, Hepatobiliary and Immunoallergic Diseases, IRCCS Azienda Ospedaliero-Universitaria di Bologna; Department of Medical and Surgical Sciences (DIMEC), University of Bologna, Italy	
Diagnostic lessons from Raphael's "La Fornarina" point to the potential for e-diagnosis in contemporary cases of breast cancer	181
<i>Marcin Śniadecki</i> , Department of Gynecology and Obstetrics, Medical University of Gdansk, Poland	
Complex breast cysts (CBC): ultrasound (US) or pneumocystography (PCG)	183
<i>Oleksii Aksonov</i> , National Cancer Institute, Kiev, Ukraine	
Crystal depositions assessed by ultrasound and DECT decrease during two years of treat-to-target treatment	184
<i>Hilde Berner Hammer</i> , Diakonhjemmet Hospital, Oslo, Norway	
Not all that Twinkles is Gold	186
<i>Rykiel Levine</i> , University Hospitals Cleveland Medical Center, United States of America	
Ultrasound Based Machine Learning Approach for Detection of Non-alcoholic Fatty Liver Disease	188
<i>Aylin Tahmasebi</i> , Thomas Jefferson university, United States of America	
Multiparameter contrast-enhanced ultrasound for diffuse and focal lesions of liver parenchyma in patients with diabetes mellitus	189
<i>Rostyslav Bubnov</i> , Clinical hospital "Pheophania", Ukraine	
STEATOSIS ASESMENT BY ULTRASOUND DERIVED FAT FRACTION IN PATIENTS WITH ALD	190
<i>Radu Cotrau</i> , 1 Department of Gastroenterology and Hepatology, Department of Internal Medicine II, Center for Advanced Research in Gastroenterology and Hepatology "Victor Babes" University of Medicine and Pharmacy Timisoara 2 Center for Advanced Hepatology Research of the Academy of Medical Sciences, Timișoara, Romania	
QUANTITAVE ULTRASOUND METHODS FOR THE ASSESSMENT OF LIVER STEATOSIS IN PATIENTS WITH ALD	191
<i>Anca Ariana Plopeanu</i> , Department of Gastroenterology and Hepatology, Department of Internal Medicine II, Center for Advanced Research in Gastroenterology and Hepatology "Victor Babes" University of Medicine and Pharmacy Timisoara, Romania, Romania	
Endoscopic Ultrasound-Guided Pancreatic Pseudocyst Drainage: retrospective study	192
<i>Sebastiana Atzori</i> , Azienda Ospedaliero Universitaria Sassari, Italy	

The carotid intima-media thickness and the pulse wave analysis: non-invasive methods of evaluation of the vascular damage in obese children	193
<i>Monica Simina Mihuta</i> , Department of Doctoral Studies, Victor Babes University of Medicine and Pharmacy, 300041 Timisoara, Ro-mania, Romania	
Significant risk factors for the increase of arterial stiffness and subclinical atherosclerosis in obese children.	194
<i>Monica Simina Mihuta</i> , Department of Doctoral Studies, Victor Babes University of Medicine and Pharmacy, 300041 Timisoara, Romania, Romania	
CEUS in the evaluation of thyroid nodules – preliminary results	195
<i>Andreea Borlea</i> , University of Medicine and Pharmacy Victor Babes Timisoara, Romania	
2D-SWE for the diagnosis of liver fibrosis using VCTE as reference method in a mixed cohort	196
<i>Camelia Foncea</i> , "Victor Babes" University of Medicine Timisoara, Romania	
Sonographic evaluation of renal transplant complications: A pictorial review	197
<i>Nur Zakiah Sidek</i> , Singapore General Hospital, Singapore	
Cerebral hemodynamics in the patients with various forms of migraine	198
<i>Olga Pushkarenko</i> , Uzhhorod National University, Ukraine	
PRE-SURGICAL DIAGNOSTIC SOLID LESIONS OF THE SKIN	199
<i>Iryna Mota</i> , ukrainian, Ukraine	
A BLENDED LEARNING APPROACH FOR TEACHING CHEST RADIOLOGY TO MEDICAL STUDENTS: A PROOF-OF-CONCEPT STUDY	201
<i>Johannes Matthias Weimer</i> , Rudolf-Frey Lernklinik, Department of Medicine, University of Mainz, Mainz, Germany, Germany	
Automated breast volume scanning and virtual touch imaging quantification in different types of breast cancer	203
<i>Lucan Eugenia Laura</i> , The Center of Excellence of Ultrasonography DOCTOR VANCU, Romania	
Prostate tuberculosis mimicking prostate cancer: multidisciplinary diagnostic imaging and review of the literature	206
<i>YU Li</i> , Affiliated Hospital of North Sichuan Medical College, China	
Comparison of Coracohumeral Distance Measurement by Shoulder Rotation Using Ultrasonography and MRI	207
<i>JONG UK SON</i> , Seoul national university bundang hospital, Korea, Republic of	
ROLE OF 3D USG IN EVALUATION OF MORPHOLOGY AND FUNCTION OF GALLBLADDER	208
<i>Manavjit Sandhu</i> , PGIMER, Chandigarh, India	

Poly(lactic acid) film pocket for ultrasound-controlled prophylaxis against spinal infections: in vitro evaluations	209
<i>Flemming Forsberg</i> , Department of Radiology, Thomas Jefferson University, United States of America	
Possibilities of Gastrointestinal Ultrasound in Diagnosis of Parasitic Invasions of Gastrointestinal Tract	210
<i>Elene Khmaladze</i> , Tbilisi State University Clinic Vivamedi, Georgia	
Testicular microlithiasis – an overview	213
<i>Malene Roland Pedersen</i> , Lillebaelt Hospital, Vejle Hospital, Department of Radiology, Beriderbakken 4, DK-7100 Vejle, Denmark, Denmark	
Use of contrast-enhanced ultrasound imaging to evaluate the effect of an exercise program on rotator cuff disorders	214
<i>Priscilla Machado</i> , Thomas Jefferson University, United States of America	
Using lymphosonography to evaluate the breast lymphatic drainage to the internal thoracic (internal mammary) system	215
<i>Priscilla Machado</i> , Thomas Jefferson University, United States of America	
The use of ultrasound in battlefield environment during the Russian invasion of Ukraine	216
<i>Vitalii Lukianchuk</i> , Ministry of Defense of Ukraine, military hospital, Ukraine	
The Lung ultrasound (LUS) of Pulmonary Oedema in different types of Heart failure (HF)	217
<i>Mikheil Tserava</i> , Chapidze Heart Center, Georgia	
Energy consumption of ultrasound devices and the potential to save energy in German hospitals	218
<i>Mark M. haenle</i> , Ulm University Hospital, Department of Internal Medicine I, Ulm, Germany	
Ultrasound evaluation of inflammatory bowel disease in children	219
<i>Rasa Augustiniene</i> , Section of Ultrasound, Department of Pediatric Radiology, Centre of Radiology and Nuclear Medicine, Vilnius University Hospital Santaros Clinics, Lithuania	
Ultrasound of congenital liver vascular shunts	220
<i>Andrius Čekuolis</i> , 1. Vilnius University, Faculty of Medicine, Institute of Clinical Medicine, Clinic of Obstetrics and Gynaecology; 2. Department of Pediatric Radiology, Centre of Radiology and Nuclear Medicine, Vilnius University Hospital Santaros Klinikos, Lithuania	
Usefulness of ultrasound examination in the detection of medullary thyroid carcinoma, in patients with Graves' disease	222
<i>Mihaela-Maria Vlad</i> , Discipline of Endocrinology, "Victor Babes" University of Medicine and Pharmacy, Timisoara, Romania	

Ultrasound of adolescent breasts	224
<i>Andrius Čekuolis</i> , 1. Vilnius University, Faculty of Medicine, Institute of Clinical Medicine, Clinic of Obstetrics and Gynaecology; 2. Department of Pediatric Radiology, Centre of Radiology and Nuclear Medicine, Vilnius University Hospital Santaros Klinikos, Lithuania	
Ultrasound evaluation protocol of arteriovenous fistula and possible complications	226
<i>Rūta Kliokytė</i> , Vilnius University Hospital Santaros klinikos, Lithuania	
The place of ultrasound in vascular anomalies	227
<i>Lina Mickevičienė</i> , Vilnius university hospital Santaros Clinic, Department of Radiology and Nuclear medicine, Lithuania	
Ultrasound interventions for beginners: 7 tips for a successful first procedure	229
<i>Kipras Mikelis</i> , Vilnius University hospital Santaros klinikos, Lithuania	
CEUS in early follow-up after cryoablation of renal cancer	230
<i>Donatas Jocius Jocius</i> , Vilnius University Hospital Santaros Klinikos, Lithuania	
Thyroid nodule ablation	231
<i>Donatas Jocius</i> , Vilnius University hospital Santaros Klinikos, Lithuania	
Interesting cases from Vilnius University Santaros Clinics ultrasound room experience – acute lower abdominal pain	232
<i>Laura Žilevičė</i> , Vilnius University Faculty of Medicine, Lithuania	
Renal duplex examination for beginners	233
<i>Igne Gecaite - Paukste</i> , Vilnius university hospital Santaros klinikos, Lithuania	
Notes from an interventional radiologist – a bridge between a diagnostic radiologist and a vascular surgeon in a lower limb venous pathology	234
<i>Rokas Gircius</i> , Vilnius University Hospital Santaros Clinics, Lithuania	
Ultrasound evaluation of acute scrotal pathology	235
<i>Irvinas Muliulis</i> , Vilnius University Hospital Santara Clinics, Lithuania	
Advanced ultrasound SMI technique for the assessment of atherosclerotic plaque microvascularization	236
<i>GALINA BALTGAILE</i> , Medical Clinic ARS, Riga Stradins University, Neurological Department, Latvia	
US in chronic granulomatous disease	237
<i>Egle Simanauskiene</i> , 1. Vilnius University, Faculty of Medicine. 2. Vilnius University Hospital Santaros Klinikos, Department of Pediatric Radiology, Lithuania	
CEUS in kidney pathology in children: opportunities and prospects	238
<i>Viktor Zhelov</i> , Western Ukrainian Specialized Children's Medical Center, Head, Ultrasound & Interventional, Ukraine	

Usefulness of ultrasound in diagnosis of upper limb nerve damage	239
<i>Ludmila Klimchuk</i> , State institution «Institute of traumatology and orthopedics of NAMS of Ukraine», Ukraine	
Unusual ultrasound appearance of gigantic liver hydatid cyst: a case report	240
<i>Ioanitu Elena Simona</i> , „Carol Davila” University of Medicine and Pharmacy, Bucharest; Internal Medicine Clinic, Fundeni Clinical Institute, Bucharest, Romania	
Usefulness of elastography in predicting induction to full dilatation time interval	242
<i>Natālija Vedmedovska</i> , Department of Obstetrics and Gynaecology, Rīga Stradiņš University; Riga Maternity Hospital, Latvia	
The role of breast ultrasound breast cancer screening	243
<i>Iacob Roxana</i> , Victor Babes University of Medicine and Pharmacy Timisoara, Discipline of Radiology and Medical Imaging, Romania	
Peculiar ultrasonographic findings in a patient with falciform ligament necrosis following acute cholecystitis and biliary pancreatitis	245
<i>Maria Luigia Vaiano</i> , Gastroenterology and Endoscopy Department, Luigi Sacco University Hospital, Milan, Italy + EFSUMB Ultrasound Learning Center of Brandenburg Institute for Clinical Ultrasound (BICUS) at Medical University Brandenburg, Neuruppin, Germany, Italy	
Soft tissue mass .Is it benign or malignant?	248
<i>Lavinia Magdalena Fisteica</i> , Caraiman Clinic Bucharest, Romania	

CORRELATION OF 3D ULTRASOUND AND HISTOPATHOLOGY ON EX-VIVO TONGUE TUMOR SPECIMEN

***Fatemeh Makouei*¹, FATEMEH MAKOU EI¹, TINA KLITMØLLER AGANDER²,
CHRISTOFFER HOLST HAHN¹, MIKKEL KALTOFT¹, IRENE WESSEL¹,
TOBIAS TODSEN¹**

1. Department of Otorhinolaryngology, Head and Neck Surgery & Audiology, Rigshospitalet University of Copenhagen, Denmark, Copenhagen, Denmark, 2. Department of Pathology, Rigshospitalet, Copenhagen, Denmark

Abstract body

Actuality and Aim

Complete removal of cancer encircled by a secure margin of healthy tissue is the aim of surgical oncology. A close or positive surgical margin reported by pathologist typically ends in adjuvant therapies (re-surgery and/or radiotherapy), which come with prognostic risks and financial expenditures. Therefore, ex-vivo imaging of removed cancer tissue may assist in margin evaluation. In this study, we aimed to investigate the correlation of 3D ultrasound to histopathology to assess tongue tumor status.

Materials and Methods

We generated 3D ultrasound of the formalin fixated tongue tumor using a custom-made setup, Hitachi(FujiFilm) Arietta850 ultrasound machine, and L64 linear probe. Data was processed by our MATLAB script for volume construction. The specimen was sliced by a pathologist and digital histopathology images were provided. Tumor region was segmented on 3D ultrasound by two head and neck surgeons blinded to the pathology results.

Results

The tongue tumor dimensions were measured on histopathology images. The tumor region morphology was reported on parallel planes on 3D ultrasound by two head and neck consultants. The correlation between the measurements from 3D ultrasound and histopathology was 82%, 79%, and 78% for tumor area, tumor width, and depth of invasion, respectively.

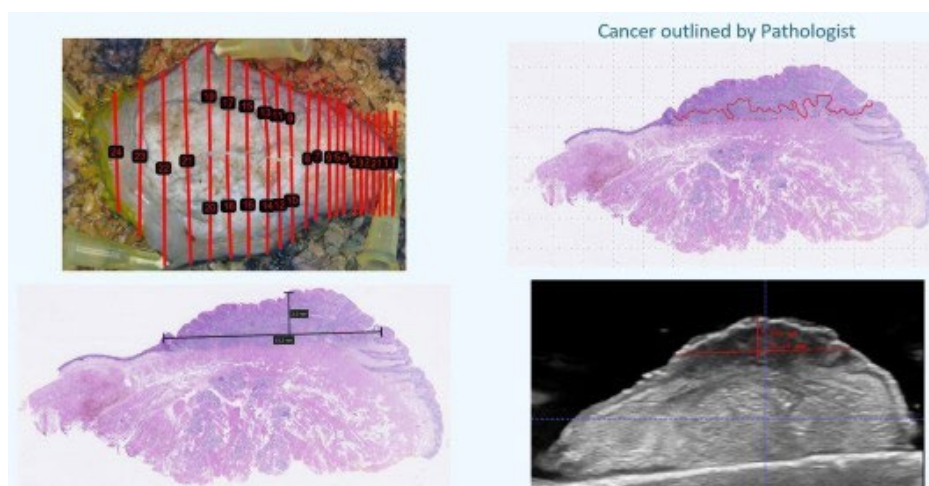
Conclusion

3D ultrasound is accurate for the measurement of tongue tumor dimensions compared to histopathology. The low cost and portability of ultrasound could make this modality an attractive imaging modality for the ex-vivo surgical specimens in the operation room. A comprehensive study with a large data set is essential to confirm the results.

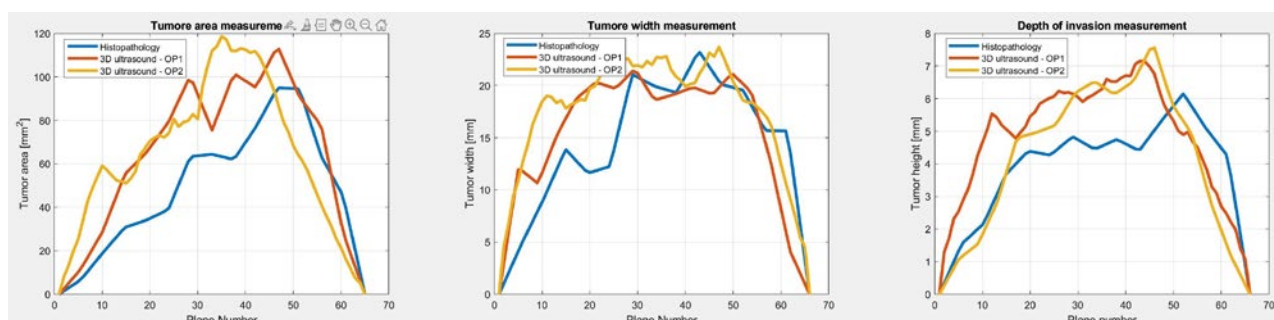
References

-

CORRELATION OF 3D ULTRASOUND AND HISTOPATHOLOGY ON EX-VIVO TONGUE TUMOR SPECIMEN



Correlation of histopathology and ultrasound at a corresponding image slide



Correlation of tumor dimension measurements at 3D ultrasound vs. histopathology

MN-BASED CONJUGATED MIMETIC ENZYME COMBINES HIFU FOR ENHANCED HISTOTRIPSY TO TREAT HEPATOCELLULAR CARCINOMA

Liao Min Liao¹

1. West China Hospital of Sichuan University

Abstract body

Objective: To develop a novel nano-mimetic enzyme and to study the effect of high-intensity focused ultrasound (HIFU) in synergy with this agent for enhanced histotripsy to the treatment of hepatocellular carcinoma. **Methods:** The conditions for the preparation of Mn-based conjugated mimetic enzyme agent were studied; a series of in vitro and in vivo experiments were performed to explore the influences of this agent combined with HIFU on tumor inhibition.

Results: The Mn-based conjugated mimetic enzyme was uniformly dispersed, and its particle size was about 110 nm. The gas produced by this agent significantly reduced the inertial cavitation threshold, and the degree correlated with the gas production. HIFU combined with the agent group had the most significant damage to Hepa1-6 cells within the safe concentration of Mn-based conjugated mimetic enzyme agents. At the biomimetic level, HIFU combined with this agent was effective in disrupting the biomimetic model, with no statistical difference in destruction in the remaining groups. Compared with other groups, HIFU combined with the Mn-based conjugate agent group effectively ablated the tumor tissue and had the most obvious effect on tumor treatment. In addition, there was no significant difference in body weight and liver and kidney function of tumor-bearing mice in the different treatment groups.

Conclusion: A novel nano-mimetic enzyme agent was developed, and HIFU synergized with this agent can effectively reduce the cavitation threshold, and improve the controllability and safety of histotripsy, which provides a new strategy for the non-invasive treatment of hepatocellular carcinoma.

References

Ca-Cancer J Clin, 2018, 68(6): 394-424.

2D VERSUS 3D DYNAMIC CONTRAST-ENHANCED ULTRASOUND FOR EARLY ASSESSMENT OF TREATMENT RESPONSE IN METASTATIC LIVER LESIONS

Ahmed El Kaffas¹, ***Neha Antil***¹, ***Amir M Pirmoazen***², ***George Fisher***¹, ***Dimitre Hristov***¹, ***Amelie Lutz***¹, ***Aya Kamaya***¹, ***Ahmed El Kaffas***¹

1. Stanford University, 2. UF Health Radiology, Jacksonville

Abstract body

Aim: To compare performance of 2D and 3D DCE-US for early response evaluation in patients with metastatic liver lesions against RECIST 1.1 as clinical standard for treatment response assessment.

METHODS: Two 3D DCE-US scans (D0: before treatment and D14: 2weeks ± 5days after treatment) were performed in 14 patients with ≥1 liver lesion using DEFINITY microbubbles. A volume-of-interest (VOI) was drawn outlining the lesion and was subsequently used to generate TICs for quantification of perfusion. The analysis of 2D DCE-US was performed by extracting 2D slices within 3D volumes. Peak enhancement (PE) was measured. Differential contrast enhancement was then calculated as percentage difference between D14 and D0 median value. Finally, the quantitative 2D and 3D DCE-US perfusion parameters were compared with RECIST 1.1 criteria.

RESULTS: 3D DCE-US outperformed in 50% (7/14) of cases and performed equally in rest 7/14 cases when compared with 2D DCE-US. 2D DCE-US wrongly predicted response in 3 case of disease progressive disease by showing apparent perfusion reduction while 3D DCE-US showed true perfusion increase. 3D DCE-US considers the whole tumor volume and associated heterogeneity, while 2D DCE-US only captures part of tumor leading to sampling errors and subjective variability.

CONCLUSION: Quantified 3D DCE-US offers promising imaging biomarkers for early treatment response assessment in patients with liver metastasis that either outperforms or perform equally when compared to 2D DCE-US.

References

El Kaffas A, Sigrist RMS, Fisher G et al. Quantitative Three-Dimensional Dynamic Contrast-Enhanced Ultrasound Imaging: First-In-Human Pilot Study in Patients with Liver Metastases. *Theranostics*. 2017 Aug 23;7(15):3745-3758.

HCCS LACKING ARTERIAL PHASE HYPERENHANCEMENT (APHE) ON CEUS – FINDINGS FROM THE PROSPECTIVE MULTICENTRE DEGUM CEUS HCC TRIAL

**Deike Strobel¹, Abbas Agaimy², Daniel Jesper¹, Sebastian Zundler¹,
Barbara Schellhaas¹**

1. Department of Internal Medicine 1, Erlangen University Hospital, Friedrich Alexander University (FAU) Erlangen-Nurnberg, 2. Department of Pathology, Erlangen University Hospital, Friedrich Alexander University (FAU) Erlangen-Nurnberg

Abstract body

Actuality and Aim

Hepatocellular carcinoma (HCC) upon CEUS typically shows arterial phase hyperenhancement (APHE), followed by late (> 60 seconds) and mild contrast washout (WO). Although APHE is considered as the hallmark of HCC, it can be absent in some HCCs. Thus, we explored which sonomorphological and histopathological features of HCC are associated with a lack of APHE upon CEUS.

Material and Methods

Focal liver lesions in high-risk patients for HCC were assessed with CEUS following a standardised protocol in a prospective multi-centre real-life setting. CEUS patterns in HCC were assessed, and tumour and patient characteristics were compared for HCCs with and without APHE.

Results

316 patients with HCC were recruited (cirrhosis, 76.9%). APHE occurred in 271/316 HCCs (85.8%). A lack of APHE was associated with portal vein thrombosis, tumour infiltration of the liver vessels ($p<0.001$), larger size, multilocularity, and higher depth location upon ultrasound ($p<0.01$). Histological grading did not differ between HCCs with and without APHE ($p=0.39$). Histopathological features of HCCs without APHE included cirrhotic stromal reaction, marked tumour cell steatosis and absence of the typical surrounding dilated sinusoidal vascular channels.

Conclusions

Correlation with histopathological findings support the fact that HCCs with a lack of APHE in CEUS are a heterogeneous group. The examiner has to be aware that HCCs with portal vein thrombosis or macro-invasion of the liver vessels may lack APHE.

References

Schellhaas B et al. Contrast-Enhanced Ultrasound Algorithms (CEUS-LIRADS/ESCU LAP) for the Noninvasive Diagnosis of Hepatocellular Carcinoma - A Prospective Multicenter DEGUM Study. *Ultraschall Med.* 2020 Jul 14.

ENDOSCOPIC ULTRASOUND AS A PERFECT SOLUTION FOR PANCREATIC CANCER

***Benahmed Amina*¹, Hazadji Kada¹**

1. University of mostaganem Faculty of biology

Abstract body

Endoscopic ultrasonography (EUS) is an important aspect of contemporary gastrointestinal endoscopy and is currently used to diagnose pancreatic disorders.

Furthermore, as EUS technology has evolved, it has become more of a therapeutic technique, and the promise of many interventional EUS applications for the pancreas is genuinely on the horizon.

This study, on the other hand, concentrates on the known diagnostic and therapeutic roles of EUS in contemporary clinical practice.

The diagnostic examination of acute pancreatitis, chronic pancreatitis, cystic pancreatic lesions, and solid pancreatic tumors is covered in detail.

In this context, the recent improved imaging techniques of elastography and contrast enhancement are reviewed.

The primary therapeutic components of pancreatic EUS, especially celiac plexus block, are then discussed. The primary therapeutic elements of pancreatic EUS are then discussed, including celiac plexus block and neurolysis for pain management in chronic pancreatitis and pancreatic cancer, as well as EUS-guided drainage of pancreatic fluid collections.

References

1. Wu BU, Banks PA. Clinical management of patients with acute pancreatitis. *Gastroenterology*. 2013;144:1272-1281. [PubMed] [Google Scholar]
2. Bollen TL. Imaging of acute pancreatitis: update of the revised Atlanta classification. *Radiol Clin North Am*. 2012;50:429-445. [PubMed] [Google Scholar]
3. Tse F, Liu L, Barkun AN, Armstrong D, Moayyedi P. EUS: a meta-analysis of test performance in suspected choledocholithiasis. *Gastrointest Endosc*. 2008;67:235-244. [PubMed] [Google Scholar]
4. Maluf-Filho F, Dotti CM, Halwan B, Queiros AF, Kupski C, Chaves DM, Nakao FS, Kumar A. An evidence-based consensus statement on the role and application of endosonography in clinical practice. *Endoscopy*. 2009;41:979-987.

PANCREATIC NEUROENDOCRINE TUMORS: CORRELATION BETWEEN DYNAMIC CONTRAST ENHANCED ULTRASOUND AND PATHOLOGICAL TUMOR GRADES

Yi Dong¹

1. Department of Ultrasound, Xinhua Hospital affiliated to Shanghai
Jiaotong University School of Medicine

Abstract body

Aim: The aim of this study was to investigate whether the dynamic contrast enhanced ultrasound (D-CEUS) features with quantitative parameters could effectively predicting for pancreatic neuroendocrine tumors' (pNETs) grades before operation according to WHO classification.

Material & Methods: Patients suspected of pNETs underwent D-CEUS of pancreas within one week prior to the surgery. Time intensity curves (TICs) were created and quantitative indexes of D-CEUS were analyzed. Patient demographics, CEUS findings, and quantitative parameters were compared to histopathological features.

Results: Finally, a total of 36 patients with histopathologically confirmed pNETs met the inclusion criteria, including 12 cases of G1, 16 cases of G2, and 8 cases of G3 patients. Compared with G1, G2/G3 pNETs showed ill-defined margin (62.5 %) and hypoenhancement during the late phase (41.6 %). Among all CEUS quantitative indexes, area under curve (AUC) was significantly higher in G2/G3 pNETs with ROC-AUC 0.731, sensitivity 81.8 % (95 % CI: 62.2-91.3) and specificity 65.2 % (95 % CI: 43.7-80.1) ($P < 0.05$).

Conclusions: D-CEUS analysis might be helpful in preoperative predicting tumor grades and liver metastases of pNETs. AUC is the potential D-CEUS parameter for identification of G2/G3 from G1 pNETs.

References

D'Onofrio M, Biagioli E, Gerardi C, et al. Diagnostic performance of contrast-enhanced ultrasound (CEUS) and contrast-enhanced endoscopic ultrasound (ECEUS) for the differentiation of pancreatic lesions: a systematic review and meta-analysis. *Ultraschall Med* 2014;35:515-521.

AN UNUSUAL ULTRASOUND DISCOVERY – MALT LYMPHOMA OF THE TERMINAL ILEUM

***Mihaela Tanco*¹, Ioan Tiberiu Tofolean¹**

1. Ovidius University of Constanta

Abstract body

Background: Gastrointestinal tract is affected by extranodal non-Hodgkin's lymphomas, with the majority of the cases involving gastric area and being associated with *Helicobacter pylori* infection. Yet among small intestine lymphomas, MALT type is a rare finding, being described in only a third of cases.

Case report: We report the case of a 71 years-old male, with a history of type 2 diabetes mellitus, alcoholic liver cirrhosis, and chronic venous insufficiency, who presented to our department for pain in the right iliac fossa for the last 2-3 weeks, and monitoring his chronic hepatopathy.

Conventional abdomino-pelvic ultrasound revealed a cockade image in the right iliac fossa, with thickening of the intestinal wall up to 15 mm.

CEUS examination followed, which revealed rapid enhancement of the cockade image from the right iliac fossa, and a rapid washout of the contrast agent. Contrast-enhanced abdomino-pelvic CT scan and colonoscopy confirmed the ultrasound diagnosis of a protrusive, circumferential terminal ileum tumoral mass, centrally ulcerated and presenting necrotic debris-biopsies being sampled. The patient was referred to Surgical Department where he undergoes right hemicolectomy with double plan latero-lateral ileo-transverse anastomosis, subtotal epiploectomy, and peritoneal biopsy (extemporaneous result: atypical lymphocytic proliferation-lymphoma).

Conclusions: Histological exam and immunohistochemistry confirmed MALT intestinal lymphoma-marginal zone, subtype A (pure, low grade), so a positive diagnosis of Terminal Ileum MALT Lymphoma was established, and the patient was referred to Oncology department.

Acknowledgements: Terminal ileum MALT lymphomas are extremely rare, with only a few reports in the literature so far, in patients with advanced disease.

References

-

KINETIC MODELING TO ESTIMATE UPTAKE RATE OF MICROBUBBLES IN AXILLARY SENTINEL LYMPH NODES USING LYPHOSONOGRAPHY

Priscilla Machado¹, **Kenneth Tichauer**², **Kane Liu**², **Ji-Bin Liu**¹, **Maria Stanczak**¹,
Walter Kraft¹, **Flemming Forsberg**¹

1. Thomas Jefferson University, 2. Illinois Institute of Technology

Abstract body

Actuality and Aims: Develop kinetic model to estimate lymphatic flow and uptake rate of microbubbles in axillary SLNs imaged using lymphosonography.

Methods: Twelve female healthy-volunteers received subcutaneous ultrasound contrast agent injections around 2-cm region upper-outer quadrant of the breast (total: 1.0ml). Lymphosonography was performed using an ultrasound scanner at specific time-points.

Microbubble concentration was mathematically represented using a two-compartment model assuming concentration in lymphatics feeding SLN, C_l , as function of time, t , represented by:

$$l[C_l(t) = \alpha C_0 e^{-(k_l t)} \quad (1)$$

C_0 concentration of microbubble, α fraction of C_0 making into afferent lymph vessels and k_l a rate constant governing loss of concentration. Microbubble concentration assumed to internalize into macrophages, governed k_i , proportional to number of macrophages and rate of uptake per macrophage; or be eliminated from the SLN at lymphatic flow rate, F_l . Resulting equation:

$$l[C_{node}(t) = \int_0^t k_{il} C_{node}(0) e^{-(k_l t)} * e^{-(k_i + F_l)t} u(t) dt, \quad (2)$$

$\alpha C_0 = C_{node}(0)$, * represents convolution operator and $u(t)$ is a step function. Eq (2) yields three parameters: k_i , F_l , and k_l , the main parameter related to concentration of macrophages in SLN (i.e., to tumor burden) is k_i .

Results: Average estimates of k_i , F_l , and k_l were $0.90 \pm 0.06/\text{min}$, $2 \pm 1/\text{min}$ and $0.09 \pm 0.06/\text{min}$, respectively. Large variances (>50%) were observed in F_l and k_l amongst subjects, however, variance of k_i , the main parameter of interest, was less than 10% of the mean.

Conclusion: k_i is expected to be lower in SLNs with cancer owing to lower concentration of macrophages, which will be investigated in future research.

Acknowledgements: NIH-R01CA172336.

References

N/A

RABBIT'S LUNG HEMORRHAGE INDUCED BY ULTRASOUND WITH LONG PULSE DURATION

Iwaki Akiyama¹, **Noriya Takayama**², **Hideki Sasanuma**², **Kazuma Rifu**², **Notaka Nitta**³, **Nobuyuki Taniguchi**⁴

1. Doshisha University, 2. Jichi Medical University, 3. National Institute of Advanced Industrial Science and Technology, 4. Saiseikai Utsunomiya Hospital

Abstract body

Actuality and Aim

Rabbit's lung hemorrhage induced by ultrasound with long pulse duration (PD), which was used in the Shear Wave Elastography. The aim of the study is to clarify the relationship between peak rarefactional pressure amplitude (PRPA) and Mechanical Index (MI)1).

Material and Methods

18 and 2 rabbits exposed to ultrasound with 0.3 ms PD and sham groups, respectively. The newly developed ultrasonic experimental system equipped with a 5.2 MHz linear probe was used for the exposure to ultrasound.

Results

Logistic regression analysis showed that derated PRPA was significantly associated with lung hemorrhage with the threshold estimated to be 1.1 MPa(MI=0.5). Spearman's rank correlation showed a positive correlation between derated PAPA and lesion area.

Conclusion

This study demonstrated that the occurrence and severity of ultrasound with long PD induced lung hemorrhage increased with a rise in PRPA.

References

1) N.Takayama et al. Acoustic radiation force impulse-induced lung hemorrhage:

investigating the relationship with peak rarefactional pressure amplitude and mechanical index in rabbits, Journal of Medical Ultrasonics, Published online 11 February 2023.

ENERGY CONSUMPTION OF ULTRASOUND DEVICES AND THE POTENTIAL TO SAVE ENERGY IN GERMAN HOSPITALS

**Mark M. Haenle¹, Maximilian M.F. Kokenge², Ronald Blechschmidt³,
Wolfgang Kratzer²**

1. Ulm University Hospital, Department of Internal Medicine I, Ulm, 2. Ulm University Hospital, Department of Internal Medicine I, Ulm, Germany, 3. Ulm University of Applied Sciences, Ulm, Germany

Abstract body

Actuality and Aim: Against the background of climate change, saving energy is getting more and more important. The energy consumption of ultrasound units is much lower than of CT or MRI scanners. Although, due to the high number of ultrasound units in daily use worldwide, it might still be relevant on a global scale. Our study for the first time aims to assess energy consumption of 9 different ultrasound devices in a hospital setting and compare it with manufacturer's data. Additionally user behaviour towards "switching off" ultrasound machines after use and saving energy in general was assessed in a representative sample of German hospitals.

Methods: The power consumption of 9 different ultrasound devices was measured in off-mode, stand-by, ready-to-scan and scan-mode with different settings and probes and compared to manufacturers' information. A random sample of 10% of all German hospitals was surveyed with an online questionnaire on user behaviour towards saving energy in ultrasonography.

Results: Preliminary results show significant differences of energy consumption in stand-by and ready-to-scan mode between different manufacturers. In stand-by mode energy consumption is still relatively high. The results of the online survey of German hospitals will be available soon.

Conclusions: Preliminary results show significant differences of energy consumption between different ultrasound units and relatively high energy-consumption in stand-by-mode indicating a huge potential to reduce energy waste.

References

SPINAL DEVICE FOR ULTRASOUND-TRIGGERED DRUG RELEASE EVALUATED IN SMALL AND LARGE ANIMAL MODELS

Flemming Forsberg¹, Rachel Hilliard², Priscilla Machado¹, Rachel Evans¹, Selin Isguven¹, Steven Kurtz³, Noreen Hickok¹, Thomas Schaer⁴, Lauren Delaney¹

1. Thomas Jefferson University, 2. University of Pennsylvania, New Bolton Center,
3. Drexel University, 4. University of Pennsylvania, New Bolton Center

Abstract body

Actuality and Aim: Despite aggressive perioperative prophylaxis, up to 20% of instrumented spinal surgeries result in implant-associated infections. We have designed an ultrasound-triggered drug release system to combat post-surgical bacterial survival and evaluated its functionality in animal models.

Methods: Polylactic acid (PLA) clips with a 0.8cm³ drug-loading reservoir were 3D printed, loaded with 150µL methylene blue (MeB) solution and 50µL of Sonazoid microbubbles (GE Healthcare), then sealed with a PLA film (0.05±0.01mm thick). Prepared clips were implanted into three rabbits and eight sheep along the spinal midline at L2 and L5, and one pig at L1 and L3. Two rabbits and two sheep were used as uninsonated controls. The remaining animals were insonated transdermally with a Logiq E10 (GE) in power Doppler imaging mode at 1.7MHz for 20 minutes using the C6 probe (5.4kHz PRF, ISPTA<146 mW/cm²).

Results: The animals tolerated the implantations with no adverse effects. The uninsonated clips (n=9) showed no signs of rupture or release, and there was no MeB staining on the surrounding tissues. Clips retrieved from the insonated rabbit (n=2) also showed no signs of PLA film rupture nor MeB staining on surrounding tissues. Following physical puncture of the PLA film, release of MeB solution was visible. The insonated clips from the pig and sheep (n=13) were visibly ruptured, and demonstrated some MeB staining of the overlying tissues (p<0.0001 vs. uninsonated).

Conclusions: Results demonstrate an important proof of concept for continued in vivo evaluations of ultrasound-triggered prophylactic release.

Acknowledgements: NIH R01AR069119, F32AR072491, and K99AR078354

References

N/A

PRELIMINARY RESULTS OF A HYBRID APPLICATION OF ULTRASOUND WITH AN ADVANCED SYSTEM FOR CUSTOMIZED REHABILITATION

Alexandra André¹, ***Cândida Malça***², ***Luís Roseiro***², ***Marco Silva***², ***Frederico Santos***², ***Arménio Cruz***³, ***Rafael Bernardes***³, ***António Ribeiro***⁴, ***Willian Xavier***⁵,
Rúben Durães⁴

1. Polytechnic of Coimbra, Health School, Rua 5 de Outubro, 3045-043 Coimbra, Portugal, 2. Polytechnic of Coimbra, ISEC, Rua Pedro Nunes, 3030 -199 Coimbra, Portugal, 3. Nursing School of Coimbra, Avenida Bissaya Barreto 143, 3004-011 Coimbra, Portugal, 4. ORTHOS XXI, Rua Santa Leocádia 2735, 4809-012 Guimarães, Portugal, 5. WISEWARE, Zona Industrial da Mota, Rua 12, Lote 51, Fração E, 3830-527 Gafanha da Encarnação, Portugal

Abstract body

Sarcopenia is the age-related progressive and generalized loss of skeletal muscle mass (MM) and strength connected to prolonged immobility. Ultrasound (US) allows us to evaluate and quantify MM, and rehabilitation therapy can combat sarcopenia. This study is part of the ABLEFIT, a rehabilitation system ensuring customized rehabilitation plans, aiming to validate the US use in the measurement of i) muscle thickness (MT), ii) cross-sectional area (CSA), iii) pennate angle (PA). Material and Methods: Two groups were selected i) Active Group (AG) (n=6); ii) Sedentary Group (SD) (n=7), age [70-80]. A specific rehabilitation program was prescribed. US protocol was used, performed in the right lower limb - gastrocnemius (GM). Volunteers with chronic skeletal muscle disease were excluded. Results: Statistical differences in the CSA of the RF ($2,82 \pm 0,52 \text{ cm}^2$ - $1,81 \pm 0,38 \text{ cm}^2$) and MT differences ($22,53 \pm 2,96 \text{ mm}$ - $16,87 \pm 3,12 \text{ mm}$). Also, differences in the PA in the right GM ($25,00 \pm 3,46$ - $19,00 \pm 4,24$) could be measured. Conclusions: Results demonstrate that the US is a reliable and valid method of diagnosis to i) assess the quantitative loss of MM; ii) measure the US parameters to predict the MM, e.g., due to the sarcopenia disease. The use of ABLEFIT interactive interface for patient motivation associated US application to evaluate the MM will be the next step. Acknowledgements: This research was co-financed by the European Regional Development Fund (ERDF) through the partnership agreement Portugal 2020 Operational Programme for Competitiveness and Internationalization (COMPETE2020) under the project POCI-01-0247-FEDER-047087ABLEFIT: Desenvolvimento de um Sistema avançado para Reabilitação

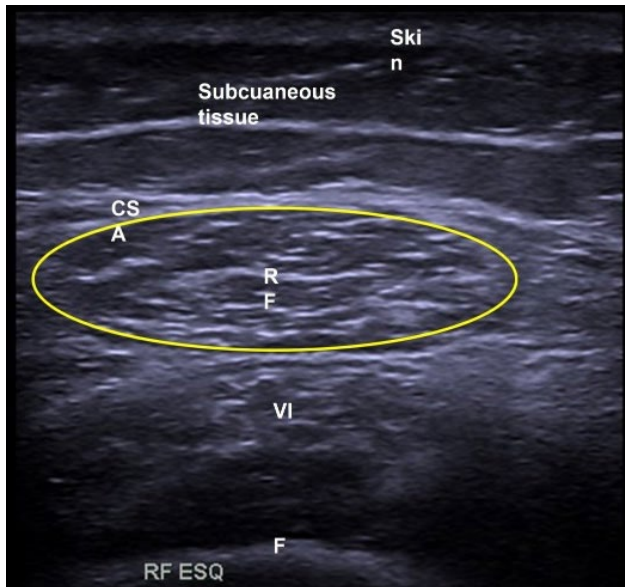
References

DOI

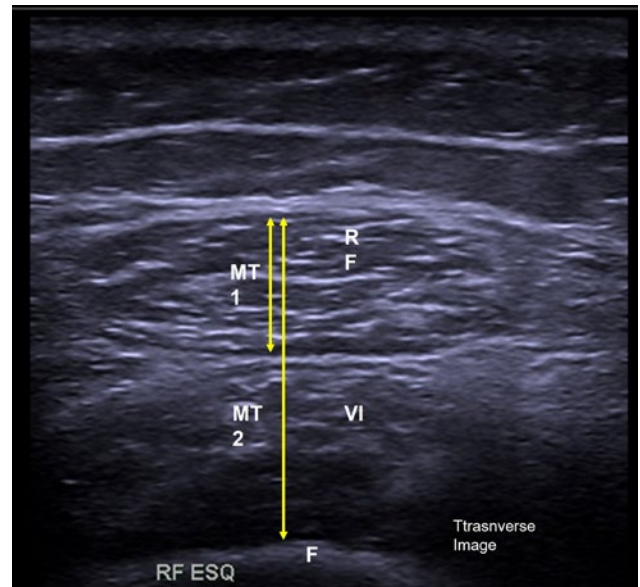
10.3390/ijerph17051708

10.1002/jcsm12076

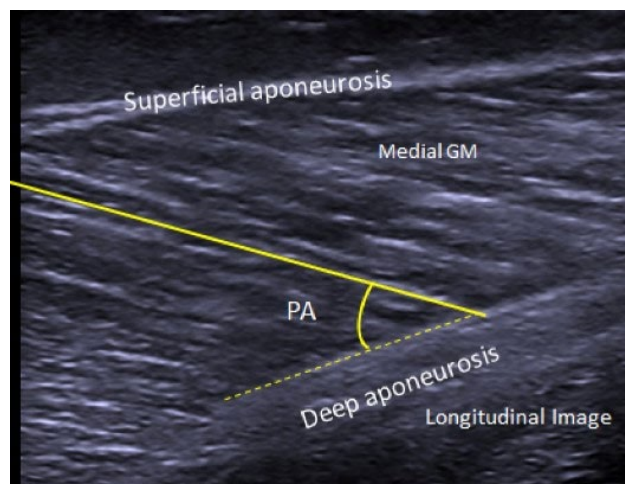
PRELIMINARY RESULTS OF A HYBRID APPLICATION OF ULTRASOUND WITH AN ADVANCED SYSTEM FOR CUSTOMIZED REHABILITATION



Rectos Femoris - Cross Sectional Area



Muscle Thickness - Rectos Femoris



Medial Gastrocnemius - Pennate Angle

DEVELOPMENT OF AN ARTIFICIAL INTELLIGENCE PROCEDURE FOR DETECTING AND CLASSIFYING ULTRASOUND ARTIFACTS IN REAL-TIME

Kollmann Christian¹, ***Zellinger Emil***², ***Haller Karin***³

1. Center for Medical Physics & Biomedical Engineering, Medical University of Vienna, Waehringer Guertel 18-20, 1090 Vienna, Austria, 2. University of Applied Sciences Technikum Wien, Faculty of Software Engineering, Hoechstaedtplatz 6, 1200 Vienna, Austria, 3. Faculty of Health Care, University of Applied Sciences Wiener Neustadt, Johannes Gutenberg-Straße 3, 2700 Wiener Neustadt, Austria

Abstract body

Aim

US scans contain artifacts and for ultrasound novices it a goal to recognise and identify the most common artifacts as early as possible.

Methods

To achieve this goal, the deep learning YOLOv5 object detection model (Ultralytics, Los Angeles USA) was trained. By using the open-source Computer Vision Annotation Tool (V7 Ltd, London UK) the artifacts have been segmented out of the data. The dataset contained in a first step 18 scans with 5567 frames and a total of 8864 labels for 6 type of US artifacts extracted from B-Mode and Colour Doppler videos.

Results

The prototype, that is able to detect and classify US artifacts in real-time, was developed. While the user is scanning the patient, the image data a grabbed to a notebook running the trained YOLOv5 object detection model and shows the identified artifact and its location within the original US image.

Conclusions

Since the dataset used for training was very limited in its diversity, the predictions were pretty mediocre in the first step but when using a scan fairly similar to the dataset, the YOLOv5 model performed very well and can absolutely be used in real-time. This means that using this method with a more diverse dataset for training purposes it will show promising results.

References

Redmon, J., & Farhadi, A. (2015). You only look once: Unified, real-time object detection. In Proceedings of the IEEE conference on computer vision and pattern recognition (pp. 779-788).

Haller, Kollmann (2010). Sono-Guide für MTRA/RT, Thieme. ISBN 978-3-13-146301-2

CHARACTERIZING THE STATUS OF SENTINEL LYMPH NODES WITH LYMPHOSONOGRAPHY AND DEEP-LEARNING COMPARED TO RADIOLOGIST'S

Priscilla Machado¹, ***Aylin Tahmasebi***¹, ***Samuel Fallon***¹, ***Ji-Bin Liu***¹,
Basak Dogan², ***Laurence Needleman***¹, ***Melissa Lazar***¹, ***Alliric Willis***¹,
Adam Berger³, ***Flemming Forsberg***¹

1. Thomas Jefferson University, 2. University of Texas, Southwestern Medical Center, 3. Rutgers University

Abstract body

Actuality and Aims: Evaluate efficacy of lymphosonography to identify sentinel lymph nodes (SLNs) in breast cancer patients and use deep learning (DL) model to differentiate benign and malignant SLNs; compared to radiologists' assessments.

Methods: 79 subjects completed this IRB-approved study. Subjects received subcutaneous ultrasound contrast agent (UCA) injections (1.0ml) around tumor. Lymphosonography was employed to identify SLNs on S3000 HELX scanner. Subjects received standard-of-care blue dye (BD) and radioactive tracer (RT). Excised SLNs classified for presence of BD, RT and UCA before pathology. Google AutoML used for DL model design and classification. Performance metric was area under precision/recall curve (AuPRC). Three radiologists assessed the same images.

Results: 252 SLNs excised, 158 positive for BD, 222 positive for RT and 223 positive for UCA Compared to BD, RT showed accuracy 96.2%, lymphosonography 99.4% ($p>0.15$). Compared to RT, BD showed accuracy 68.5%, lymphosonography 86.5% ($p<0.0001$). Of 252 SLNs, 34 were malignant by pathology; 18 positive for BD (53%), 23 positive for RT (68%), 34 positive for UCA (100%; $p<0.0001$). SLNs identified with lymphosonography were divided group1 (all) and group2 (equal number benign/malignant). AuPRC group1: 0.84(B-mode)/0.91(contrast-enhanced ultrasound [CEUS]); group2: 0.91(B-mode)/0.87(CEUS). Comparison DL versus readers group1: B-mode $p=0.047$, CEUS $p=0.0004$; group2: B-mode $p=0.03$, CEUS $p=0.04$. Interreader agreement was poor with values around 0.2.

Conclusion: Lymphosonography achieved similar accuracy as RT and higher than BD for identifying SLNs and detected all malignant SLNs. DL improved diagnostic performance in equal volume datasets (group2), radiologist performance was not influenced by volume datasets.

Acknowledgements: NIH-R01CA172336.

References

N/A.

ULTRASOUND-TRIGGERED DRUG RELEASE SYSTEM TO COMBAT POST-SURGICAL INFECTIONS: IN VITRO EVALUATIONS

Flemming Forsberg¹, Selin Isguven¹, Quezia Lacerda¹, Priscilla Machado¹, Steven Kurtz², Noreen Hickok³, Lauren Delaney¹

1. Thomas Jefferson University, 2. Drexel University, 3. Thomas Jefferson University

Abstract body

Actuality and Aim: Bacterial infection following instrumented spinal surgery is a major clinical concern with up to 20% incidence. We have designed and evaluated an ultrasound-triggered drug release system to combat post-surgical bacterial survival in vitro.

Methods: Polylactic acid (PLA) clips with a 0.8cm³ drug-loading reservoir were 3D printed, loaded with ~165µL of VAN solution (400mg/mL, ~70mg total, Athenex) and 50µL of Sonazoid microbubbles (GE Healthcare), and then sealed with a PLA film (0.05±0.01mm thick). Long-term stability of Sonazoid in distilled water and VAN was determined over a 14-day incubation at 4°C. Microbubble counts were obtained via flow cytometry. Contrast enhancement was visualized with a Logiq E10 scanner (GE). VAN-loaded clips were submerged in 37°C water and insonated for 10 minutes using a curvilinear C6 probe. Power Doppler imaging (1.8MHz, 6.5kHz PRF, ISPTA 146.2±1.4mW/cm²) induced VAN release, which was quantified using spectrophotometry.

Results: VAN had a conservatory effect on Sonazoid (p=0.007) over the 14 days. The number of Sonazoid microbubbles in distilled water reduced by an order of magnitude (from 7.3±1.4x10⁷/mL to 7.3±1.6x10⁶/mL), while those incubated in the VAN solution reduced less (from 8.9±6.7x10⁶/mL to 3.3±9.3x10⁶/mL). Marked contrast enhancement was observed from both solutions at 14 days. Insonated clips had an average cumulative VAN release of 81.4±2.8mg at 72 hours. Uninsonated clips achieved only 0.3±0.1mg average cumulative VAN release (p<0.0001).

Conclusions: These results demonstrate the ability to produce ultrasound-triggered release of an encapsulated VAN solution in vitro, which may be useful for prophylaxis.

Acknowledgements: NIH R01AR069119, F32AR072491, and K99AR078354

References

N/A

HAS LUNG ULTRASOUND BECOME THE NEW GAME CHANGER?

Rafal Rajski¹

1. Faculty of Medicine of the University of Opole

Abstract body

Actuality and aim: Over the years, the main users of lung ultrasound (LUS) have been mainly intensive care and emergency medicine physicians. With the beginning of the COVID-19 pandemic, it gained immense popularity. The aim of this study was to determine the popularity of lung ultrasonography among doctors and their subjective opinion about it.

Methods: The study consisted of an analysis of: literature from the Pubmed database and a survey addressed to doctors from Poland.

Results: The research group included 100 surveys, which were divided into LUS users and non-users (62% vs 38%). In both groups, the lack of invasiveness (91.1%, 89.5%) and the possibility of frequent monitoring (87.1%, 81.6%) were indicated as the greatest advantage. 96.5% of users believe that it is a perspective technique and 91.9% believe that it should be introduced into the medical study curriculum. 79% users and 50% non-users rated LUS as useful in COVID-19. Many physicians showed the need to include LUS in the official guidelines of scientific societies.

Conclusions: Lung ultrasound is commonly used in many fields of medicine, especially among young doctors. It is a perspective technique, the learning of which should start at the medical academy and should be included in the guidelines of the largest scientific societies.

Acknowledgements: I am much obliged to the Authorities of the University of Opole for financial support.

References

Demi, Libertario, et al. "New international guidelines and consensus on the use of lung ultrasound." *Journal of Ultrasound in Medicine* (2022).

THE USE OF ULTRASOUND IN BATTLEFIELD ENVIRONMENT DURING THE RUSSIAN INVASION OF UKRAINE

Vitalii Lukianchuk¹, Oleh Dynnyk²

1. Ministry of Defense of Ukraine, military hospital, 2. Medical Director of the Institute of Elastography, President of the Ukrainian Association of Ultrasound Diagnostics.

Abstract body

On February 24, 2022, the Russian Federation invaded Ukraine, starting a war. Like any armed conflict, these events have a large number of victims.

In order to understand the utility of tactical ultrasound it is important to understand the battlefield environment, the military medical system and combat medicine. The purpose of combat medicine is to return the greatest number of military members to combat and to preserve life, limb and eyesight in those who must be evacuated from the battlefield.

Accurate and reliable diagnostic capability is essential in deployed healthcare to aid decision-making and mitigate risk. This is important for both the patient and the deployed healthcare system, especially when considering the prioritization of scarce aeromedical evacuation assets and frontline resources.

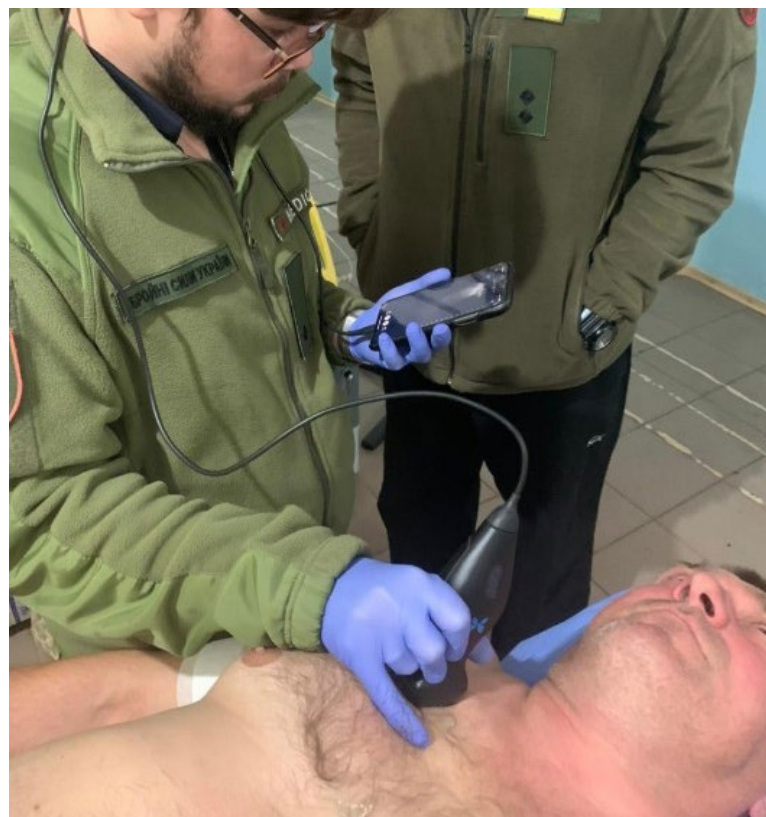We describe the use of emergency ultrasound in austere environments to guide tactical decision-making. We describe the use of tactical ultrasound, which is the use of emergency ultrasound to guide decision-making in the diagnosis, treatment and disposition of patients when resources are scarce and testing is severely limited. It is the use of emergency ultrasound in an environment that is inherently different than routine daily practice in emergency departments in the developed world. Tactical ultrasound provides critical information that justifies the utilization of limited resources and the significant risk involved in evacuating a patient to higher levels of care. Battlefield medicine is the primary venue where tactical ultrasound is useful, however, these same principles apply to civilian mass casualty incidents.

References

THE USE OF ULTRASOUND IN BATTLEFIELD ENVIRONMENT DURING THE RUSSIAN INVASION OF UKRAINE

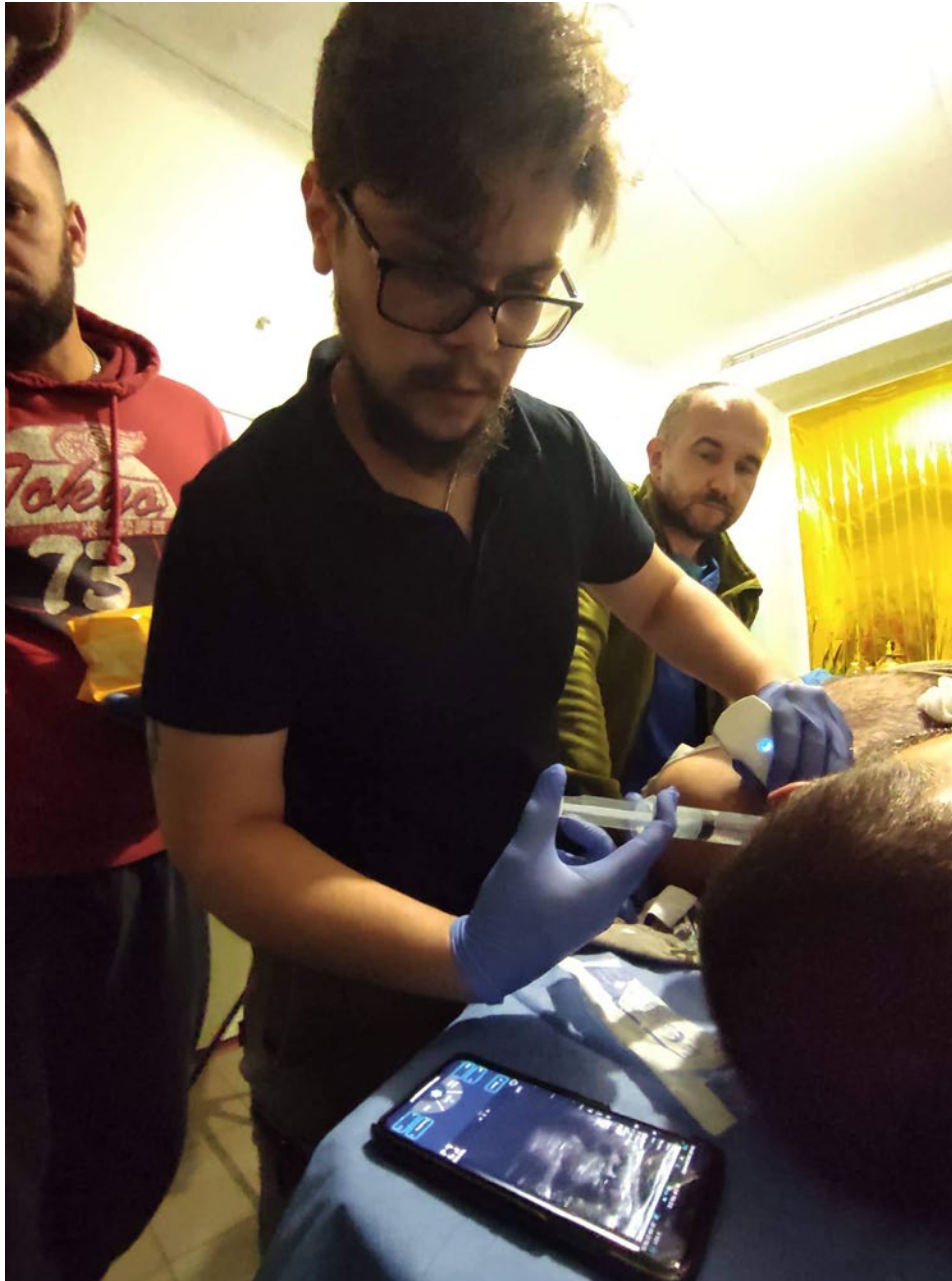

Ultrasound examination of a patient with suspected tension pneumothorax.



Ultrasound examination of a patient with mine explosive injuries.

THE USE OF ULTRASOUND IN BATTLEFIELD ENVIRONMENT DURING THE RUSSIAN INVASION OF UKRAINE



Regional methods of analgesia before evacuation.

MUSCULOSKELETAL ULTRASOUND – THE ADVANTAGES OF ULTRASOUND IN FRACTURES MANAGEMENT

**Stoicescu Emil Robert¹, Iacob Roxana¹, Manolescu Diana Luminita¹,
Cerbu Simona¹, Birsasteanu Florin²**

1. Discipline of Radiology and Medical Imaging, “Victor Babes” University of Medicine and Pharmacy Timisoara, 2. Discipline of Radiology and Medical Imaging, “Victor Babes” University of Medicine and Pharmacy Timisoara

Abstract body

Actuality and Aim: Fractures are among the most common medical-surgical emergencies in people of all ages. This study aims to prove that ultrasound can be used as a complementary method to radiographic or CT examinations due to its non-irradiant nature.

Material and Methods: Patients with fracture suspicion, both adults and children, but a negative/normal X-ray or patients with a lower suspicion of fracture, were evaluated using ultrasound to disprove or confirm the presence of a cortical bone discontinuity. The study included a total of 34 patients, aged between 4 – 68 years.

Results: Ultrasound was proven to be effective in the diagnosis of rib fractures, as well as in tracking the process of consolidation and callus formation, because it showed the callus much earlier than X-rays, being more sensitive. Another intriguing case involved a 35-year-old woman who complained of pain in her right lower limb and was suspected of having tendinopathy. A stress fracture in the second right metatarsus was discovered using musculoskeletal ultrasound.

Conclusions: Musculoskeletal ultrasonography can help in the diagnosis and follow-up of long bone fractures, especially when clinical suspicion is high and an X-ray did not reveal any cortical interruption. It is also a good way to detect early callus formation, helping in reducing serial and repetitive X-rays.

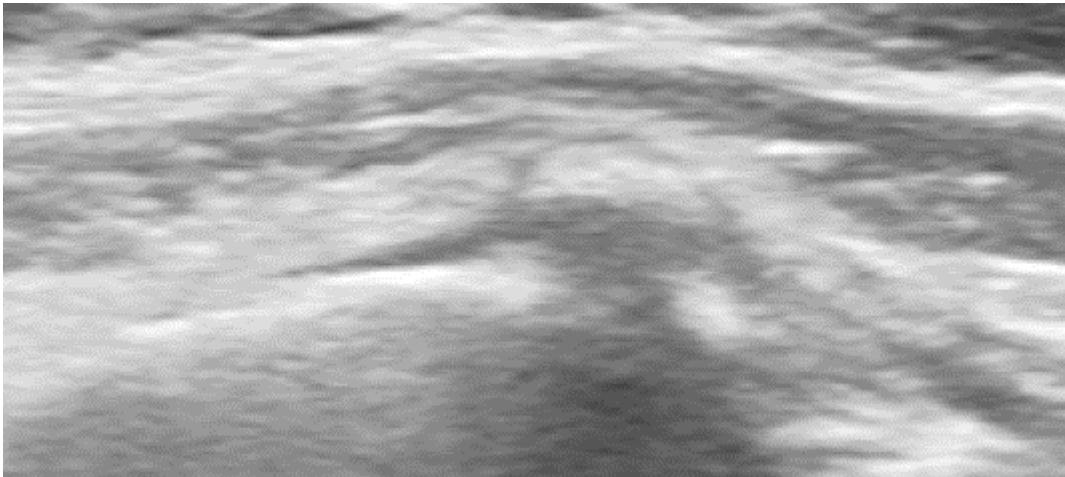
Only simple, linear fractures benefit from musculoskeletal ultrasonography.

Acknowledgements to all authors.

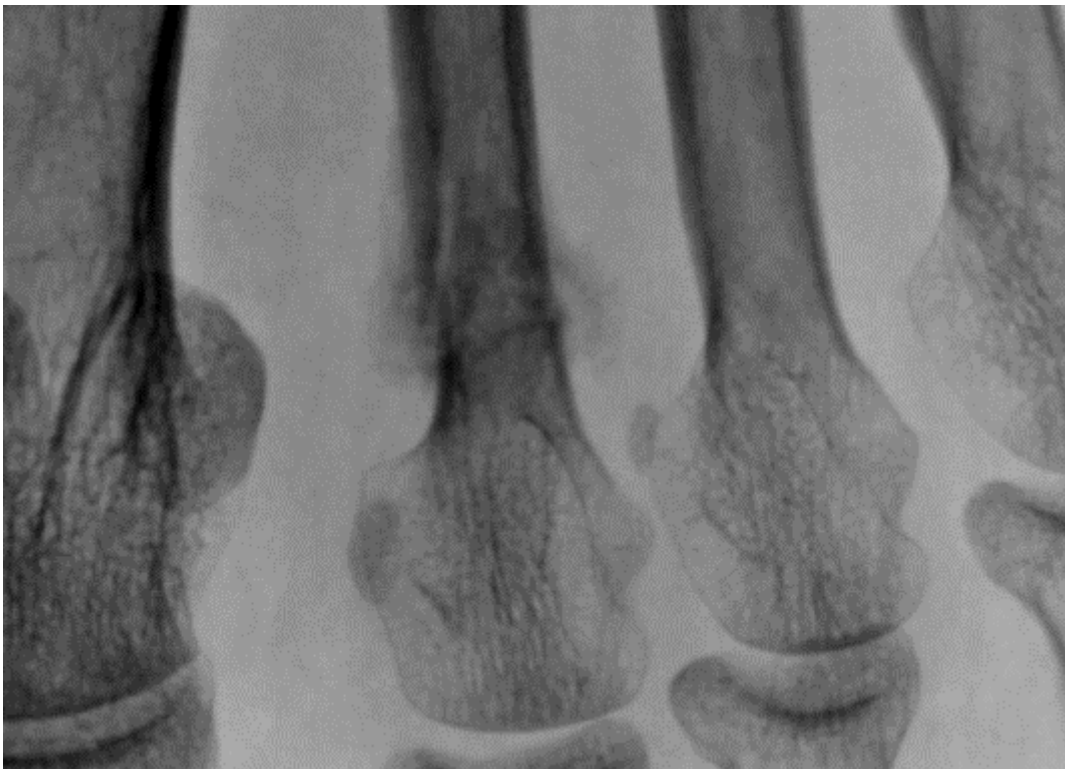References

Iacob R, Stoicescu ER et al. Could Ultrasound Be Used as a Triage Tool in Diagnosing Fractures in Children? A Literature Review. Healthcare. 2022; 10(5):823. <https://doi.org/10.3390/healthcare10050823>

MUSCULOSKELETAL ULTRASOUND – THE ADVANTAGES OF ULTRASOUND IN FRACTURES MANAGEMENT

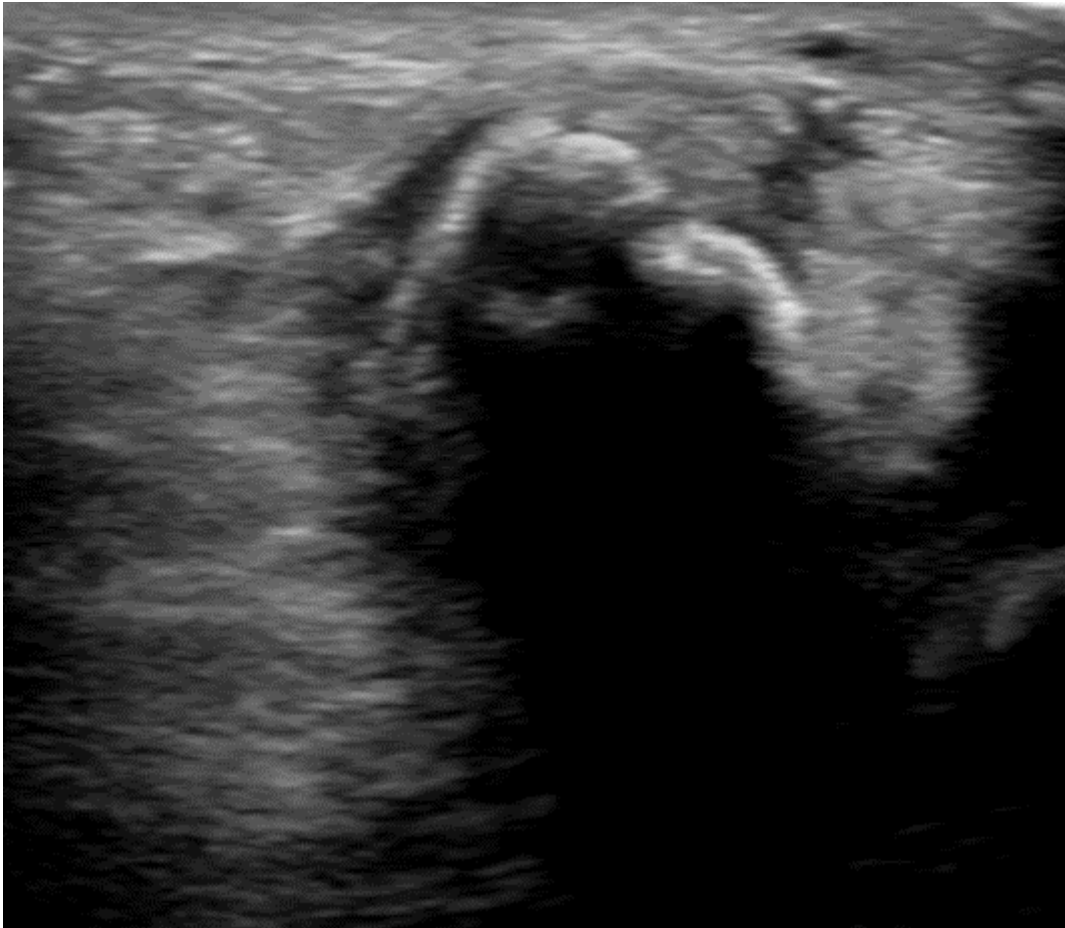

Healing of a rib fracture with callus formation



The X-ray shows a fracture of the second right metatarsus

MUSCULOSKELETAL ULTRASOUND – THE ADVANTAGES OF ULTRASOUND IN FRACTURES MANAGEMENT



The ultrasound shows a fracture of the second right metatarsus

NONINVASIVE ULTRASOUND TECHNIQUES TO DIAGNOSE CHRONIC EXERTIONAL COMPARTMENT SYNDROME: A PILOT CLINICAL TRIAL

Corinne E. Wessner¹, Corinne E. Wessner¹, Rachel Blackman¹, Corbin Pomeranz¹, Michael Hoy¹, Kristen Bradigan¹, Marc I Harwood², Levon Nazarian¹, Andrej Lyshchik³, Flemming Forsberg³

1. Department of Radiology, Thomas Jefferson University, Philadelphia, PA, 19107, 2. Non-Operative Sports Medicine Department, Rothman Orthopaedic Institute, Philadelphia, PA, 3. Department of Radiology, Thomas Jefferson University, Philadelphia, PA, 19107

Abstract body

Actuality and Aim: To noninvasively diagnose chronic exertional compartment syndrome (CECS) using subharmonic aided pressure estimation (SHAPE) and shear wave elastography (SWE) compared to invasive compartment pressure testing as reference standard.

Methods: Healthy volunteers (HVs) and patients with CECS were enrolled in this ongoing IRB-approved study. Study groups underwent ultrasound before and immediately after exercise. Patients were scanned using a Logiq E10 scanner (GE Healthcare) with C2-9 probe. For SHAPE, 3ml of ultrasound contrast agent Definity (Lantheus Medical Imaging) was infused and three 5s clips were acquired sequentially. Regions of interests were drawn offline around the symptomatic compartment muscle and an adjacent vessel pre- and post-SHAPE. After SHAPE, the patient performed an exercise protocol for ~6 minutes. Immediately after exercise, SHAPE clips were acquired again. SWE color maps were generated pre- and post-SHAPE and analysed off-line using shear wave velocity (m/s).

Results: Data analysis in 10 healthy volunteers and 4 CECS patients (mean age of HVs 33±16 years and CECS patients 27±5 years (p=0.03)). Linear regression analysis was statistically significant when evaluating the correlation between compartment pressure testing results (in mmHg) and SHAPE estimates (R² = 0.96; p = 0.02). When evaluating SWE in the HVs from pre- to post- exercise there was a difference (p=0.01, 1.15m/s ±0.17 to 1.28m/s ±0.22), which was not seen in the CECS patients (p=0.14, 1.12m/s ±0.13 to 1.39m/s ±0.21).

Conclusions: Preliminary results demonstrate that non-invasive ultrasound techniques may be an alternative method for evaluating CECS patients.

Acknowledgements: RSNA R&E Foundation #RR1957, NIH R01DK118964

References

N/A

ULTRASONIC TIME-HARMONIC SHEAR WAVE ELASTOGRAPHY OF THE VASTUS MEDIALIS

Pascal Engl¹, Heiko Tzschätzsch², Tom Meyer², Ingolf Sack², Michael Schultz³, René Schwesig⁴, Eduard Kurz⁴, Stephan Schulze⁴, Thomas Bartels⁵, Klaus-Vitold Jenderka¹

1. Merseburg University of Applied Sciences, Eberhard-Leibnitz-Str. 2, 06217 Merseburg, Germany,
2. Department of Radiology, Charité-Universitätsmedizin Berlin, Charitéplatz 1, 10117 Berlin, Germany,
3. Gampt mbH, Hallesche Straße 99F, 06217 Merseburg, Germany, 4. Department of Orthopedic and Trauma Surgery, Martin-Luther-University Halle-Wittenberg, 06120 Halle, Germany,
5. MVZ Sportklinik Halle GmbH, Weidenplan 16-17, 06108 Halle/Saale, Germany

Abstract body

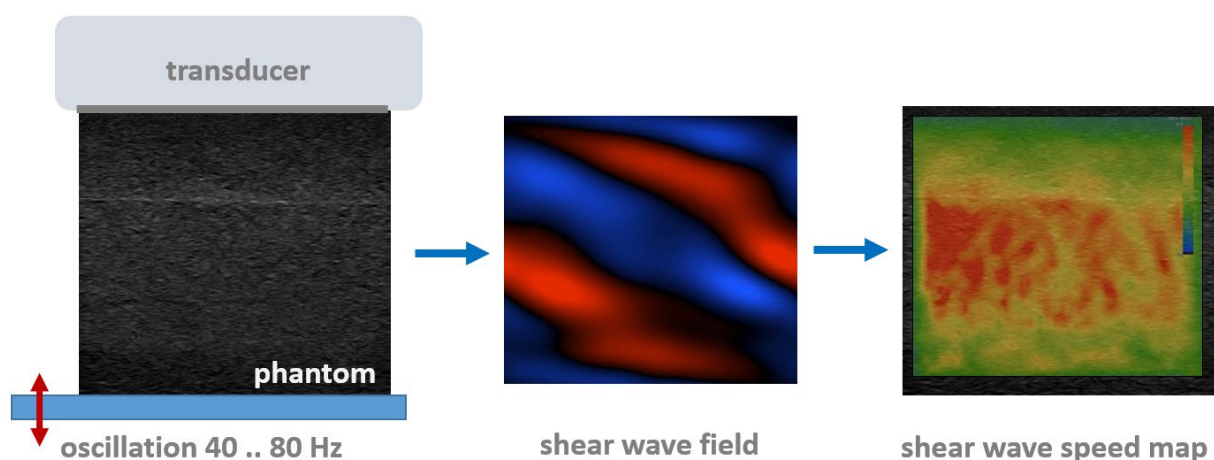
In the field of rehabilitation, the assessment of valid „return-to-sport“ criteria is crucial for long-term success. One indicator of restored functionality can be stiffness of the muscle tissue in relation to tension.

In this work, we have developed a measurement setup to study the stiffness of the vastus medialis muscle by means of ultrasonic time-harmonic elastography. The elastic properties were derived from the speed of shear waves propagating through the tissue. The shear waves were excited by an external vibration unit, which was driven by a multi-harmonic signal with frequencies between 45 and 79 Hz. In addition to stiffness measurements in the relaxed state, the amount of muscle tension was quantified by a force-load cell.

Initial experiments in unaffected participants showed the expected increase of shear wave speed with force load (20% per 100 N). Furthermore, shear wave speed along and transverse to the muscle fibers was determined to be (1.8 ± 0.3) m/s and (1.3 ± 0.2) m/s, respectively.

References

M. Grossmann et al., „US Time-Harmonic Elastography for the Early Detection of Glomerulonephritis,” *Radiology*, vol. 292, no. 3, pp. 676-684, Sep. 2019, doi: 10.1148/radiol.2019182574.



2D-mapping of SWS in a tissue-mimicking phantom with US-THE

ULTRASOUND IMAGING OF THE COMBAT-RELATED SOFT TISSUE TRAUMA IN UKRAINIAN SOLDIERS

Kitija Nulle¹

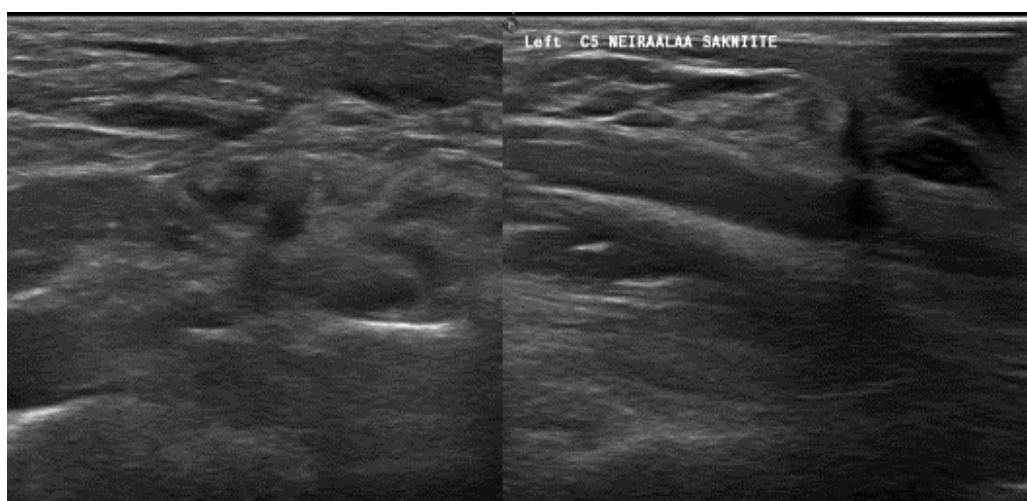
1. Riga East Clinical University hospital

Abstract body

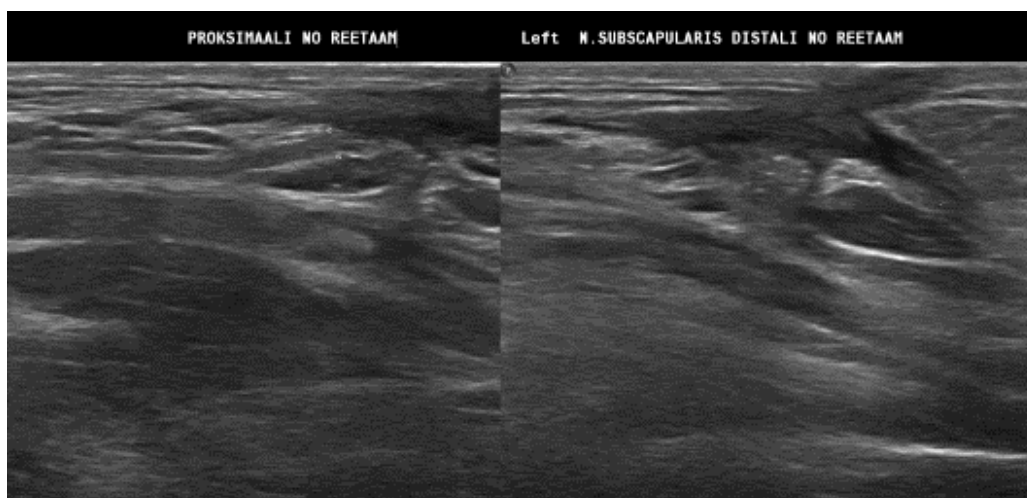
In august and in november of year 2022 numerous of Ukrainian solders were transferred to Riga East Clinical University hospital for therapy and rehabilitation. This presentation reviews multiple cases of Ukrainian soldiers with soft tissue combat injury, discusses impact on life.

References

Ankur Goyal, Imaging of traumatic peripheral nerve injuries; J Clin Orthop Trauma. 2021 Oct; 21: 101510.

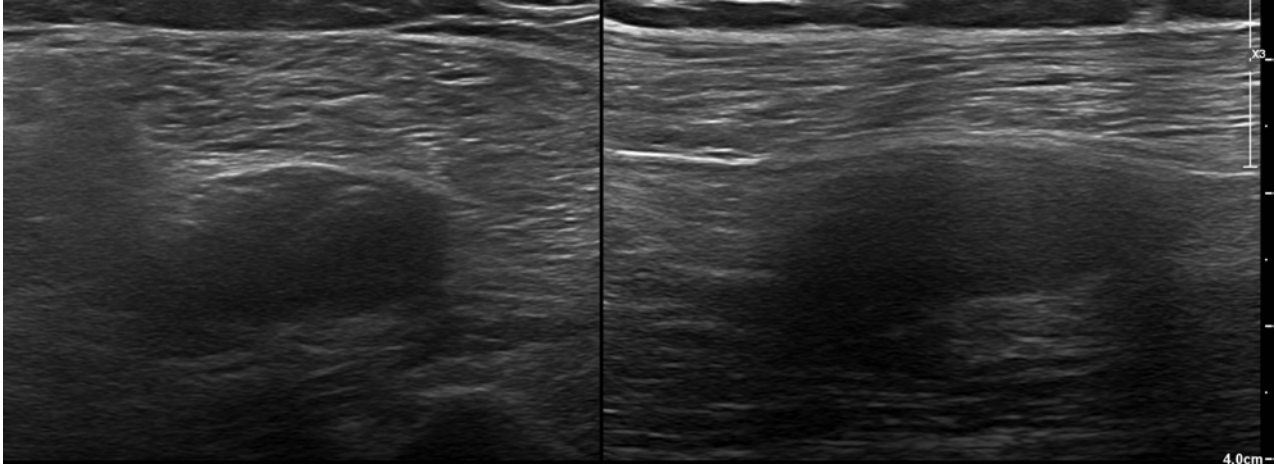


Neuropathy oc C5 root prom neural foramina.



Injury and scarring of subscapular nerve.

ULTRASOUND IMAGING OF THE COMBAT-RELATED SOFT TISSUE TRAUMA IN UKRAINIAN SOLDIERS



Total injury of sciatic nerve.

CHARACTERIZATION OF COMPLEX OVARIAN MASSES ON ULTRASOUND MOLECULAR IMAGING AND CORRELATION WITH SURGICAL HISTOPATHOLOGY

Ahmed El Kaffas¹, Neha Antil¹, Ann Folkins¹, Huaijun Wang¹, Teri A Longacre¹, Jonathan S. Berek¹, Ahmed El Kaffas¹, Amelie Lutz¹

1. Stanford University

Abstract body

Aim: To characterize ovarian masses (OMs) on ultrasound molecular imaging (USMI) using [KDR]-targeted contrast microbubble [MBKDR] and correlate with gold standard surgical histopathology (HPE).

Material&Methods: USMI was performed in 24 women with complex OMs. MBKDR were manually injected over 10 seconds followed by 10 mL saline flush. Imaging was obtained starting with initial 45 seconds acquisition to capture the wash-in phase of MBKDR, followed by 10 second acquisition every 2 mins until 30 minutes. Surgery for these OMs were performed within 2-week interval following imaging. Quantitative USMI analysis was performed by two radiologists in consensus who were blinded to final HPE diagnosis. ROI was drawn over the target lesion and mean contrast signal intensity was calculated. USMI analysis was then correlated with HPE results.

Results: 22/24 (92%) lesions were confirmed in the ovaries on surgical HPE and were analyzed. 13/22 (59%) lesions were malignant and 9/22 (41%) lesions were benign. Overall, Quantitative USMI analysis showed a sensitivity of 100% (13/13), specificity of 88.89% (8/9), PPV of 92.85% (13/14) and NPV of 100% (8/8), when compared to gold standard HPE.

Conclusion: Quantitative Targeted USMI shows promising results that allows non-invasive accurate characterization of OMs without any malignant lesions miscategorized as benign. However, this requires further validation.

References

- Willmann JK, Bonomo L, Testa AC et al. USMI with BR55 in patients with breast & ovarian lesions: First-in-human results. J Clin Oncol. 2017;35(19):2133-40.
- Lutz AM, Willmann JK, Drescher CW et al. Early diagnosis of ovarian carcinoma: Is a solution in sight. Radiology. 2011;259(2):329-45

SHEAR WAVE ULTRASOUND ELASTOGRAPHY OF MALIGNANT BREAST LESIONS: MEASURED VALUES WITH DIFFERENT REGION OF INTEREST AND LESION SIZE

**Antonio Bulum¹, Gordana Ivanac¹, Marta Bulum¹, Iva BiondićŠpoljar¹,
Eugen Divjak¹, Kristina Bojanić², Boris Brkljačić¹**

1. University hospital Dubrava, Zagreb, Croatia, 2. Health center Osječko-Baranjska County, Osijek, Croatia

Abstract body

Actuality and Aim:

The aim of this study was to determine the effect of different region on interest (ROI) and lesion size on the measured values of the elastic modulus and elasticity ratio of malignant breast lesions using shear wave elastography (SWE).

Material and Methods:

150 female patients were enrolled in this retrospective single-centre study. Elastic modulus and e-ratio value were measured by using a circular ROI size of 2 mm, 4 mm and 6 mm, measured by placing the centre of the ROI at the place of the maximum measured elastic modulus value in the SWE acquisition box. In addition to that, a second ROI was placed over the surrounding fatty tissues and corresponding e-ratio values were obtained. Furthermore, all lesions were divided into small and large ones, 15 mm diameter was used as a cut-off value.

Results:

The highest values of the elastic modulus and lowest variability were obtained by using the 2 mm ROI. The same was observed with the measured elasticity ratio values as well. Differences between the measured values using different ROI sizes were significantly more pronounced when measuring larger lesions in comparison to smaller lesions. Emax values were not significantly different regardless of ROI size.

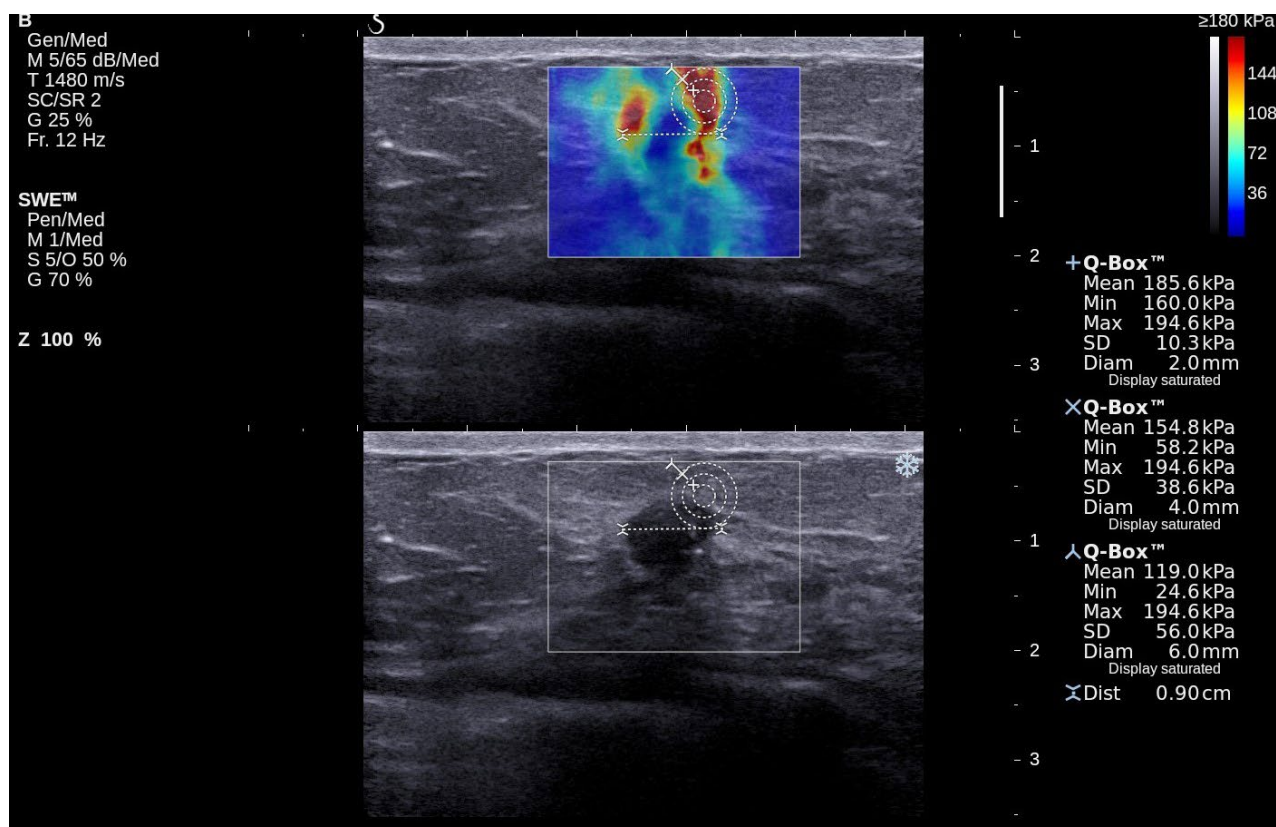
Conclusions:

When measuring the elastic modulus and elasticity ratio of malignant breast lesions, the smallest possible ROI size should be used regardless of lesion size. ROI size has no impact on measured Emax values.

References

1. Barr, R. Sonographic breast elastography: A primer. J. Ultrasound Med. 2012, 31, 773-783.

SHEAR WAVE ULTRASOUND ELASTOGRAPHY OF MALIGNANT BREAST LESIONS: MEASURED VALUES WITH DIFFERENT REGION OF INTEREST AND LESION SIZE



Ultrasound examination with shear wave elastography and the measurements.

UNNECESSARY BIOPSY RATES OF BIRADS-4A LESIONS: CAN ELASTOGRAPHY DECREASE THE RATES?

Düzgün CanSenbil¹, Sonay Aydın¹

1. Erzincan Binali Yıldırım University Faculty of medicine

Abstract body

Objectives

Breast MRI is extremely sensitive. However, the false positive rate is high. Many benign lesions are biopsied as a result of this situation(1). By calculating the stiffness of the lesions, ultrasonography and swe can assist in determining the BIRADS class(2). The aim of our study is to evaluate BIRADS-MRI 4a lesions with SWE and to reduce unnecessary biopsies.

Methods

The study included 95 patients who were diagnosed with BIRADS 4a by breast-MRI between January 2020 and April 2021. In all patients, ultrasonography and SWE were performed concurrently. Using the 5th edition of the BIRADS atlas, SWE results were classified as soft, medium, or hard. The gold standard method was biopsy results.

Results

An ultrasound-guided biopsy was not performed when BI-RADS-MRI category 4a, BI-RADS-US category 3-4a, the stiffness result as soft or intermediate (strain ratio 1.335) in elasticity assessment according to the fifth edition of the BI-RADS atlas, age 52 years, and the maximum diameter of lesion 20 mm were all met at the same time. Biopsies were abandoned in 30 of 95 patients, and the total number of biopsies performed was reduced by 31%.

Conclusion

BIRADS MRI 4a is an effective method for assessing lesions. SWE will reduce biopsies, injuries, and patient anxiety.

Acknowledgements

References

1. Smetherman DH. Screening, imaging, and image-guided biopsy techniques for breast cancer. Surg Clin North Am 2013; 93: 309- 327.
2. Carlsen J, Ewertsen C, Sletting S, et al. Ultrasound elastography in breast cancer diagnosis. Ultraschall Med 2015; 36: 550- 562

ULTRASOUND SHARE WAVE ELASTOGRAPHY (2D-SWE) IN THE DIAGNOSIS AND EVALUATION OF VITEX AGNUS-CASTUS TREATMENT MYSTODYNIA AND MASTOPATHY

Zhanna Makarova¹, Oleh Dynnyk², Oleksandr Fedusenko²,
Anatolii Fedusenko jr.³

1. Director, 2. PhD, Associate Professor, 3. Doctor

Abstract body

Actuality. Due to the high prevalence of mastodynia, mastopathy (risk factors breast cancer) among women, the issues of their diagnosis are very relevant.

Aim. Diagnosis, evaluation of AGNUS-CASTUS treatment in patients with mystodynia, mastopathy by 2D-SWE. **Methods.** Using 2D-SWE, soft tissue of breast stiffness was investigated in 32 women aged 18-52 with cyclic mastalgia/mastopathy before and after AGNUS-CASTUS treatment. A correlation was made with prolactin level, general state of the breast according to the results of ultrasonography (thickness parenchyma, dilation milk ducts, presence of simple cysts and their dynamic changes due to treatment). Control group 78 women without complaints, without signs of breast pathology.

Results. 2D-SWE method obtained normal values of the stiffness of the breast tissues (fat, parenchyma) in women without pathology. In symptomatic women, 2D-SWE made it possible to detect an increase in the stiffness of glandular, thereby screening for its diffuse changes. Statistical evidence of the positive effect of AGNUS-CASTUS drugs in the treatment of mastodynia/mastopathy has been proven.

Conclusions. Assessment of the basic stiffness of breast tissues using 2D-SWE makes it possible to screen patients with elevated values. This fact makes it possible to attribute these women to the risk group for the development of breast cancer. Evaluation changes in the mechanical stiffness properties of the breast allows to evaluate and objectify the effectiveness of the treatment being carried out.

References

WFUMB Guidelines and Recommendations for Clinical Use of Ultrasound Elastography: Part 2: Breast / Richard G. Barr et al // Ultrasound in Medicine & Biology. 2015

BREAST CANCER OF YOUNG WOMEN. PREVENTION, PROBLEMS OF PREGNANCY AND LACTATION. RETROSPECTIVE STUDY

Jana Slobodníková¹

1. radiologist

Abstract body

Introduction: We meet more often with the occurrence of breast cancer in women in 30s and significantly between 20 and 40 years.

Methodology: In period from 1.5.2007 and 30.6.2022 we performed more more than 185,000 ultrasound examinations. Preventive examinations completed asymptomatic women without clinical symptoms. Young women were examined by ultrasound, next if necessary, we performed mammography, MR-mammography a CCB too. During the monitored period we diagnosed 398 new cases of the breast cancer, all cases are verified by histopathology. In the category women between 18s and 39s, we diagnosed 32 new cases of breast cancer, between 40s and 49s - 64 cases. Summary is that, we found 86 new cases of breast cancer in women between 18 and 49 years. We analyzed the different findings, especially with respect to possibility of diagnostic self-examination, combined with ultrasound, MR mammography, mammography and core cut biopsy under ultrasound control.

Conclusion: We also want to draw attention to some underestimation of clinical symptoms, while revaluation results of sonographic examinations.

References

1. Apple, S.K., Doepke, L., Bassett, L.W.: Benign cystic Lesions of the Breast, in: Breast Imaging, Elsevier, 2011, ISBN : 978-1-4160-5199-2, str. 239-254
2. Lehman CD, Lee CI, Loving VA, Portillo MS, Peacock S, DeMartini WB (2012) Accuracy and value of breast ultrasound for primary imaging evaluation of symptomatic women 30-39 years of age. AJR Am J Roentgenol 199:1169-1177
3. Kopans D.B.: It's tiem to stop the misinformation about breast cancer screening, in :Screening and Beyond,m ESR. EUSOBI, 2016, ISBN 978-3.9504388-3-3, 188 pp

PROTOCOL OF BREAST CANCER PREVENTION MODEL WITH ADDITION OF BREAST ULTRASOUND TO ROUTINE GYNECOLOGICAL VISITS IN PATIENTS 25-49 YEARS OLD

Marcin Sniadecki¹, Paulina Jaworek¹

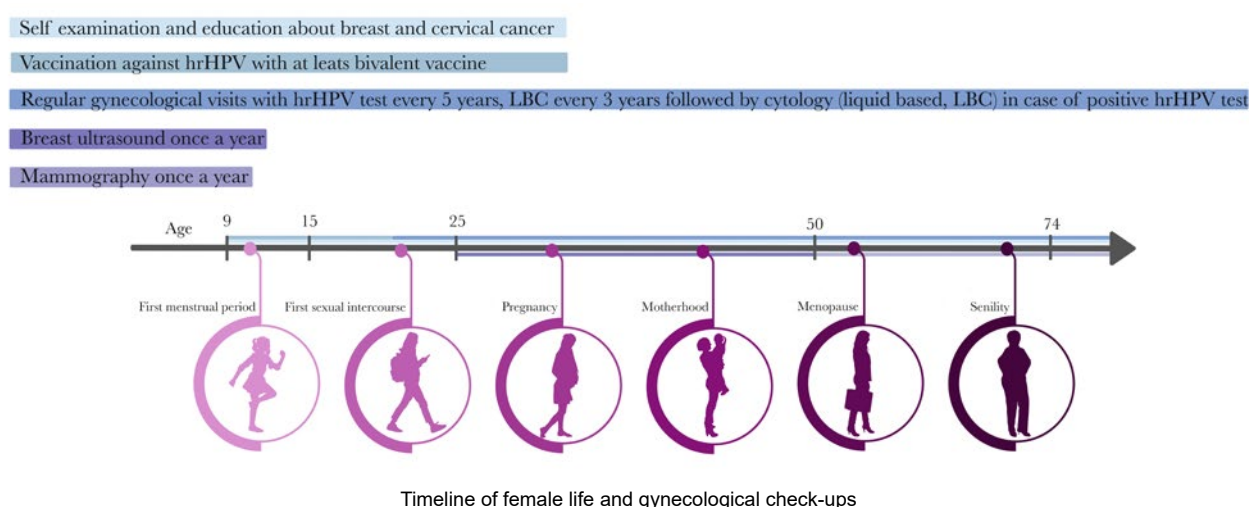
1. Medical University of Gdańsk

Abstract body

Actuality and aim: Of the four, breast cancer and cervical cancer are among the 10 most common malignant neoplasms globally, regardless of gender, and are known to have effective screening measures. Our research aims to create a screening model that combined cervical cancer and breast cancer to maximize health outcomes for women at risk of both cancers. **Methods:** GynSen, which is a nationwide screening model, will test all women below the age of 49 years attending gynecological consultations. There is growing evidence that prophylactic ultrasound examination should be indicated for average-risk women <40 years old. **Results:** the strategy explained in this model protocol is expected to bring positive outcomes on breast cancer diagnosis in patients excluded from the other breast cancer prevention programs as well as the overall growth of the popularity of female cancer prevention screening. Combining two programs and advertising them as a strategy for a healthy lifestyle will possibly convince females that their health is very important and it doesn't have to be expensive and time-consuming. **Conclusion:** We conclude that our model merits consideration and discussion among health care decision makers, as the screening changes we propose have significant potential benefits for female population. **Acknowledgements:** Patient Anna T., whose case was described in success story section and Przemysław Maniara (Sonolife Company, Poland).

References

Will be provided over e-mail since it consists 36 positions.



DYNAMIC ULTRASOUND IMAGING OF THE ULNAR NERVE MOVEMENT AT THE LEVEL OF ELBOW: SONOANATOMY AND ASSOCIATED FINDINGS

Kitija Nulle¹

1. RAKUS "Gaiļezers"

Abstract body

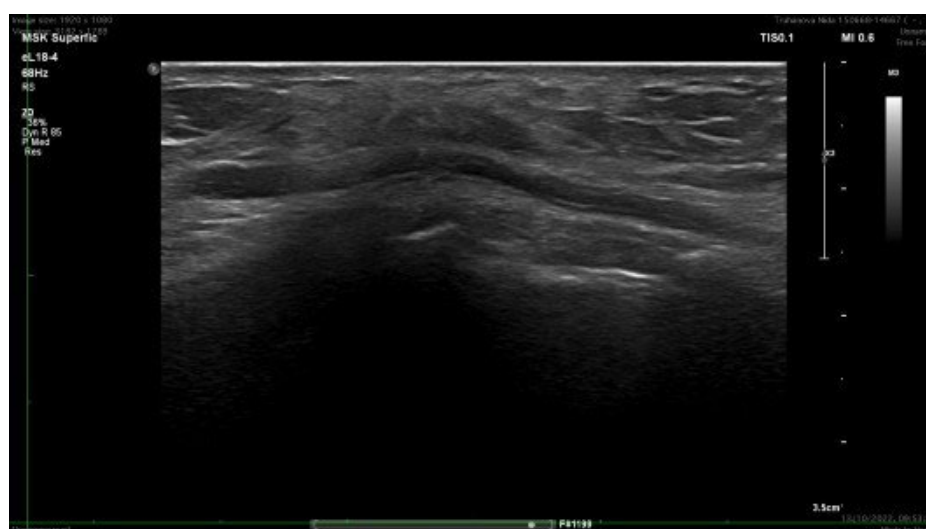Ulnar nerve neuropathy at the level of elbow is second most common peripheral nerve entrapment. Many conditions that might cause the neuropathy of the ulnar nerve have been recognised. Although some of these conditions are less uncommon and often overlooked while performing the examination of the elbow joint. It has been proposed that ulnar nerve hypermobility can contribute to pain syndrome and friction injury; however, it has been also suggested that hypermobility of the ulnar nerve protects against neuropathy due to reduction of tension along the ulnar nerve. Furthermore, even if the cause of pathology is obvious it is still advisable to evaluate the mobility of ulnar nerve and its relations to surrounding structures. It is hard to imagine second such nerve that's mobility and functional anatomy is so widely debated. This presentation reviews the literature on the subject, anatomy of the ulnar nerve and the surrounding structures, and presents relevant cases from the personal archive with the aim of bringing the knowledge of the topic, standardising terminology and raising an awareness on an important aspect of dynamic ultrasound imaging of elbow.

References

Childress, H. M.: Recurrent ulnar-nerve dislocation at the elbow, J Bone Joint Surg. 168-173; 1975

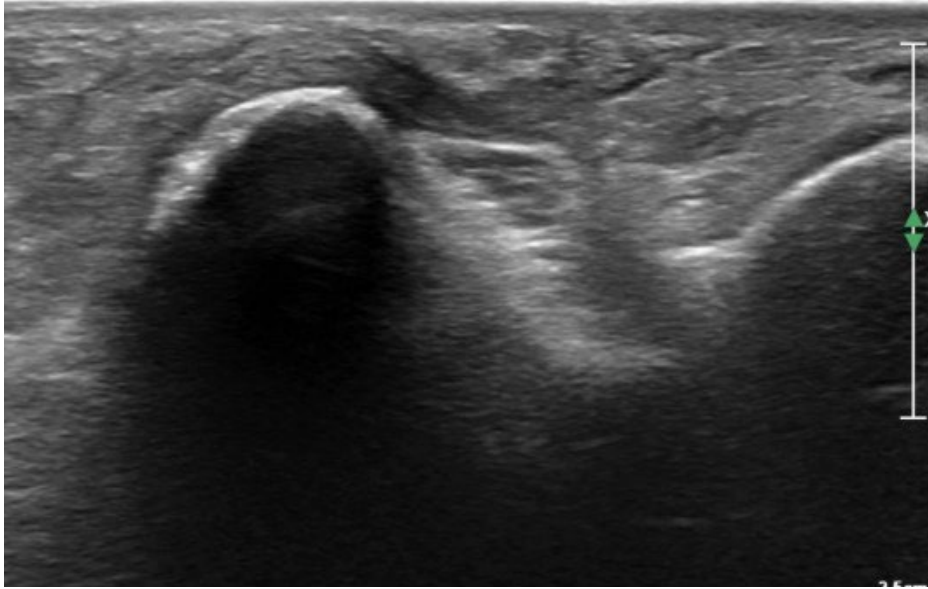
Stephen J.Bordes Jr. Ulnar nerve subluxation and dislocation: the review of the literature, Neurosurgical rev; 2020

Robert J. Spinner. Unrecognised dislocation of the medial portion of the triceps: another cause of failed ulnar nerve transposition, J Neurosurg 92:52-57; 2000

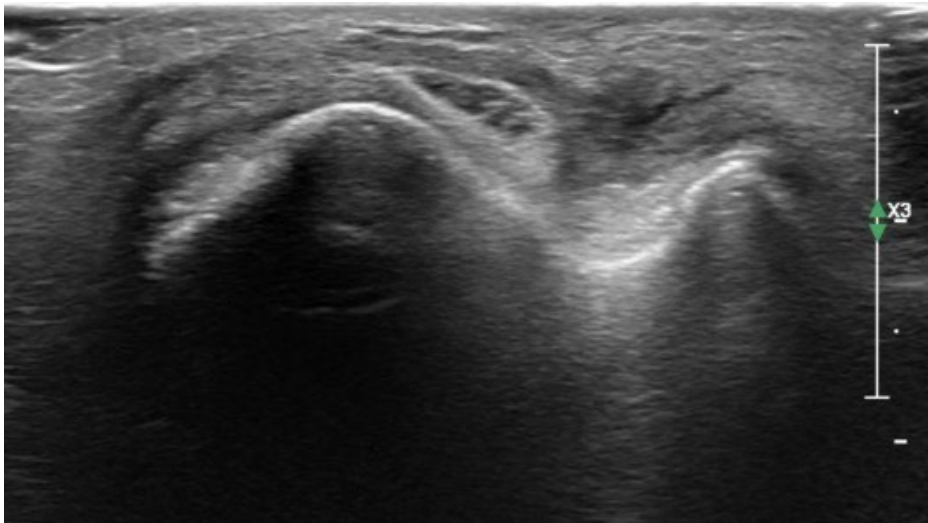


M.anconeus trochlearis and n.ulnaris at the level os cubital tunnel.

DYNAMIC ULTRASOUND IMAGING OF THE ULNAR NERVE MOVEMENT AT THE LEVEL OF ELBOW: SONOANATOMY AND ASSOCIATED FINDINGS



Ulnar nerve when elbow joint is extended.



Ulnar nerve when elbow joint is flexed.

ULTRASONOGRAPHIC EVALUATION OF POST-TRAUMATIC CHANGES IN CAROTID AND VERTEBRAL ARTERIES.

Mateusz Cheda¹, Agata Zarajczyk², Maria Materek², Maryla Kuczyńska¹, Anna Drelich-Zbroja¹

1. Department of Interventional Radiology and Neuroradiology, Medical University of Lublin,

2. Students' Scientific Society at the Department of Interventional Radiology and Neuroradiology, Medical University of Lublin

Abstract body

Aim: The assessment of usefulness of ultrasound examination in the diagnosis of post-traumatic changes in the carotid and vertebral arteries.

Materials and Methods: In the period of 7 years (2016-2022), a group of 265 patients was sent to the Department of Interventional Radiology and Neuroradiology at the Medical University in Lublin to confirm / rule out post-traumatic changes. All patients underwent ultrasound examinations of extracranial carotid and vertebral arteries using the B-mode option as well as color and spectral Doppler.

Results: In the ultrasound examination: 5 patients were diagnosed with internal carotid artery (ICA) pseudoaneurysms, 2 patients had an ICA thrombus, 3 patients had dissection of the vertebral artery, 1 patient had subclavian artery dissection, in 4 patients dissection of the common carotid artery was diagnosed, in 2 patients dissection of the brachiocephalic trunk and common carotid artery was observed. On the basis of ultrasound examination of 5 patients with pseudoaneurysms and 4 patients with stratification, they were qualified for endovascular treatment.

Conclusion: US is the method of choice in the diagnosis of post-traumatic changes in the extracranial segments of the carotid and vertebral arteries. It allows their unambiguous confirmation / exclusion and qualification of patients for endovascular treatment.

Acknowledgements: none

References

1. Scutt, Leslie M, and Gowthaman Gunabushanam. "Carotid Ultrasound." Radiologic clinics of North America vol. 57,3 (2019): 501-518. doi:10.1016/j.rcl.2019.01.008
2. Ramamurti, Pradip et al. "Vertebral Artery Injury in the Cervical Spine: Anatomy, Diagnosis, and Management." JBJS reviews vol. 9,1 e20.00118. 19 Jan. 2021, doi:10.2106/JBJS.RVW.20.00118

CAROTID PLAQUE INSTABILITY AND NEOVASCULARIZATION ASSESSMENT WITH CONTRAST – ENHANCED ULTRASOUND (CEUS) AND SUPERB MICROVASCULAR IMAGING

Andrejs Lioznovs¹, Maija Radziņa², Aigars Lācis³, Inese Briede³, Pēteris Grinbergs⁴

1. Pauls Stradins Clinical University Hospital, Riga, Latvia; Riga Stradins University, Riga, Latvia, 2. Pauls Stradins Clinical University Hospital, Riga, Latvia; University of Latvia, Faculty of Medicine, Riga, Latvia; Riga Stradins University, Radiology Research Laboratory, Riga, Latvia, 3. Pauls Stradins Clinical University Hospital, Riga, Latvia; Riga Stradins University, Riga, Latvia, 4. Riga Stradins University, Students, Riga, Latvia

Abstract body

Purpose: Incidence of stroke every year increases worldwide, According to World Health Organization In 2020, 1 in 6 deaths from cardiovascular disease was due to stroke, about 87% of all strokes are ischemic strokes. CEUS and SMI is used to detect neovascularization, as a one of the main factor of atherosclerotic plaques instability.

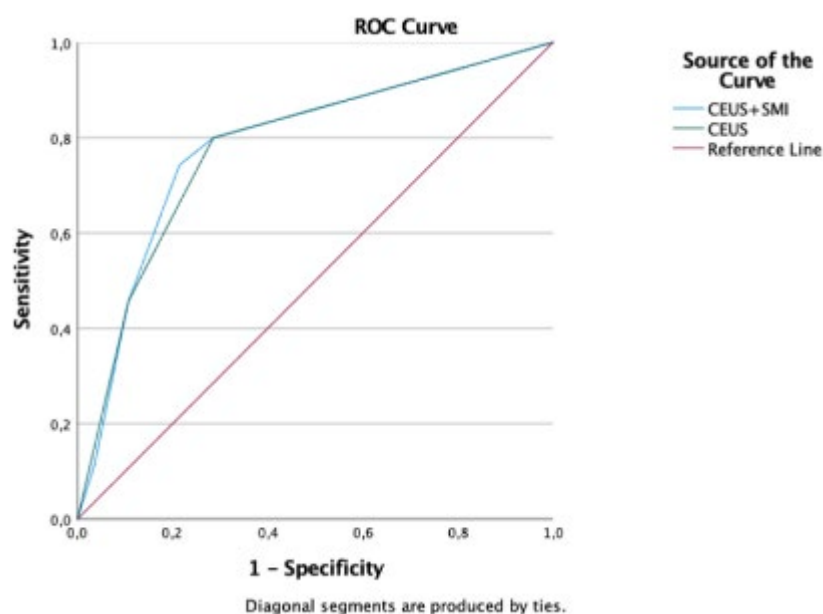
Method or Background: During the prospective research, 88 patients underwent Doppler ultrasound examination, and significant hemodynamic plaques (>50% stenosis) were detected, following SMI and CEUS. The neovascularization was categorized in three categories (Grade 0, Grade 1, Grade 2) and results were compared to histological finding from endarterectomies in 62 patients.

Results: There was a positive correlation between SMI and histological material, $r=0.319$; $p=0.01$. Also, positive correlation was found between CEUS and histological material, $r=0.456$; $p=0.0001$. Moderate positive correlation was observed between CEUS and SMI $r=0.669$; $p=0.0001$. However, ROC curve analysis showed that SMI is less sensitive than CEUS (51.22% vs 80.56%). CEUS method is valued with the sensitivity- 80.56%, specificity- 77.75%, accuracy- 79.29% with limitation among calcified plaques.

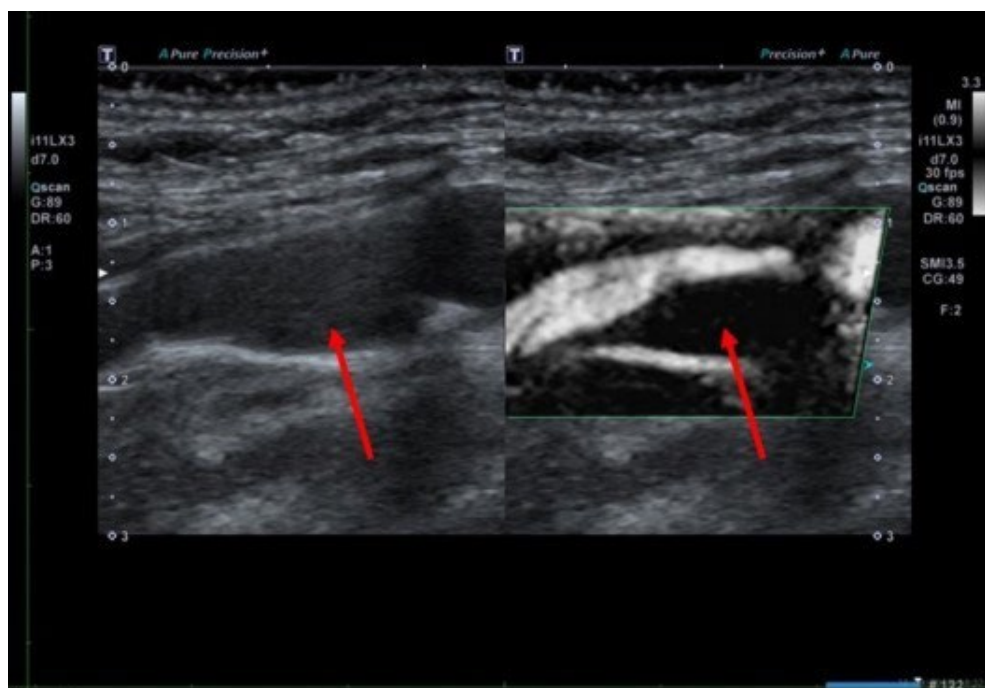
Conclusion: CEUS is minimally invasive ultrasound method that is more accurate for carotid plaque instability evaluation than US doppler or microvascular imaging and it should be advised in clinical practice for patients with carotid artery atherosclerotic changes. However, the sensitivity of CEUS and SMI decreases in markedly calcified plaques.

References <https://www.worldlifeexpectancy.com/latvia-stroke;>
<https://cdt.amegroups.com/article/view/36014/html;>
<https://pubmed.ncbi.nlm.nih.gov/26025869;>

CAROTID PLAQUE INSTABILITY AND NEOVASCULARIZATION ASSESSMENT WITH CONTRAST – ENHANCED ULTRASOUND (CEUS) AND SUPERB MICROVASCULAR IMAGING

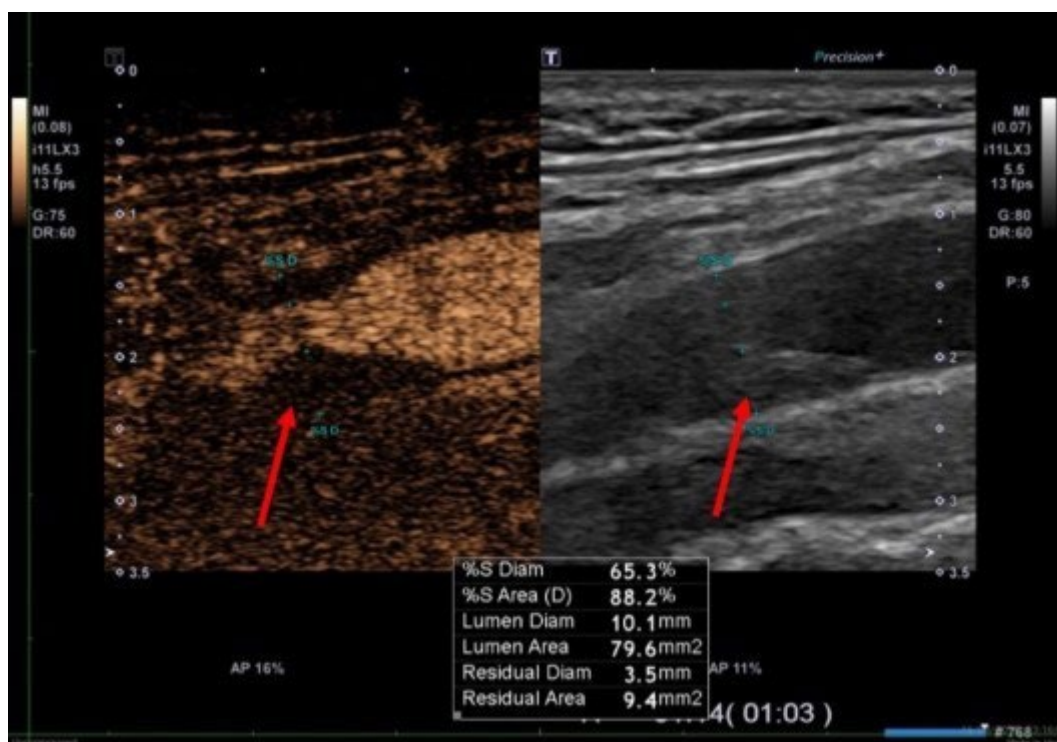


ROC Curve: CEUS method is valued with the sensitivity-80.56%, specificity-77.75%.



SMI/B mode: Grade 0 neovascularization within carotid soft atherosclerotic plaque.

CAROTID PLAQUE INSTABILITY AND NEOVASCULARIZATION ASSESSMENT WITH CONTRAST – ENHANCED ULTRASOUND (CEUS) AND SUPERB MICROVASCULAR IMAGING



CEUS/Bmode: Grade 0 neovascularization within carotid soft atherosclerotic plaque.

ANALYSIS OF NEOVASCULARIZATION IN CAROTID ATHEROSCLEROTIC PLAQUE IN PATIENTS WITH CEREBRAL INFARCTION BY CONTRAST-ENHANCED ULTRASOUND

Juan Cheng¹

1. Xinhua Hospital Affiliated to Shanghai Jiaotong University School of Medicine

Abstract body

Objective: To quantitatively analyze and compare the enhancement degree of contrast-enhanced ultrasound (CEUS) in plaques of cerebral infarction and non-cerebral infarction patients.

Methods: 1. Subjects: 82 patients (a total of 106 plaques) underwent carotid CEUS examination in the ultrasound department of Xinhua hospital from September 2021 to March 2022, including 49 males and 33 females, aged 41-81 years. The patients with previous acute cerebral infarction were in the cerebral infarction group (30 patients with 41 plaques), and others were in the control group (52 patients with 65 plaques). 2. Instruments and methods: Aplio500 ultrasonic diagnostic instrument, 14L5 linear array probe, frequency 5-14MHz. Patches with thickness >1.5mm were selected for CEUS(SonoVue 2.0ml) . The plaque enhancement of CEUS was divided into four grades. After the contrast, quantitative analysis software was used for offline analysis.

Results: 1. The intensity of CEUS enhancement in the cerebral infarction group was higher than that in the control group ($P<0.05$). 2. The peak intensity|peak intensity Ratio and AUC in cerebral infarction group was higher than that in control group ($P<0.05$).

Conclusion: Quantitative analysis of CEUS is helpful to judge stability of plaque and provide evidence for clinical treatment.

References

1. Zamani M, Skagen K, Scott H, Lindberg B, Russell D, Skjelland M. Carotid plaque neovascularization detected with superb microvascular imaging ultrasound without using contrast media. *Stroke* 2019;50:3121-7
2. Pletsch-Borba L, Selwaness M, van der Lugt A, Hofman A, Franco OH, Vernooij MW. Change in carotid plaque components: a 4-year follow-up study with serial MR imaging. *JACC Cardiovasc Imaging* 2018;11:184-92

DOPPLER ULTRASOUND IN PARENCHYMAL EMERGENCIES: KNOW-HOW AND INTERPRETION

Francesca De Chiara¹, **Marco Di Serafino**², **Francesca De Chiara**¹,
Dalila De Lucia¹, **Vito Cantisani**³, **Gianfranco Vallone**¹

1. Department of Medicine and Health Sciences "V. Tiberio", University of Molise, Campobasso,

2.1) Department of Medicine and Health Sciences "V. Tiberio", University of Molise, Campobasso

2) General and Emergency Radiology Department "A. Cardarelli" Hospital, Naples,

3. Department of Radiological Sciences Univ. Sapienza, Rome

Abstract body

Learning objectives:

Describe the diagnostic role of pulse-wave Doppler-ultrasound (PWD-US) in parenchymal emergencies through analysis of the spectral curve.

Background:

Grayscale B-mode-US is the initial diagnostic tool for patients suspected of having acute organ disease. PWD-US integrates B-mode-US with semiquantitative parameters to record the V/t curve in the afferent artery and intraparenchymal circulation.

Findings:

The physiological spectral curve of parenchymal arterial flow typically shows low resistance, represented by a steep systolic front due to the sharp acceleration of the blood column in the axial direction during systole, followed by a gentle deceleration throughout diastole. The subsequent systolic-diastolic complex does not start from the zero line, but rather is registered on the end-diastolic flow to ensure constant tissue oxygenation throughout the cardiac cycle. An increase in resistance, leading to a representation of flow reversal in the diastolic phase, is indicative of organ pathology and is often caused by congestion phenomena that affect all parenchymal tissue (such as transplant rejection, torsion and compartment syndrome). The detection of "tardus et parvus" arterial flow in parenchymal tissue typically indicates pathology in the afferent arterial vessel, such as arterial stenosis or complete thrombosis with inadequate collateral branch compensation. Post-traumatic intraparenchymal arterial vessel turbulent flow may indicate an arteriovenous fistula, while a "to and fro" spectral pattern is more suggestive of a pseudoaneurysm.

Conclusions:

Correctly interpreting the arterial spectral tracing at PWD-US in the parenchyma allows for an indirect and quantitative measurement in both traumatic and non-traumatic emergencies.

References

Diagnostic ultrasonography for peripheral vascular emergencies. Thomas Cook

ULTRASOUND DIAGNOSIS OF GASTROESOPHAGEAL REFLUX DISEASE

Elene Khmaladze¹

1. Tbilisi State University Clinic Vivamed

Abstract body

Gastrointestinal ultrasonography has existed in the world medical practice more than 35 years ago. The first works on this subject date back to the 1978-79 years. Now GIUS is gaining strength in many countries.

Objectives

- 1) primary detecting of gastroesophageal reflux
- 2) value of method in availability for the broad masses of population in condition technical capabilities of equipment, even using the portable scanner
- 3) advantages of method:
 - non-invasiveness in comparison with endoscopy
 - absence of radiation in comparison with X-ray and CT
 - budget method in comparison with CT, MRI and PET

Methods

Ultrasonography of cardioesophageal zone with peroral water contrasting with three probes positions

- 1) epigastric position
 - 2) right subcostal position
 - 3) left subcostal position
- patient's position on the back
 - patient's position on the right side

Results

Patients groups classification patients groups according to ultrasonic symptoms:

- 1) slight gastroesophageal reflux with cardia insufficiency with hiatal ring dilatation of 16-18 mm (video)
- 2) medium reflux with unfixed hiatal hernia dilatation over 18 mm (video)
- 3) strong reflux with unfixed and fixed hiatal hernia dilatation over 25 mm (video)

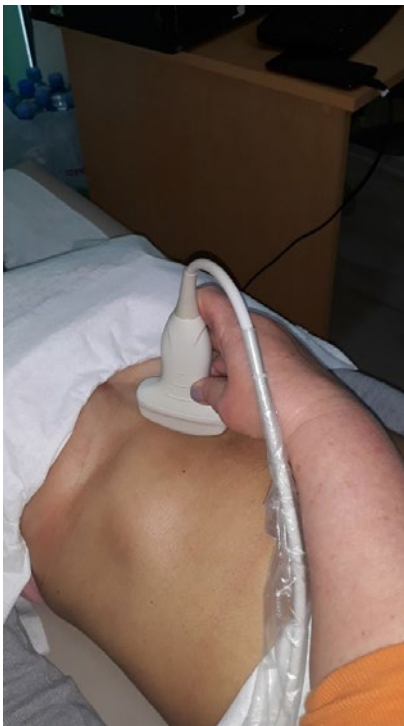Conclusions

- 1) GIUS is a valuable, informative, non-invasive, non-radiating, budget technique for the primary detection of gastroesophageal reflux
- 2) GIUS can be used in screening of gastroesophageal reflux disease even in the early stages
- 3) GIUS of cardioesophageal zone deserves close attention and active using by US specialists in every day practice

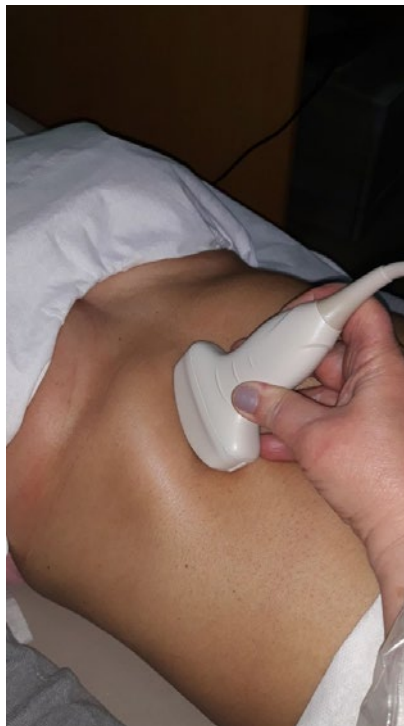References

Symptomatic gastroesophageal reflux: diagnosis with ultrasound

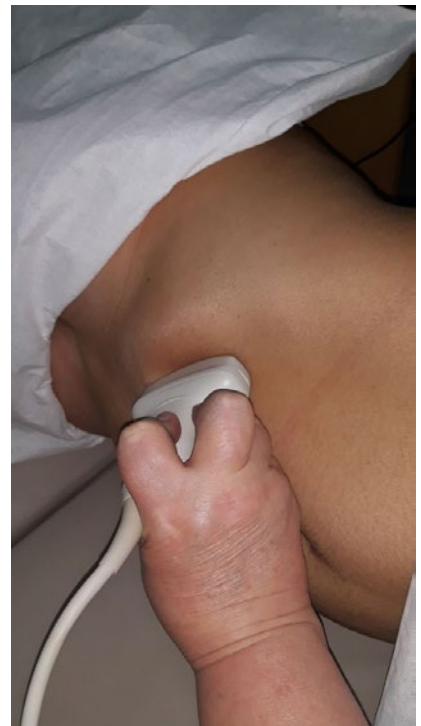
S J Westra 1, H H Derkx, J A Taminiau



Epigastric probe's position.



Right subcostal probe's position.



Left subcostal probe's position.

ADVANCED 3D TRANSRECTAL ULTRASOUND FOR EVALUATION OF PERIANAL FISTULAS, TUMORS AND ANAL SPHINCTERS

Nerijus Teresius¹, Raminta Luksaite - Lukste¹, Tomas Poskus¹

1. Vilnius University Hospital Santaros Clinics

Abstract body

Learning objectives:

To illustrate the usefulness of 3D anorectal endosonography (EUS) in evaluating perianal fistulas, anal or low rectal tumors and visualizing anal sphincter atrophy in fecal incontinence.

Background:

Fecal incontinence, perianal fistulas has a profound impact in a patient's life, impairing its quality and carrying economic burden due to health costs [1]. Colorectal cancer is the most common gastrointestinal malignancy and the second most common cause of cancer-related deaths in Western countries.

Findings and procedure details:

We use bkSpecto Ultrasound System with 20R3 transducer. Inside its head, two-crystal assembly can rotate to give a 360° field of view, creating very high 3D image resolution. No moving parts contact human tissue and the need of altering transducers position inside the body is also minimized. Afterwards BK3D Viewer application is used for evaluation of images. Images can be reviewed later, making EUS technique less operator dependent.

In anal or low rectal cancers, EUS helps to accurately assess T staging. This is especially true for T1 and T2 tumours.

In fistulas, EUS can visualize anal sphincter defects and inner opening of fistulas into anal canal. H2O2 can be applied during examination since it enhances visualization of fistula tracts in ultrasound image.

Anal sphincter tears or atrophy is also readily made with EUS, since it has comparable results to magnetic resonance imaging.

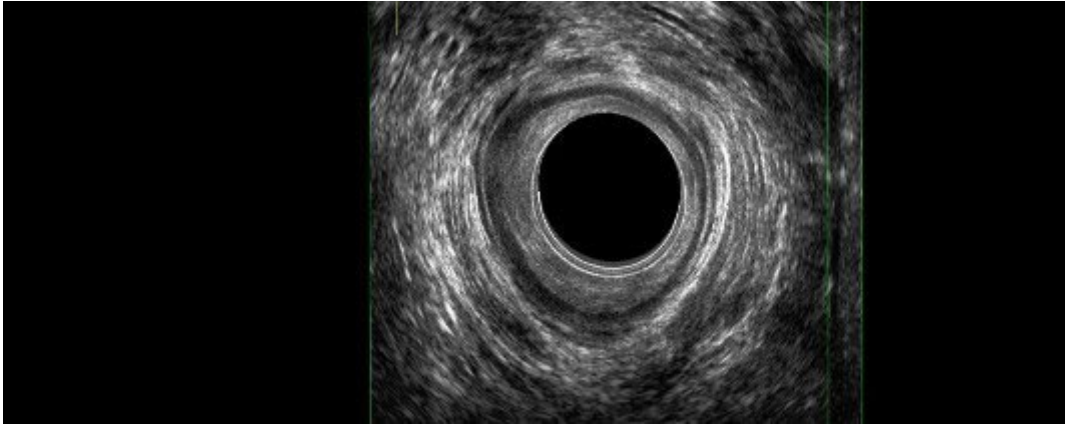
Conclusions:

EUS is reliable tool to visualize subtle fistulas, small (T1-T2) anal or low rectal tumors, as well as anal sphincter atrophy / defects.

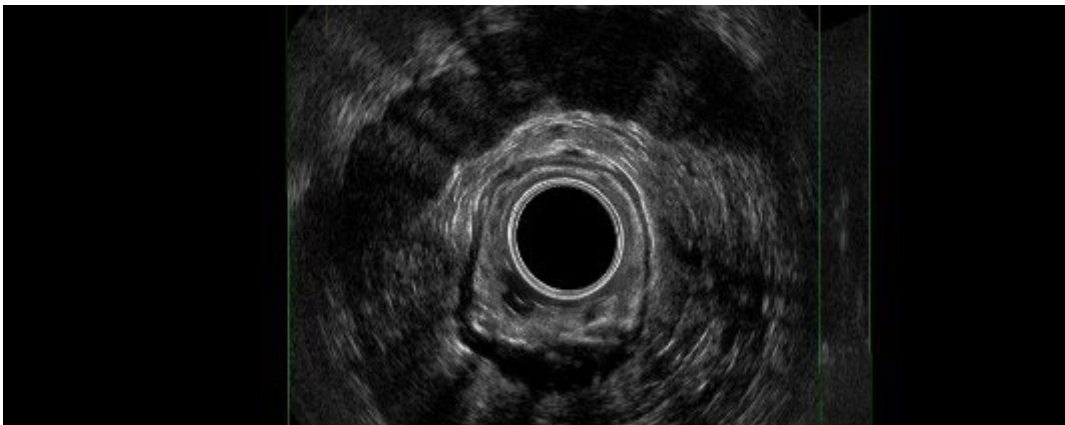
References

Will be announced in presentation.

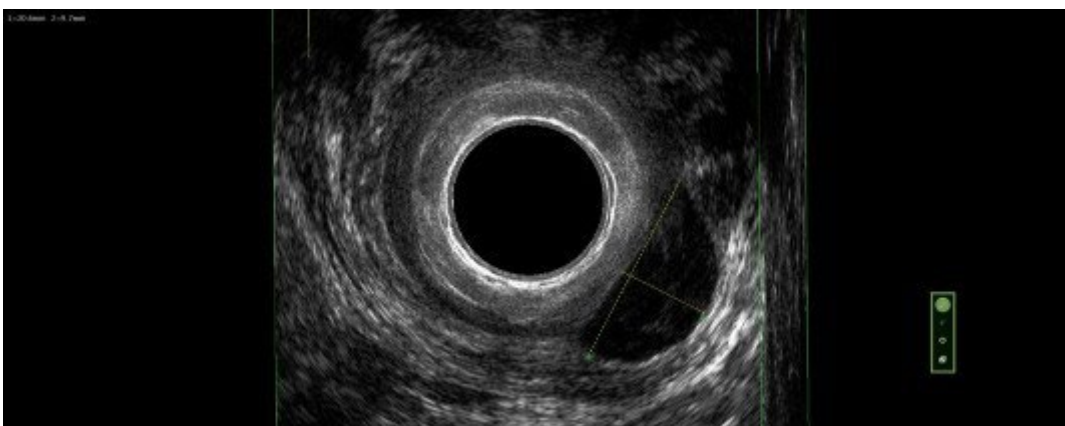
ADVANCED 3D TRANSRECTAL ULTRASOUND FOR EVALUATION OF PERIANAL FISTULAS, TUMORS AND ANAL SPHINCTERS



Irregular atrophy / thinning of internal anal sphincter.



Fistula tract at 7 o'clock, enhanced with H2O2.



Perianal tumour at 3-5 o'clock.

CONTRAST-ENHANCED ULTRASOUND COMPARED WITH ENDOSCOPY IN CROHN'S DISEASE

***Kim Nylund*¹, Odd Helge Gilja¹**

1. National Centre for Ultrasound in Gastroenterology, Haukeland University Hospital, Bergen, Norway

Abstract body

Actuality and aim:

Dynamic contrast-enhanced ultrasound (DCE-US) was used for assessing perfusion in Crohn's disease (CD), but there is less experience with Sonazoid. The aim was to examine if DCE-US with Sonazoid was feasible in patients with active CD, if contrast-enhancement correlated with endoscopic activity and if DCE-US can differentiate mild from moderate/severe disease.

Material and methods:

48 patients with CD activity on ultrasound (Bowel wall thickness ≥ 3 mm) were included. A 90 sec cine loop was recorded after the injection of Sonazoid. DICOM video files were analyzed using Vuebox calibrated for a Logiq E10, C1-6 ultrasound probe. Data was scaled to high intensity spots within the bowel wall. Quality of fit over 70% was considered acceptable. Parameters derived from the time intensity curve were correlated with the SES-CD value for the examined bowel segment. Moderate/severe disease activity was defined as SES-CD ≥ 7 .

Results:

Three patients refused contrast examination. For the remaining, feasibility was 39/45 (87%). There was a negative correlation between SES-CD and Time to Peak (TTP) (-0.32 , $p=0.049$) and a positive correlation for Wash in Rate (WiR) (0.35 , $p=0.030$). 10/39 patients had moderate/severe activity and significantly higher PE ($p=0.016$) and WiR ($p=0.009$) and lower TTP ($p=0.032$).

Conclusions:

There is an association between local SES-CD and both temporal and amplitude-based parameters derived from the time intensity curve. Also, there is a significant difference in DCE-US between mild and moderate/severe disease activity.

References

None

ULTRASOUND SHEAR WAVE ELASTOGRAPHY BASED NON-INVASIVE DIAGNOSIS OF CHRONIC PANCREATITIS: A PROSPECTIVE COHORT FEASIBILITY

Carlo Felix Maria Jung¹, Cecilia Binda¹, Fabio Cortellini¹, Leonardo Solaini²,
Chiara Coluccio¹, Monica Sbrancia¹, Elisa Liverani¹, Carla Serra³, Carlo Fabbri¹

1. Gastroenterology and Digestive Endoscopy Unit, Forlì-Cesena Hospitals, AUSL Romagna, Forlì-Cesena, Italy, 2. Department of Medical and Surgical Sciences, University of Bologna, Forlì 40126, Italy, 3. Interventional, Diagnostic and Therapeutic Ultrasound Unit, Department of Medical and Surgical Sciences, IRCCS, Azienda Ospedaliero-Universitaria Sant'Orsola Malpighi Hospital, Bologna, Italy

Abstract body

Actuality and Aim

Diagnosis of chronic pancreatitis in early stages is difficult but necessary [1]. New generation ultrasound devices provide high-definition images and serve as first level diagnostic screening method [2]. Ultrasound (US) shear wave elastography and an ultrasound specific chronic pancreatitis (USCP) score have been recently proposed for the diagnosis of chronic pancreatitis [3, 4]. We compared pancreatic US- shear wave elastography (SWE) and the USCP score to the Rosemont EUS score.

Materials and Methods

From July to November 2022, 10 patients with (CP) and 11 patients without (NP) chronic pancreatitis according to Rosemont criteria were included. We obtained SWE and USCP scores and performed score correlations. A USCP score of 5 and a shear wave parameter of >1.4m/s were assumed for chronic pancreatitis. Exclusion criteria were patients <18 years old, pancreatic adenocarcinoma, reduced visibility of the pancreas.

Results

Median SWE in CP was 1.7m/s (IQR/med 16.9%) and 1.48 m/s (IQR/med 14.3%) in NP. Median USCP score in CP was 7 and 1.5 in NP. SWE significantly correlated with Rosemont criteria (OR 6.18, 1.34-2.84; p<0.05), Gemelli USCP score (OR 5.69, 0.87 -37.1; p=0.069) showed a trend towards significance.

Conclusions

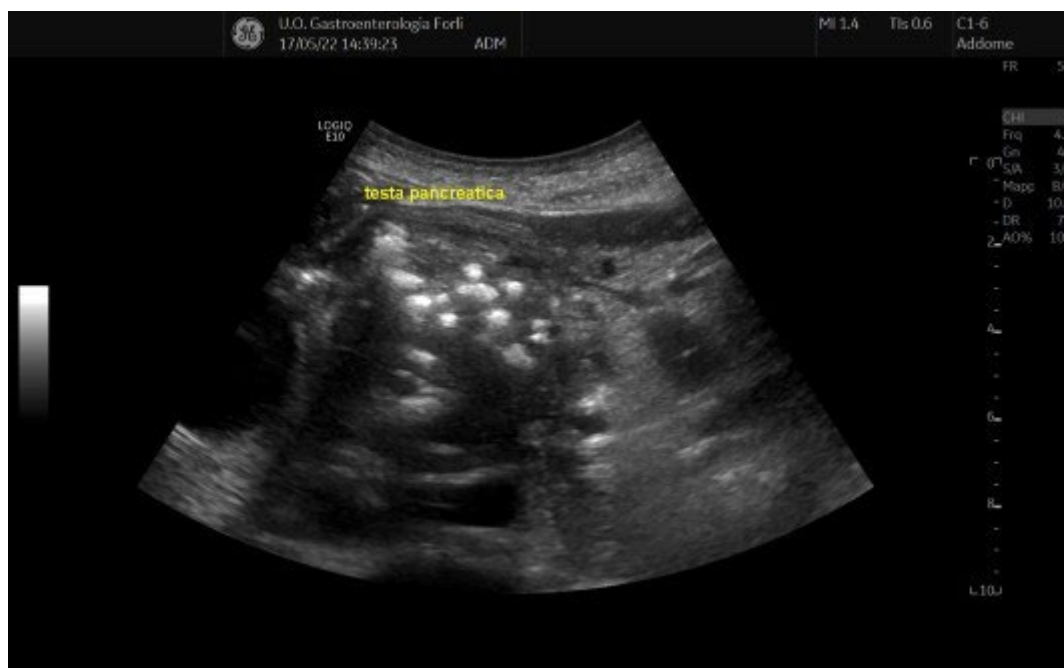SWE represents a minimally invasive tool to diagnose chronic pancreatitis. Larger studies are needed to confirm these preliminary data.

Acknowledgements

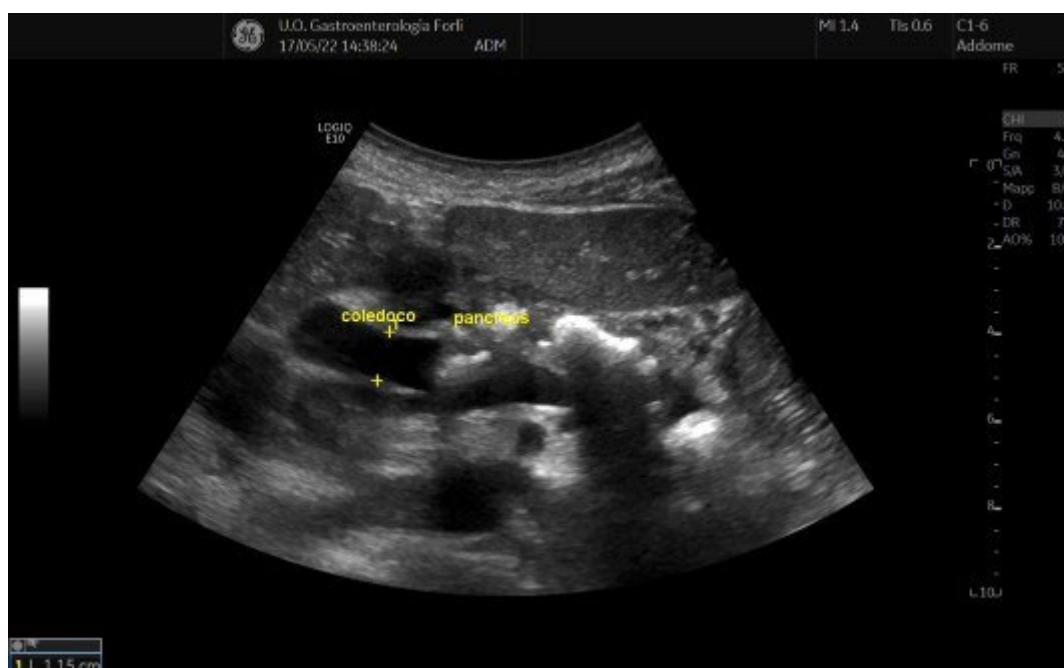References

1. Beyer G et al, Lancet 2020 396:499-512.
2. D'Aversa F et al, Ultrasound Med Biol 2022 48:685-693.
3. Săftoiu A et al, Ultraschall der Medizin 2019 40:425-453.
4. Pagliari D et al, Dig Liver Dis 2020 52:644-650.

ULTRASOUND SHEAR WAVE ELASTOGRAPHY BASED NON-INVASIVE DIAGNOSIS OF CHRONIC PANCREATITIS: A PROSPECTIVE COHORT FEASIBILITY



Pancreatic head with mass like effect including multiple calcifications.



Main bile duct dilation in chronic pancreatitis with calcification.

ULTRASOUND ASSESSMENT OF THE CHOLECYSTOLITHOTOMY EFFECT ON THE STRUCTURAL AND FUNCTIONAL PROPERTIES OF THE GALLBLADDER

***Oleksandr Babii*¹, *Oleh Dynnyk*², *Borys Shevchenko*³**

1. Department of Surgery of digestive organs, SI "Institute of gastroenterology of NAMS of Ukraine", Dnipro.,
2. "Institute of elastography" Medical center LLC, Kyiv, Ukraine, 3. Department of Surgery of
Digestive organs, SI "Institute of gastroenterology of NAMS of Ukraine", Dnipro

Abstract body

Actuality. Recently, there is a tendency to perform organ-saving surgery, including on the gallbladder (GB) in gallstones (GS).

Aim. Ultrasound assessment of the cholecystolithotomy (CHLT) effect on the structural and functional GB properties.

Methods. 38 patients with uncomplicated GS before and 4-6 years after laparo-endoscopic CHLT were studied by ultrasound: men - 10 (26.3%), women - 28 (73.7%), age 21-70 (36.2 ± 4.6) years. The GB structure was evaluated: volume, wall thickness, deformation and number, size, mobility of GS. Evaluation of the contractile function of the GB: the initial volume (V1) of the GB was measured in fasting and for 1, 3, 5, 7, 10, 15, 20, 30, 40, 50, 60 minutes after the cholekinetic. By the volume of maximum contraction (V2) of GB, the efficiency of bile secretion (EBS) was calculated: $EBS = V1 - V2 / V1 * 100\%$.

Results. Before surgery, the GB volume was 22.5-36.6 (29.9 ± 1.4) ml. GB deformations were determined in 24 (63.2%) cases. Movable GS were from one to 60 in size 5-36 and sludge - 9 (23.7%). EBS was 32.3-68.6 (46.7 ± 2.1)%.

In the remote period after CHLT EBS did not change significantly - (48.5 ± 2.4)%, ($p > 0.05$). In 17 (44.7%) cases, there was a decrease in wall thickness from 3.1-4.2 (3.6 ± 0.1) mm to 2.0-3.4 (2.6 ± 0.2) mm, ($p < 0.05$). The GS recurrence rate was - 3 (7.8%), and sludge - 8 (21.1%).

Conclusions. Performance of CHLT allows the preservation of a functioning GB with a low frequency of recurrence of GS.

References

Organ-saving laparo-endoscopic operations on the gallbladder. Babii A.M., Shevchenko B.F. Surg Endosc (2018): P287; P.158

ULTRASOUND FEATURES OF HELICOBACTER PYLORI RELATED GASTRITIS

***Fulvia Terracciano*¹, Antonella Marra², Veronica Nassisi³, Rosa Valvano², Fabrizio Bossa², Sonia Carparelli², Francesco Cocomazzi², Antonio Massimo Ippolito², Rossella Cubisino², Giovanni Squatrito³, Francesco Perri²**

1. IRCCS CASA SOLLIEVO DELLA SOFFERENZA, 2. IRCCS Casa Sollievo della Sofferenza,

3. Department of Clinical and Experimental Medicine, Messina

Abstract body

ACTUALITY AND AIM

Abdominal ultrasound (US) is effective in the visualization of gastric wall layers and measuring its thickness. The aim of this study is to evaluate the US features of H. Pylori gastritis and to study its predictive value in detecting this disease.

METHODS

One hundred patients were subjected to gastroscopy with biopsy according to clinical indication and to abdominal US for assessing the antral wall thickness (AWT), submucosal wall thickness (SLT), mucosa wall thickness (MLT), gastric motility and presence of ingests. They were divided into 2 groups according to the presence of the H. Pylori: group A (H. Pylori infection) and B (non-H. Pylori infection). We also identify a cut-off value of SLT using a receiver operating characteristic (ROC) curve.

RESULTS

The SLT and slowing gastric motility were significantly greater in H. Pylori gastritis group ($p < 0,001$). In multivariate analysis, only SLT was a significant independent predictor of H. Pylori gastritis (OR = 14.1, $p < 0,002$). The best threshold value of SLT to discriminate positive H. Pylori patients from negative was set at 1.55 mm, with a sensitivity of 76% and a specificity of 72%.

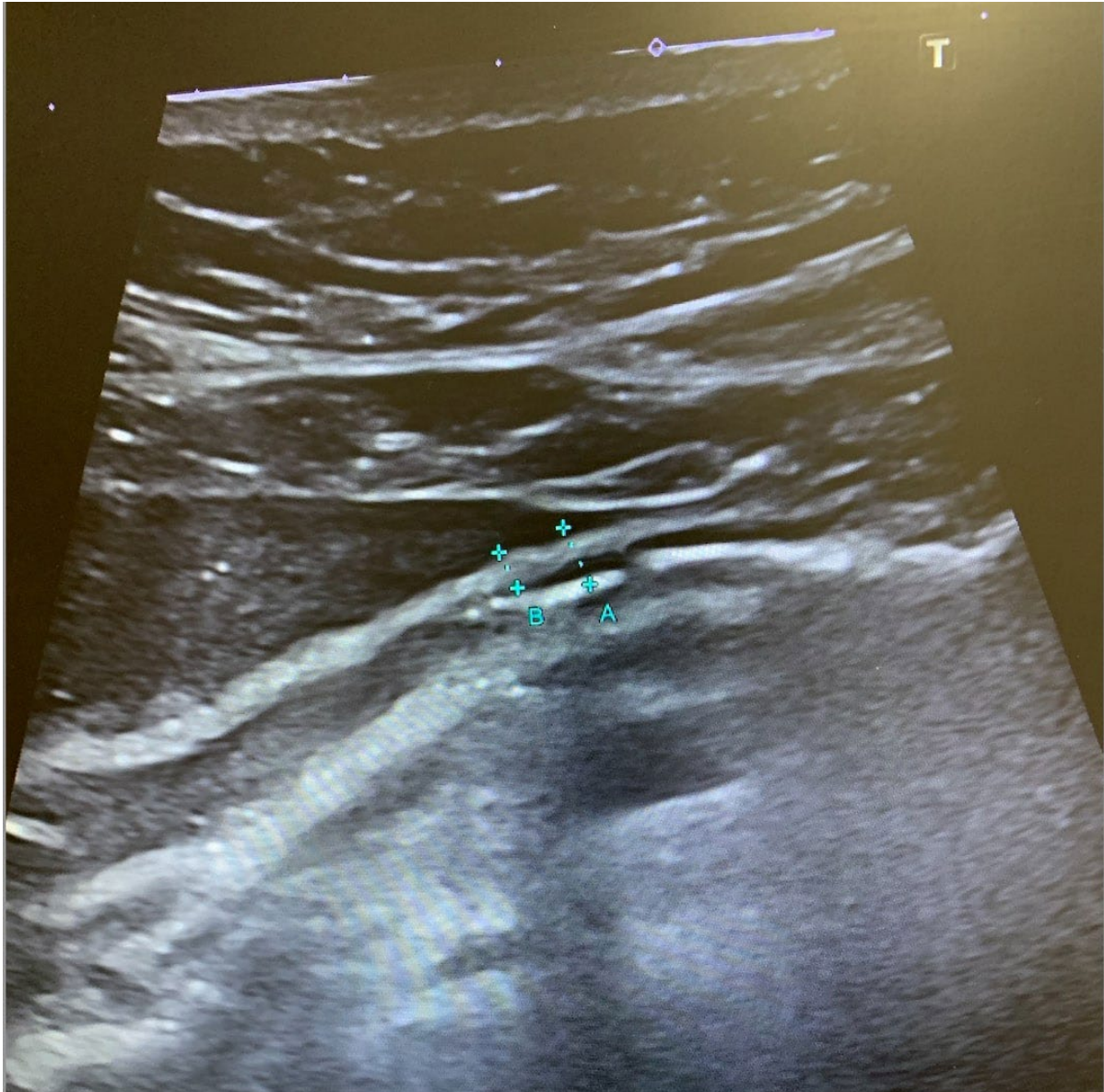
CONCLUSIONS

This study suggests that H. Pylori gastritis is associated with a thickening of the submucosal layer and a decreased of gastric motility. These gastric US features could help us in the diagnosis of H. Pylori gastritis and in detecting those patients who need further investigation.

References

1. Mascatello VJ, et al. The ultrasonic demonstration of gastric lesions. J Clin Ultrasound 1977; 5:383-387

ULTRASOUND FEATURES OF HELICOBACTER PYLORI RELATED GASTRITIS



ACUTE PATHOLOGY OF THE GALLBLADDER, ITS ULTRASOUND DIAGNOSIS AND THE MOST COMMON PITFALLS

Dovile Volodkoviciene¹

1. Vilnius University hospital Santaros Klinikos

Abstract body

Learning objectives: Describe the clinic of acute cholecystitis (AC), the value of laboratory and instrumental tests, diagnostic criteria and treatment tactics. Evaluate and discuss the most common anatomical, technical and diagnostic barriers to diagnostic accuracy.

Background: Acute cholecystitis is the fourth most common cause of hospital admission for acute abdominal syndrome. Traditionally, alongside laboratory tests, imaging tests are essential for a correct diagnosis. Ultrasonography is the first choice for the evaluation of patients with suspected AC. In the case of complicated ACHs, additional imaging tools such as CT or MRI/MRCP may be needed to assess the extent and complexity of lesions.

Results: Acute cholecystitis is usually classified into a complicated and uncomplicated. Uncomplicated disease is characterized by a stone in the gallbladder's neck or ductus cysticus, gallbladder hydrops and dilatation, ultrasound Murph sign. Additional signs: gallbladder wall thickening, sludge, wall and surrounding tissues hyperemia, inflammatory fat infiltration. Main ACs complications: perforation, abscess or fistula formation, Bouveret syndrome. The differential diagnosis includes appendicitis, biliary colic, cholangitis, mesenteric ischemia, ulcer perforation, gastritis. Some of the AC features alone can cause pitfalls in interpretation, thus in many cases imaging alone is not sufficient for accurate differentiation, patient's history and available laboratory data is required.

Conclusion: It's important to know not only the basic pathognomonic diagnostic features of the disease, but also to understand the possible concomitant pathologies and their ultrasound diagnosis, which determines the further treatment tactics.

Acknowledgements: Many thanks to Raminta Luksaite-Lukste for the help and support.

References

-

COULD VENOUS IMPEDANCE INDEX BE MORE HELPFUL THAN ARTERIAL RESISTIVE INDEX IN THE EVALUATION OF RENAL OBSTRUCTION? PRELIMINARY RESULTS

***Dalila De Lucia*¹, Marco Di Serafino², Dalila De Lucia¹, Francesca De Chiara³, Vito Cantisani⁴, Gianfranco Vallone¹**

1. Department of Medicine and Health Sciences "V. Tiberio" University of Molise, 2. Department of Medicine and Health Sciences "V. Tiberio" University of Molise; General and Emergency Radiology Department "A. Cardarelli" Hospital, Naples, 3. Department of Radiological Sciences Univ. Sapienza, Rome, 4. Department of Radiological Sciences Univ. Sapienza, Rome I

Abstract body

ACTUALITY AND AIM

We aimed to determine the accuracy of interlobar renal venous pulsed-wave Doppler (PWD) ultrasound (US) impedance index (II) in patients with acute renal colic to diagnose acute obstructive uropathy compared to interlobar arterial PWD-US resistive index (RI) study as the standard method.

MATERIAL AND METHODS

We recruited 25 adult patients with unilateral acute renal pain and US evidence of stone obstruction. 25 healthy patients were randomly selected as control group. US-B-mode imaging was first performed for a morphological evaluation of kidneys (size, shape, echotexture), pelvicalyceal system and bladder. PWD-US study was performed, measuring II and RI respectively in the interlobar veins (II) and interlobar arteries (RI) of the affected kidney, compared with the values of the contralateral healthy kidney. The venous II and arterial RI were calculated from the peak systolic velocity (PSV) and end diastolic velocity (EDV) using the formula: $(PSV - EDV) / PSV$.

RESULTS

In the affected kidney, RI was increased and the II decreased compared to the undamaged side. The extent of the variation of II was more significant than the variation of RI.

CONCLUSIONS

Evaluation of the II can be clinically effective in cases of ultrasound diagnostic doubt for acute urinary obstruction since the change in venous flow is more pronounced in these patients.

References

- 1) Diagnostic value of renal resistive index for the assessment of renal colic. Kavakli
- 2) Role of resistive index in renal colic. Onur 2007
- 3) Doppler sonographic evaluation of resistive index of intra-renal arteries in acute ureteric obstruction. Maheswaran 2021

EVALUATION OF INTRA- AND INTEROBSERVER VARIABILITY ATTENUATION COEFFICIENT MEASUREMENT (ACM) FOR THE ASSESSMENT OF HEPATIC STEATOSIS

Maksym Zhaivoronok¹, Oleh Dynnyk², Olexandr Livkutnyk³, Viktoriia Yerokhovych⁴, Violetta Yuzvenko⁵, Iryna Serednia⁴, Yelizaveta Melnychenko⁴, Nazarii Kobyliak⁴

1. Department of Nuclear Medicine, Radiation Oncology and Radiation Safety of Shupyk National Healthcare University of Ukraine, Kyiv, Ukraine, 2. "Institute of elastography" Medical center LLC, Kyiv, Ukraine, 3. Kyiv City Clinical Endocrinology Center, 4. Endocrinology Department, Bogomolets National Medical University, Kyiv, Ukraine, 5. Ukrainian Scientific and Practical Center for Endocrine Surgery, Transplantation of Endocrine Organs and Tissues of the Ministry of Health of Ukraine

Abstract body

Actuality. Evaluation of the ultrasound attenuation coefficient is widely used in the diagnosis of hepatic steatosis.

Aim is evaluation of intra- and inter-observer variability ACM for the assessment of hepatic steatosis.

Methods. 26 patients (9 men and 17 women), average age 53.2 ± 4.73 years with a diagnosis of liver steatosis, were examined. B-mode and ACM were performed on US systems Soneus P7, (Ultrasign, Ukraine).

Examinations were performed by 2 radiologists with 28 (expert 1) and 17 (expert 2) years of experience and 4 general practitioners (GPs) without US experience (operators 1-4).

The training of 4 GPs on mastering the ACM was only 60 minutes due to US steatophantom. Each doctor performed 5 measurements of the ACM for each patient.

Results. Intraobserver variability was: intraclass correlation coefficient (ICC) for operator 1 - 0,918 (95% CI 0,754-0,990); for operator 2 - 0,885 (95% CI 0,673-0,985); operator 1 - 0,746 (95% CI 0,443-0,951), operator 2 - 0,765 (95% CI 0,473-0,956), operator 3 - 0,737 (95% CI 0,429-0,949), operator 4 - 0,768 (95% CI 0,477-0,956);

Interobserver variability was: between experts 1 and 2 - 0,754 (95% CI 0,522-0,883); between non- experts overall - 0,685 (95% CI 0,521-0,823).

Conclusion. Assessment of hepatic steatosis using ACM for the experts is very easy and accuracy. A short training of GPs on US steatophantom allows to quickly and quite accurately perform the ACM.

References

Strauss S, Gavish E, Gottlieb P, Katsnelson L. Interobserver and intraobserver variability in the sonographic assessment of fatty liver. AJR 2007; 189: W320-W323.

FOCAL LIVER OBSERVATIONS NOT VISUALIZED ON GRAYSCALE ULTRASOUND PRIOR TO PERFORMING CEUS: ANALYSIS FROM A PROSPECTIVE MULTICENTER TRIAL

Corinne Wessner¹, Corinne Wessner², Rachel Blackman², Yuko Kono³,
Stephanie Wilson⁴, Alexandra Medellin⁴, Shuchi Rodgers², Aya Kamaya⁵,
Lisa Finch⁶, David Fetzer⁷, Fabio Piscaglia⁸

1. Thomas Jefferson University Hospital, Philadelphia PA, 2. Thomas Jefferson University Hospital, Philadelphia PA, United States, 3. University of California, San Diego, San Diego CA, United States, 4. University of Calgary, Calgary, Canada, 5. Stanford University, Stanford CA, United States, 6. Swedish Medical Center, Seattle WA, United States, 7. UT Southwestern Medical Center, Dallas, TX, United States, 8. University of Bologna, Bologna, Italy

Abstract body

Actuality and aim:

To analyze the ability of contrast-enhanced ultrasound (CEUS) to characterize focal liver observations detected by CT or MRI but not visible on pre-contrast ultrasound.

Methods:

Patients at risk for hepatocellular carcinoma (HCC) with focal liver observations on CT/MRI and inadequate visualization on ultrasound underwent CEUS with an intravascular agent (Lumason/SonoVue, Bracco Diagnostics) as part of a prospective multicenter trial. Liver observations were classified using CEUS LI-RADS. Tissue histology, CT/MRI findings at the time of CEUS or imaging follow-up were used as reference standard.

Results:

Of the 616 subjects a total of 20 patients (15 male and 5 female; mean age 64 ± 28 years) had focal liver observations detected by CT or MRI but not visible on pre-contrast ultrasound. Eleven (55%) CEUS examinations were deemed inadequate (4 HCC, 2 benign, 4 indeterminate on follow-up and 1 liver metastases). Among the 9 remaining lesions (5 HCC, 2 indeterminate on follow-up and 1 cholangiocarcinoma), 6 (30%) cases were characterized as indeterminate (1 LR-2, 1 LR-3, 4 LR-4), 2 (10%) cases were classified as LR-M on CEUS. Only 1 (5%) case was characterized as definite HCC (LR-5).

Conclusion:

These preliminary results demonstrate the importance of visualization of focal liver observations on ultrasound prior to a CEUS examination. Among the 20 lesions present on CT/MRI and not visible on ultrasound, 1/9 HCC can be characterized correctly on CEUS as LR-5.

Acknowledgements:

Study support: NIH RO1 CA215520; Bracco Diagnostics.

References

- 1) ACR Contrast-Enhanced Ultrasound Liver Reporting & Data System.
<https://www.acr.org/-/media/ACR/Files/RADS/LI-RADS/CEUS-LI-RADS-2017-Core.pdf>.

TERMINOLOGY OF MULTIPARAMETRIC ULTRASOUND (MP-US) OF CHRONIC DIFFUSE LIVER DISEASES (CDLD)

***Oleh Dynnyk*¹, *Oleksandr Fedusenko*², *Maksym Zhaivoronok*³, *Nazarii Kobylia*⁴
*, Svitlana Zakrevska*¹, *Iryna Oraevska*¹**

1. "Institute of elastography" Medical center LLC, Kyiv, Ukraine, 2. "Doctor Lakhman" Medical center LLC, Zaporizhzhia, Ukraine, 3. Department of Nuclear Medicine, Radiation Oncology and Radiation Safety of Shupyk National Healthcare University of Ukraine, Kyiv, Ukraine, 4. Endocrinology Department, Bogomolets National Medical University, Kyiv, Ukraine

Abstract body

Actuality. CDLD (non-alcoholic fatty liver disease (NAFLD) and viral hepatitis (VH)) have a time continuum of gradual development fibrosis/cirrhosis and their complications (portal hypertension, HCC). Aim is to propose a terminology for the algorithm of the mp-US of CDLD. Methods. We summarized our own experience with US in CDLD from 2014 to 2022 in 23445 patients of both sexes aged 18 to 87 years. Until 1998, we used only the B-method, as a monoparametric approach. The appearance of Doppler has led to the combined use B-mode and Doppler - biparametric US. Since 2010, our team has been using shear wave elastography (B-mode, Doppler and 2D SWE) - three-parametric US). Since 2014, we constantly perform liver steatometry by the attenuation coefficient of the Ukrainian device Soneus P7 - a quadro-parametric mode. Focal liver lesions requires CEUS - penta-parametric US. The clinical implementation of viscosimetry in CDLD US will become hexa-parametric. Results. CDLD US may use a different number of US device parameters depending on clinical needs, operator skill and device properties. The range of US parameters (US continuum) should be used in accordance with the time continuum of the CDLD. Conclusions. Mp-US – use of the most optimal number of US equipment parameters for a comprehensive and most complete solution of a clinical diagnostic problem in the same patient during the same US examination by the same operator.

References

Dynnyk O, Fedusenko A, Kobylia N. Multiparametric ultrasound (mp-US) in the chronic diffuse liver disease diagnosis. ECR 2017; C-2865: 1-35. DOI: 10.1594/ecr2017/C-2865.

ASSESSMENT OF NEW ULTRASOUND-BASED METHODS FOR LIVER STEATOSIS QUANTIFICATION AS COMPARED TO CONTROLLED ATTENUATION PARAMETER

Alina Popescu¹, **Camelia Foncea**¹, **Renata Bende**¹, **Radu Cotrau**¹, **Adrian Burdan**¹, **Tudor Moga**¹, **Ariana Pascu**¹, **Maria Stan Voicu**¹, **Felix Bende**¹, **Roxana Sirli**¹, **Ioan Sporea**²

1. "Victor Babes" University of Medicine Timisoara. 2 Center for Advanced Hepatology Research of the Academy of Medical Sciences, Timisoara, 2. "Victor Babes" University of Medicine Timisoara

Abstract body

Actuality: Early detection and staging of liver steatosis is important for establishing prognosis of patients with fatty liver. The aim of this study was to evaluate two new quantitative ultrasound (QUS) parameters, TSI (tissue scatter-distribution imaging) and TAI (tissue attenuation imaging) for steatosis assessment, as compared to controlled attenuation parameter (CAP).

Material and methods: A prospective study was conducted in which liver steatosis was assessed in the same session by QUS (Samsung Medison RS85, CA1-7A probe) and CAP (FibroScan Compact M 530, M/XL probes) in 275 patients [59% (162) males, mean age 55.9±12.2 years]. Reliable measurements were defined for CAP as the median value of 10 measurements with IQR/M<0.3. For QUS, five consecutive measurements of TAI and TSI were acquired by a color-coded map overlaid on B-mode ultrasound. TAI and TSI were automatically calculated and considered reliable when reliability index, R²>0.6. The CAP cut-off value to identify the presence of at least mild steatosis was 248 dB/m.

Results: Reliable measurements were obtained in 100% of cases both by CAP and TAI/TSI. Moderate correlations were observed between TSI vs. CAP $r=0.56$, and TSI vs. TAI, $r=0.49$. The best cut-off values to identify at least mild steatosis were: for TAI>0.73 (AUROC=0.87, $p<0.0001$, Se=67.6%, Sp=95.1%, PPV=96.9%, NPV=56.1%), for TSI>96.5 (AUROC=0.84, $p<0.0001$, Se=76.9%, Sp=82.9%, PPV=91.1%, NPV=61.3%).

Conclusion: TAI and TSI are feasible methods for assessing liver steatosis, with good accuracy to diagnose at least mild steatosis.

References

Karlas T, Petroff D, Sasso M, et al. Individual patient data meta-analysis of controlled attenuation parameter (CAP) technology for assessing steatosis. J Hepatol. 2017 May;66(5):1022-1030. doi: 10.1016/j.jhep.2016.12.022.

LIVER STEATOMETRY: POSSIBILITIES OF IMPLEMENTATION FOR PATIENTS WITH GALLSTONE DISEASE.

Olga Pushkarenko¹, **Olesya Horlenko**¹, **Vasyl Kaliy**¹, **Olena Debreceni**¹,
Viktor Pushkarenko¹

1. Uzhhorod National University

Abstract body

Liver steatometry is an ultrasound quantitative method of assessing the degree of fat content in the liver. In the study, an attempt was made to analyze the possibilities of the method after cholecystectomy.

30 patients were examined using laboratory methods, steatometry, and elastography using Soneus P7, Ultrason (Ukraine).

All patients of the study group with GD were diagnosed with liver steatosis of various degrees of severity: 1st stage of steatosis, 2.25 \pm 0.01 dB/cm - 10 people (33.3%), II stage, 2.7 \pm 0.02 dB/cm - 14 people (46.7%), III stage, 3.2 \pm 0.01 dB/cm - 6 people (20%).

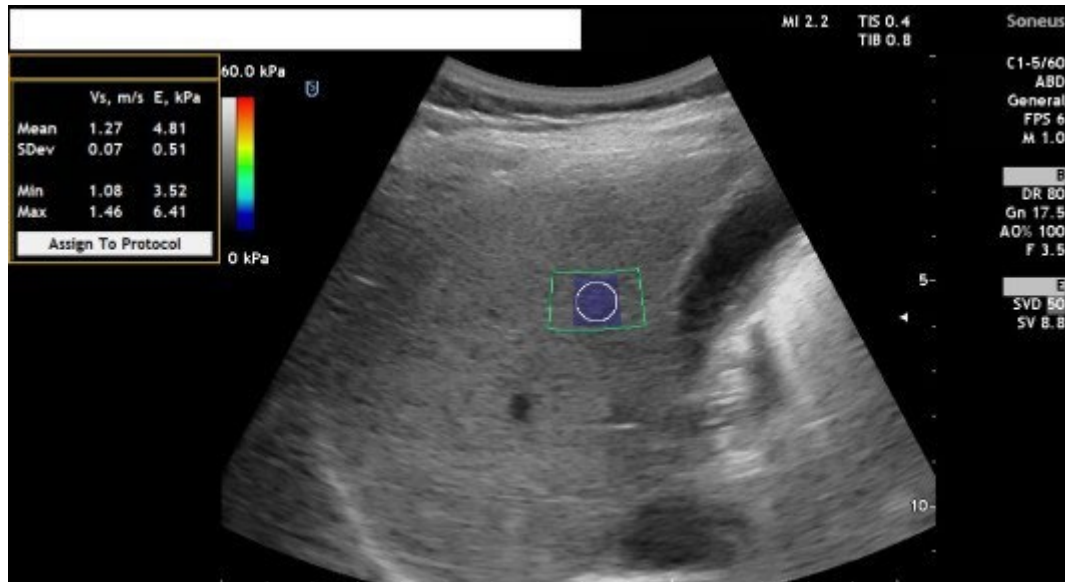
Among the studied contingent were patients with overweight and obesity (76.7%), type 2 diabetes (13.3%), cardiovascular diseases (26.7%), depression/eating disorders (40%), disturbed biochemical parameters of the liver (23.3%) and blood lipids (80%). No significant difference was found between preoperative steatometry data and data after 3 months. However, after 6 months, some patients (40% of them) who followed the recommendations for diet, physical activity and took ursodeoxycholic acid have shown a significant improvement in their condition with a direct correlation of such data as a decrease in body weight, normalization of laboratory parameters and a decrease in the level of the attenuation coefficient (AC, $r=1.0$).

Steatometry and the determination of the attenuation coefficient make it possible to assess the state of the liver after cholecystectomy in order to control the effectiveness of postoperative treatment and compliance on the part of the patient.

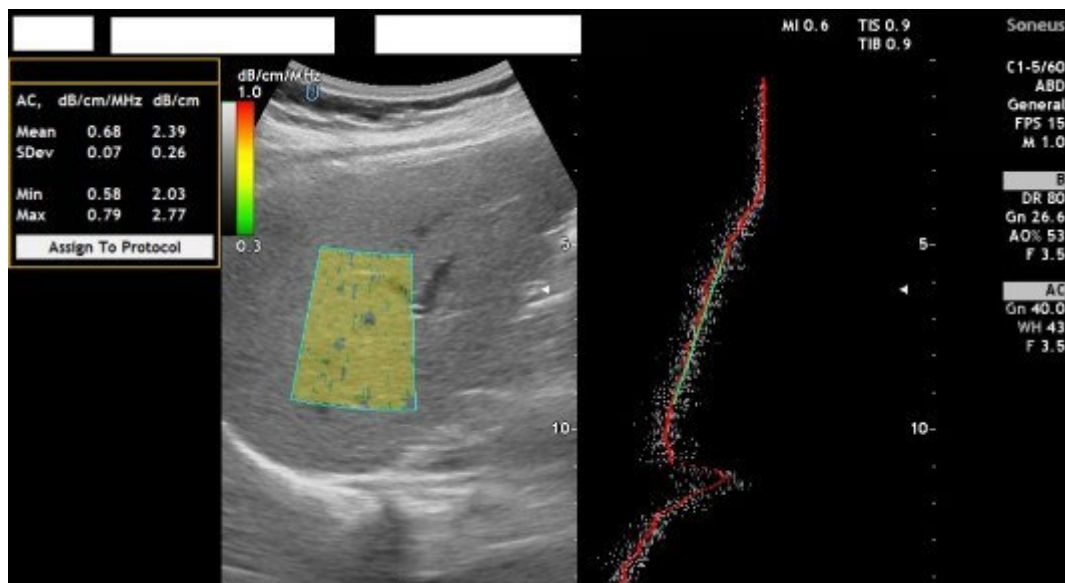
References

1. DOI: 10.2957/kanzo.59.194
2. http://www.irbis-nbuv.gov.ua/cgi-bin/irbis_nbuv/cgiirbis_64.exe?I21DBN=LINK&P21DBN=UJRN&Z21ID=&S21REF=10&S21CNR=20&S21STN=1&S21FMT=ASP_meta&C21COM=S&2_S21P03=FILE=&2_S21STR=PraktLik_2014_3_23
3. <http://www.mif-ua.com/archive/article/46067>
4. <http://www.mif-ua.com/archive/article/47280>

LIVER STEATOMETRY: POSSIBILITIES OF IMPLEMENTATION FOR PATIENTS WITH GALLSTONE DISEASE.



Elastography - Soneus P7, Ultrason (Ukraine).



Steatometry - Soneus P7, Ultrason (Ukraine).

CLINICAL VALIDATION OF CEUS LI-RADS IN PROSPECTIVE MULTI-CENTER STUDY

***Andrej Lyshchik*¹, Yuko Kono², Stephanie Wilson³, Alexandra Medellin³, Shuchi Rodgers¹, Victoria Planz⁴, Aya Kamaya⁵, David Fetzer⁶, Annalisa Berzigotti⁷, Paul Sidhu⁸, Fabio Piscaglia⁹**

1. Thomas Jefferson University Hospital, 2. University of California, San Diego, 3. University of Calgary, 4. Vanderbilt University Medical Center, 5. Stanford University, 6. UT Southwestern Medical Center, Dallas, 7. University of Bern, 8. King's College Hospital, 9. University of Bologna

Abstract body

The AIM of this prospective multi-center study was to determine diagnostic accuracy of LR-5 category ("Definitely HCC") and to show the incidence of malignancy within each of the algorithm's categories.

Methods

A total of 688 nodules in 606 patients at risk for HCC were included in this prospective international study conducted at 11 centers (eight in North America; three in Europe). Definite HCC diagnosis on MRI, imaging follow-up, or histology for MRI-indeterminate observations were used as reference standard.

Results

Of 688 nodules, 553 (80%) had confirmed diagnosis while 135 (20%) did not achieve final diagnosis. Of 553 confirmed nodules, 407 were HCC (73.5%), 30 (5.4%) other malignancy, and 116 (21.0%) non-malignant. A total of 263 confirmed observations were characterized as CEUS LR-5, 255 of them were HCC (97.0%). The sensitivity of LR-5 for HCC was 62.7% (95% CI 58.0%-67.4%); specificity 95.2% (95% CI 91.7% - 98.7%); Positive Predictive Value 97.3% (95% CI 95.4% - 99.3%); Negative Predictive Value 47.8% (95% CI 42.0% - 53.5%).

All 37 LR-1 and LR-2 observations were benign. 94.4% LR-M observations (51/54), 37.5% (34/92) of LR-3 observations, and 85.6% (89/104) of LR-4 observations were malignant.

Conclusions

The CEUS LR-5 classification is 95.2% specific for HCC, confirming high clinical value of CEUS for noninvasive HCC diagnosis.

Clinical Relevance

CEUS LI-RADS algorithm performs as expected, with increasing incidence of malignancy with higher LR categories, achieving very high specificity for HCC similar to CT and MRI, allowing for management decisions without the need for biopsy.

References

CEUS LI-RADS v2017

<https://www.acr.org/-/media/ACR/Files/RADS/LI-RADS/CEUS-LI-RADS-2017-Core.pdf>

FATTY LIVER QUANTIFICATION USING ULTRASOUND DERIVED FAT FRACTION (UDFF) AS COMPARED TO CONTROLLED ATTENUATION PARAMETER

**Sporea Ioan¹, Lupusoru Raluca¹, Sirli Roxana¹, Bende Felix¹, Cotrau Radu¹,
Foncea Camelia¹, Popescu Alina¹**

1. Department of Gastroenterology and Hepatology Victor Babes Timisoara

Abstract body

Aim: The aim of this study was to assess the performance and optimal cut-off points of UDFF for the non-invasive assessment of liver steatosis, using transient elastography (TE) with CAP as a reference method.

Material and methods: We included 271 consecutive patients, with or without chronic liver disease (43.7% female, mean age 53.3 ± 13.05 years). Liver steatosis was evaluated in the same session by 2 techniques: UDFF - using a Siemens ACUSON Sequoia system and by CAP – using a FibroScan Compact M 530 device. The following CAP cut-off values were used: 248 dB/m for mild steatosis (S1), 268 dB/m for moderate steatosis (S2) and 280 dB/m for severe steatosis (S3) [1].

Results: The correlation between UDFF and CAP was good, $r=0.75$, $p<0.0001$. We calculated the following UDFF optimal cut-off values to differentiate among steatosis grades: for S1 - $>5\%$ [(with 88.4% Se, 77.5% Sp, AUC of 0.92, $p<0.0001$]; for S2 $>10\%$ [(with 69.3% Se, 99% Sp, AUC of 0.95, $p<0.0001$]; and for S3 $>15\%$ [(with 46.9% Se, 100% Sp, AUC of 0.93, $p<0.0001$].

Conclusion: UDFF is a good method for classifying steatosis severity with the following cut-offs: $> 5\%$ for mild steatosis, $> 10\%$ for moderate steatosis and $> 15\%$ for severe steatosis, the specificity increasing with steatosis severity.

References

1. Karlas T, Petroff D, Sasso M, et al. Individual patient data meta-analysis of controlled attenuation parameter (CAP) technology for assessing steatosis. J Hepatol. 2017 May;66(5):1022-1030. doi: 10.1016/j.jhep.2016.12.022. Epub 2016 Dec 28. PMID: 28039099.

THORACIC ULTRASOUND IN NEONATAL RESPIRATORY PATHOLOGIES – A CHALLENGING TECHNIQUE

**Stoicescu Emil Robert¹, Iacob Roxana¹, Manolescu Diana Luminita¹,
Iacob Emil Radu², Oancea Cristian³, Iacob Daniela⁴**

1. Discipline of Radiology and Medical Imaging, "Victor Babes" University of Medicine and Pharmacy Timisoara,
2. Department of Pediatric Surgery, 'Victor Babes' University of Medicine and Pharmacy Timisoara,
3. Department of Pulmonology, 'Victor Babes' University of Medicine and Pharmacy Timisoara,
4. Department of Neonatology, 'Victor Babes' University of Medicine and Pharmacy Timisoara

Abstract body

Actuality and Aim: Nowadays, thoracic ultrasound is used as a non-invasive and radiation-free method of exploring respiratory pathologies, particularly in newborns. This study aims to prove the efficiency of this method in the management of newborns' respiratory pathologies, avoiding cumulative doses of radiation.

Material and Methods: The study includes 52 neonates with respiratory pathologies, 24 of them with SARS-CoV2 infection. The ultrasonography machines used for evaluation were equipped with the linear transducer as well as the microconvex one. The lung severity was evaluated using an ultrasound score covering twelve areas of thoracic interest – Lung UltraSound Score (LUSS).

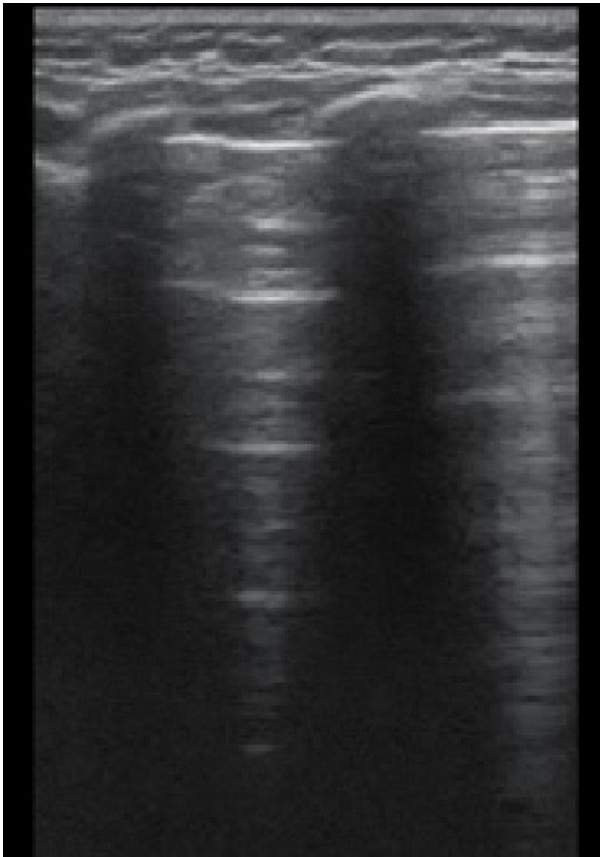
Results: The ultrasonographic assessments identify the disappearance of physiological A-lines (92.30%), sparse B-lines (80.76%), coalescent B-lines (46.15%), abnormalities of the pleural lines – thickening, fragmentation, irregularity (61.53%), subpleural consolidation (32.69%), and a small percent of pleural fluid collection. A correlation between the ultrasound score obtained and patient symptoms or biological markers was performed with Pearson's correlation coefficient $r = 0.792$ ($p = 0.03$) between the LUSS and the number of leukocytes at symptomatic neonates (with fever and cough), since $r = -0.812$ ($p = 0.0001$) between the LUSS and O2 saturation level.

Conclusions: Thoracic ultrasonography can be used in the follow-up of patients with respiratory pathology, helping in neonate management of pulmonary ones, based on LUSS.

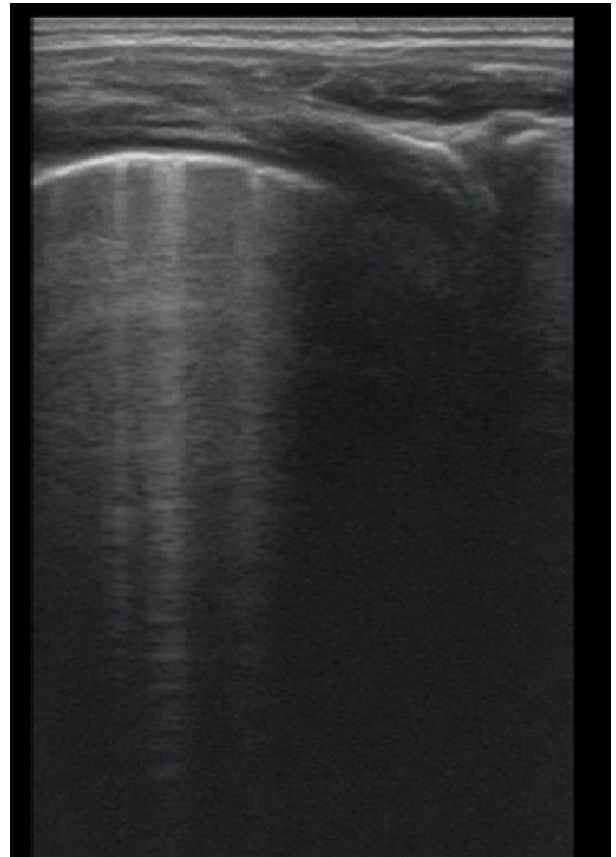References

Stoicescu, Emil Robert et al. "The Assessment of COVID-19 Pneumonia in Neonates: Observed by Lung Ultrasound Technique and Correlated with Biomarkers and Symptoms." *Journal of clinical medicine* vol. 11,12 3555. 20 Jun. 2022, doi:10.3390/jcm11123555

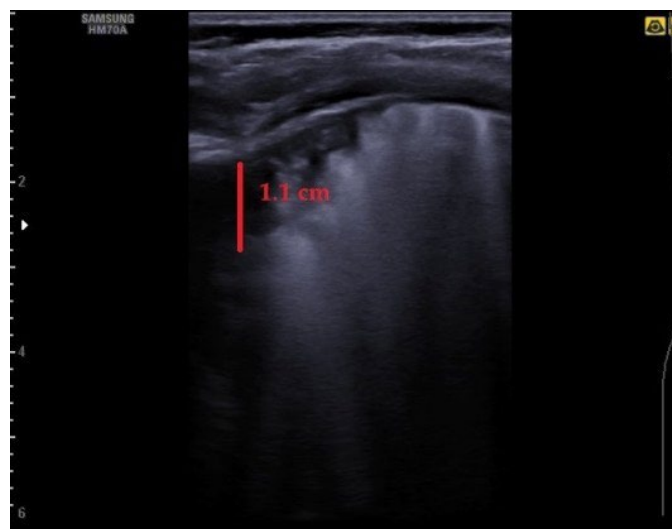
THORACIC ULTRASOUND IN NEONATAL RESPIRATORY PATHOLOGIES – A CHALLENGING TECHNIQUE



Normal aspect of the lung ultrasound in newborns.



The ultrasound shows sparse B-lines and confluent ones.



The ultrasound shows subpleural consolidation > 1 cm.

ULTRASOUND DIFFERENTIAL DIAGNOSIS OF BONE LESIONS IN CHILDREN

Paweł Walisiewicz¹, Andrzej Pomiećko¹

1. University Medical Center in Gdańsk

Abstract body

Actuality and Aim

Bone neoplastic lesions in children may present with non-specific symptoms, such as non-specific pain or general symptoms. Initially, the diagnosis focuses on exclusion of more frequent pathologies. When more obvious features appear, e.g. tumors or pathological fractures, other diagnostic imaging is performed. The aim of study is to determine the role of ultrasound in detection and differentiation of bone lesions in children.

Material and Methods

The authors analyzed the available literature about ultrasonography of bone tumors in children. They also used their own experience by 17 patients with bone lesions hospitalized at the Department of Pediatrics, Hematology and Oncology of the University Clinical Hospital in Gdańsk in 2019-2022.

Results

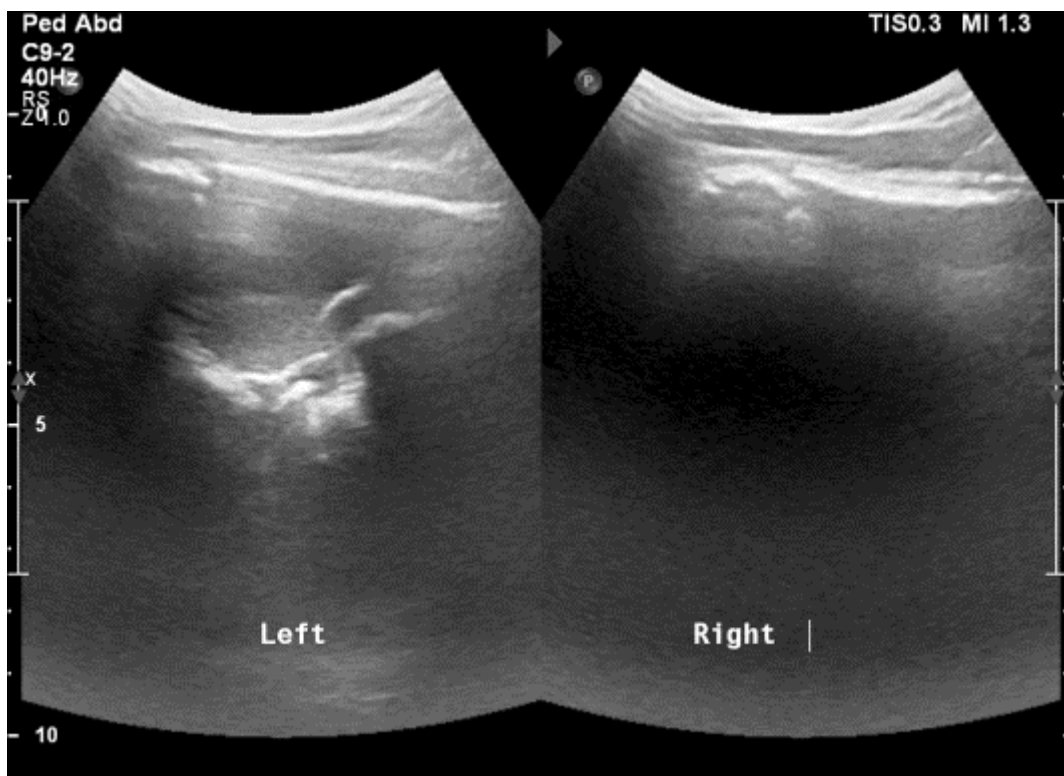
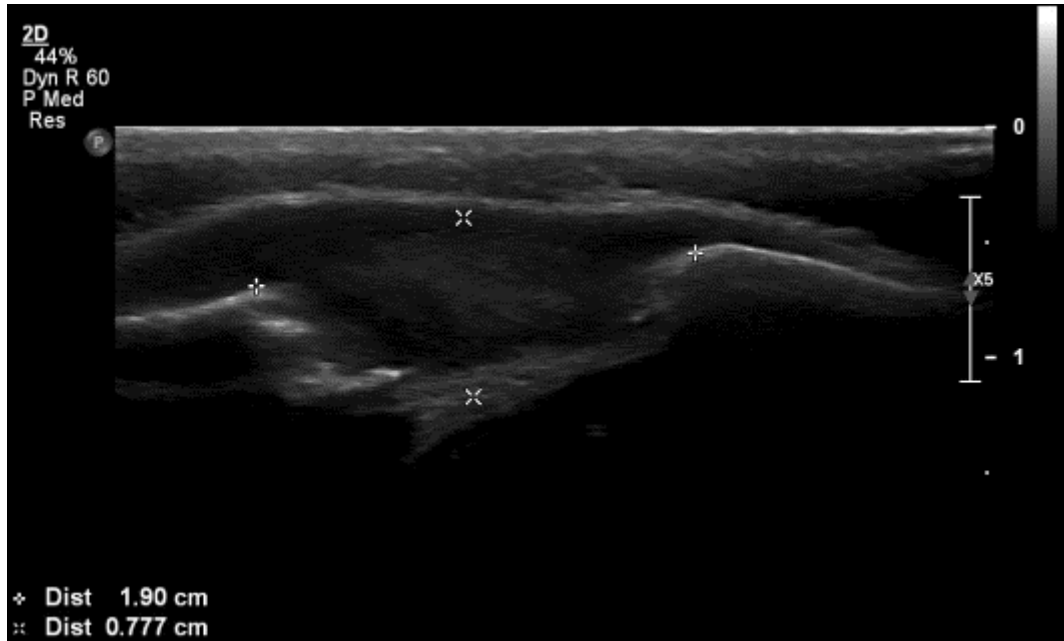Although ultrasound doesn't penetrate into the bone, it can reveal many lesions in the bones. The common feature of these lesions is the destruction of the periosteal line. Features suggesting malignant nature may include expansion into soft tissues, bone destruction, separation of the periosteum, rich vascularity and irregular borders of the lesion. Some tumors have very specific sonomorphology, which allows for a quick initial diagnosis.

Conclusions

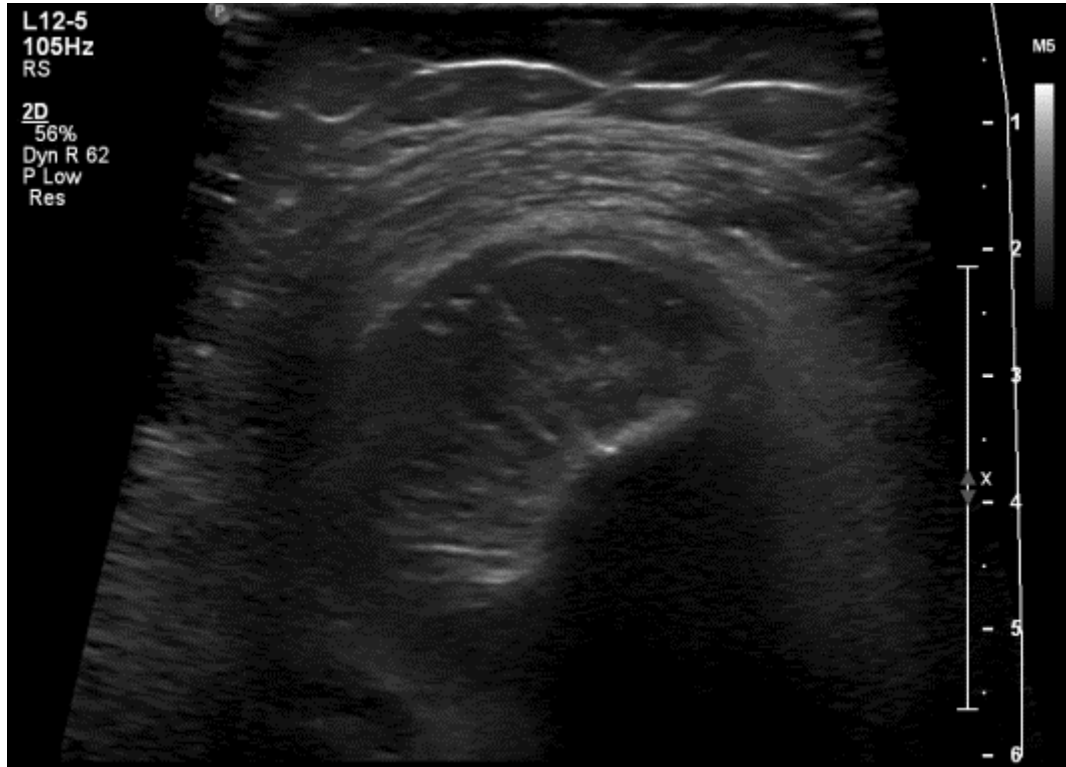Ultrasonography is a useful method for detecting bone lesions, and their differentiation between benign and malignant ones. Its use at the beginning of diagnostics can speed up detection, faster histopathological examination and faster treatment, improving the patient's prognosis. Soft tissue ultrasonography should be used routinely in the initial diagnosis of atypical symptoms that may suggest bone neoplasm. It can also be used to monitor the healing process of these lesions.

References

ULTRASOUND DIFFERENTIAL DIAGNOSIS OF BONE LESIONS IN CHILDREN



ULTRASOUND DIFFERENTIAL DIAGNOSIS OF BONE LESIONS IN CHILDREN



ACCESSORY KIDNEY ARTERY AS A CAUSE OF EXTRINSIC URETERO-PELVIC JUNCTION OBSTRUCTION (UPJO) IN CHILDREN WITH HYDRONEPHROSIS

**Anna Moczulska¹, Joanna Bieniek¹, Katarzyna Zachwieja¹,
Monika Miklaszewska¹, Dorota Drożdż¹**

1. Jagiellonian University Medical College, Dpt. of Pediatric Nephrology and Hypertension, Krakow

Abstract body

Accessory renal arteries are routinely considered to be normal anatomical variant.

The aim of the study was to analyze lower pole renal vessel, subpelvically crossing the ureter, as a cause of extrinsic uretero-pelvic junction stenosis (UPJO) in children with hydronephrosis.

Material and Methods

Group of 77 children diagnosed with UPJO was involved into the study, median age 29 (4-108) months; 50 males (65%).

Color doppler ultrasound (CD-US) of renal arteries was performed in 44 patients (57%) using Aloka Prosound alpha6, convex transducer 2-6 MHz. Diuretic renography was used to determine renal function.

Results

In CD-US 16 from 44 patients (36,4%) were found with accessory vessel crossing (CV) the ureter subpelvically, causing UPJO, median age 108,5 (69-159) months; 11 males.

In this CV -group first diagnosis of hydronephrosis was set at the age of 105 (31-162); 8 children complained of abdominal pain (50%). There were 5/16 early divisions of renal artery, 11/16 accessory renal artery to the lower pole.

Children without crossing vessel were significantly younger, median age 10 (4-89,5) months, with earlier diagnosis of hydronephrosis, at median age of 6 months (0-111); 4/28 children (14%) presented with abdominal pain.

There was no difference in diuretic renography between children with or without crossing vessel.

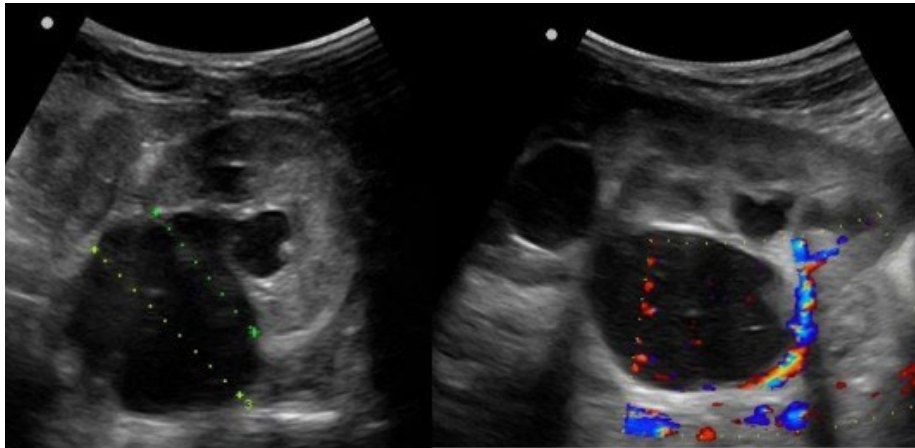
Conclusions

Extrinsic UPJO was found in 36,4% of examined patients. In older children the incidence of extrinsic UPJO was higher. CD-US is a useful and sensitive method to detect crossing vessel in UPJO, and should be considered as the investigation of choice in children with hydronephrosis.

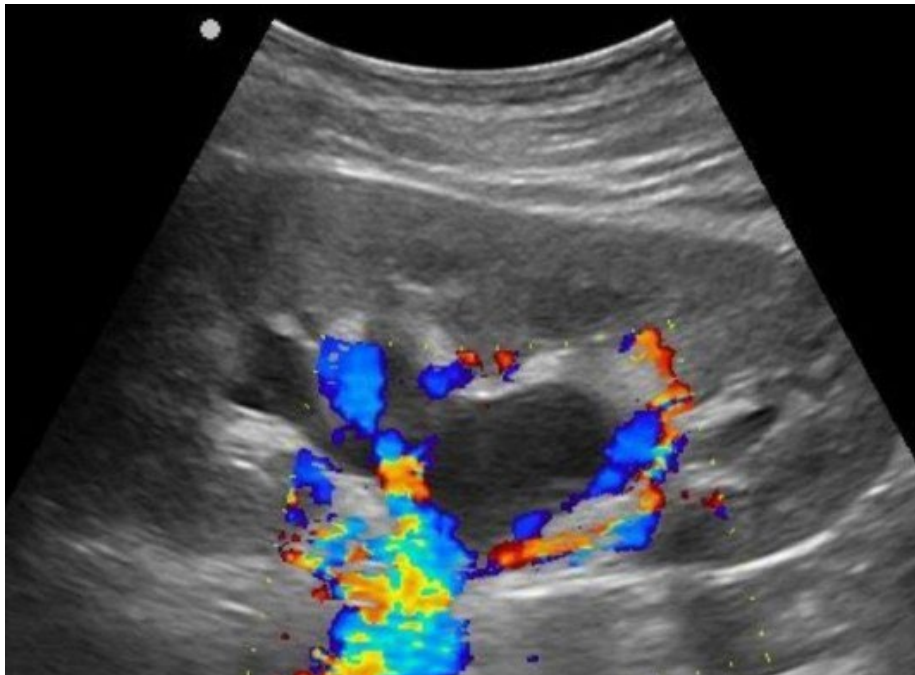
References

-

ACCESSORY KIDNEY ARTERY AS A CAUSE OF EXTRINSIC URETERO-PELVIC JUNCTION OBSTUCTION (UPJO) IN CHILDREN WITH HYDRONEPHROSIS

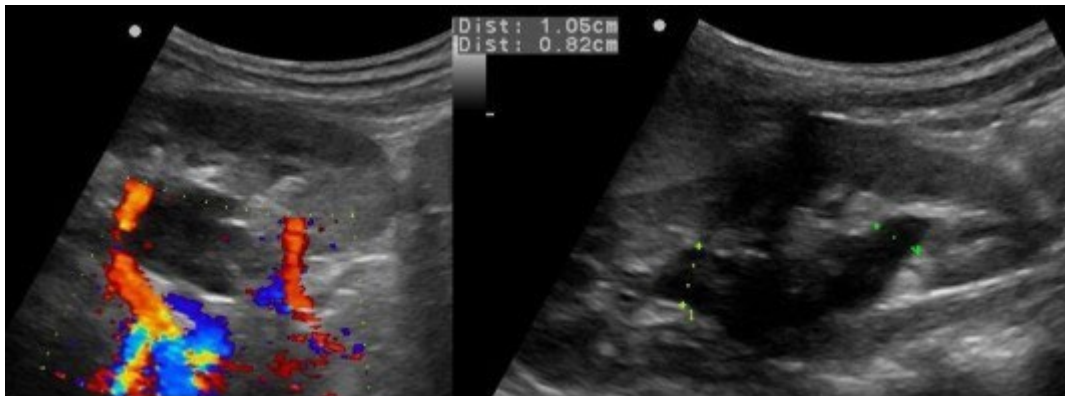


Boy9y. hydronephrosis, early division of renal artery crossing the ureter.



Girl with UPJO, early division CV to lower kidney pole.

ACCESSORY KIDNEY ARTERY AS A CAUSE OF EXTRINSIC URETERO-PELVIC JUNCTION OBSTUCTION (UPJO) IN CHILDREN WITH HYDRONEPHROSIS.



Boy7y. Accessory renal artery to lower kidney pole crossing ureter.

QUANTITATIVE ULTRASOUND FATTY LIVER EVALUATION IN A PEDIATRIC POPULATION: COMPARISON WITH MAGNETIC RESONANCE

***Pacini Patrizia*¹, Polti Giorgia², Dolcetti Vincenzo², Del Gaudio Giovanni², Poggiogalle Eleonora², Lucarelli Giuseppe², Cantisani Vito²**

1. Policlinico Umberto I, Sapienza-University of Rome,

2. Policlinico Umberto I- Sapienza, University of Rome

Abstract body

Actuality and Aim

The present study aims to assess liver steatosis in pediatric population comparing B-mode ultrasound, Hepato-Renal Index with Automated ROI Recommendation(EzHRI),Tissue Attenuation Imaging(TAI)and Tissue Scatter distribution Imaging(TSI)using Magnetic Resonance imaging proton density fat fraction(MRI-PDFF)as the reference standard.In addition,interobserver variability between two operators the variability is investigated.

Material and Methods

38 patients(18 males and 20 females,in a range of 8-17 years,average BMI 27.5)underwent MRI,B-mode,EzHRI,TAI,and TSI.MRI was acquired using a 3T magnet and two different techniques were used:3D T2* with Dixon pulse multiple-echo sequence(IDEAL IQ; MR-PDFF) and MR spectroscopy.

Results

Of the 38 patients recruited in the study,MRI identified a PDFF value $\geq 5.6\%$ in 23 patients. No significant superiority over B-mode ultrasound was found for all three methods.The cut-off values guaranteeing the best ratio of sensitivity and specificity in the pediatric population were TAI > 0.62(Db/cm/MHz);TSI > 92;EzHRI > 1.2. The results show no substantial difference between QUS and MRI for steatosis assessment;the inter-rater reliability of QUS techniques,which was good-to-excellent for EzHRI and TAI,and moderate-to-good for TSI.

Conclusions

Our results show acceptable reliability for QUS methods;furthermore,we propose novel cut-off values for EzHRI,TAI,TSI using MRI-PDFF as the reference method to identify the presence of pediatric hepatic steatosis.

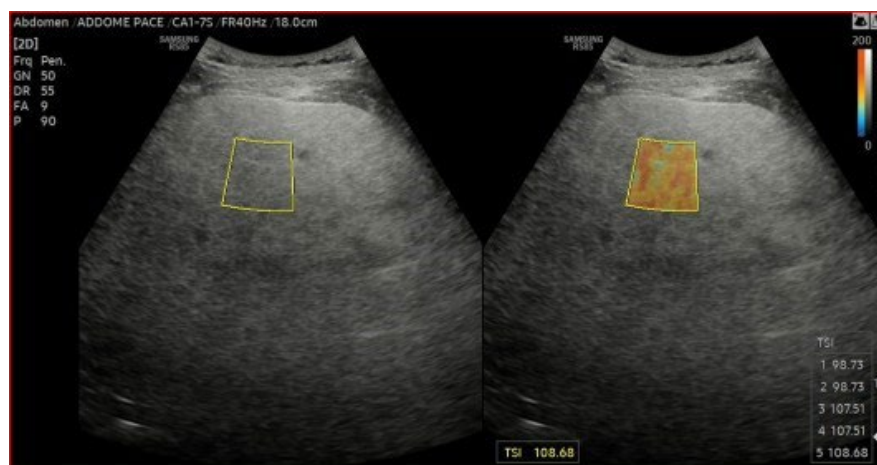
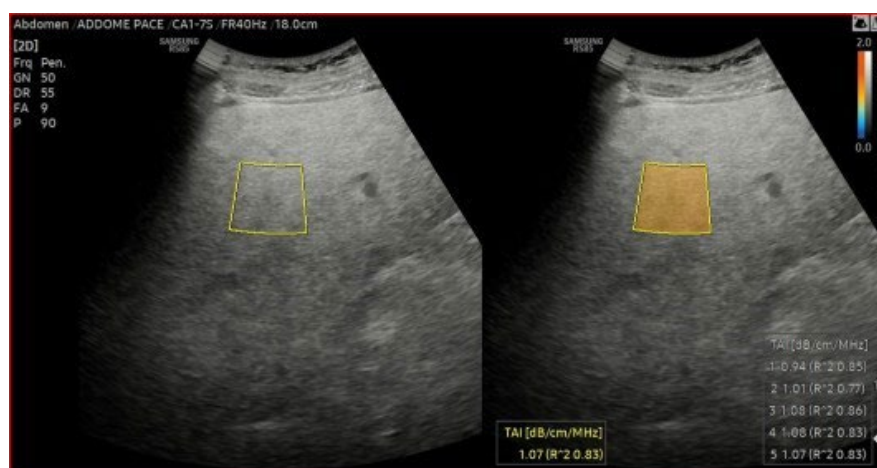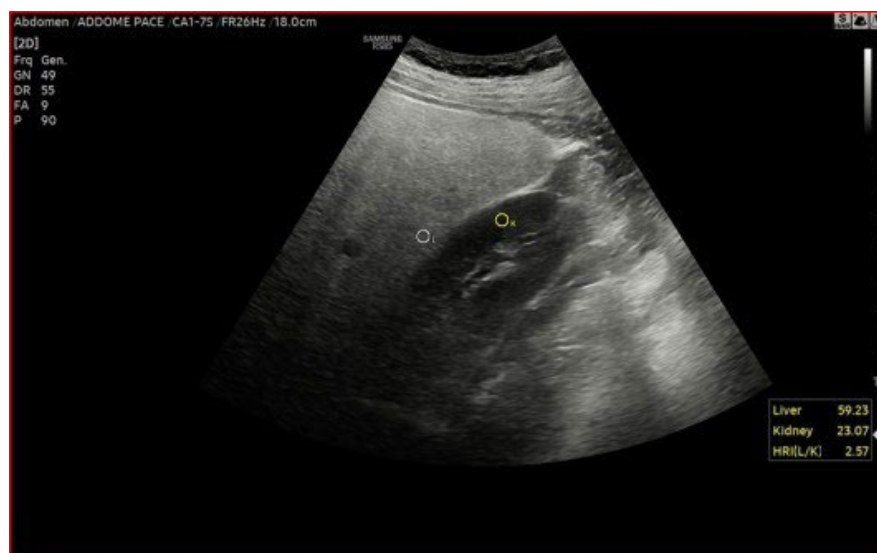Acknowledgments

n/d

References

Ferraioli G et al.- Quantification of Liver Fat Content with Ultrasound: A WFUMB Position Paper. Ultrasound Med Biol. 2021

QUANTITATIVE ULTRASOUND FATTY LIVER EVALUATION IN A PEDIATRIC POPULATION: COMPARISON WITH MAGNETIC RESONANCE



DIAGNOSTIC SUCCESS OF ACR TI-RADS AND SOLID PROTRUDING COMPONENT IN PARTIALLY CYSTIC THYROID NODULES

Serkan Guneyli¹, **Adnan Kabaalioglu**², **Hakan Dogan**², **Eren Coskun**²,
Omer Tarik Esengur³, **Hur Hassoy**⁴, **Barbaros Erhan Cil**², **Bulent Colakoglu**⁵,
Serdar Tezelman⁶, **Orhan Agcaoglu**⁶

1. Department of Radiology, Bakircay University School of Medicine, 2. Department of Radiology, Koc University School of Medicine, 3. Koc University School of Medicine, 4. Department of Public Health, Ege University School of Medicine, 5. Department of Radiology, American Hospital, 6. Department of General Surgery, Koc University School of Medicine

Abstract body

Aim We aimed to investigate the diagnostic success of American College of Radiology (ACR) Thyroid Imaging Reporting and Data System (TI-RADS) and solid protruding component in partially cystic thyroid nodules (PCTNs) and evaluate interobserver agreement.

Materials and Methods In all, 179 patients (F/M: 128/51, median age: 43 years, range: 69, min: 13, max: 82), who had PCTNs (n=187) on ultrasound and underwent surgery or fine-needle aspiration (FNA) between January 2014 and October 2020 were included in this retrospective study. Two academic radiologists scored the nodules based on ACR TI-RADS. Fourteen parameters including age, gender, composition, echogenicity, shape, margin, echogenic foci, TIRADS score and category, FNA recommendation based on category, sonographic appearance suspicious for Hashimoto's thyroiditis, solid, vascular, and calcific protruding components were correlated with histologic/cytologic results using Mann-Whitney U and chi-square tests.

Results There were 144 benign and 43 malignant nodules. Age ($p=0.043$), composition ($p=0.004$), echogenicity ($p=0.003$), echogenic foci ($p=0.015$), score ($p=0.005$), FNA recommendation ($p=0.021$), and solid protruding component ($p=0.013$) correlated with malignancy. In multivariate analysis, except for FNA recommendation, they remain significant. Sensitivity, specificity, PPV, NPV, and accuracy of TI-RADS were 58%, 65%, 33%, 84%, and 64%, respectively. There were poor interobserver agreement for echogenicity and shape.

Conclusions ACR TI-RADS has low diagnostic accuracy rates in PCTNs, and solid protruding component in PCTNs correlates with malignancy.

References

1. Grant EG, Tessler FN, Hoang JK, et al. Thyroid ultrasound reporting lexicon: white paper of the ACR Thyroid Imaging, Reporting and Data System (TIRADS) committee. J Am Coll Radiol 2015; 12:1272-1279.

CONTRAST-ENHANCED ULTRASOUND IN THE EVALUATION OF TI-RADS 3,4 AND 5 THYROID NODULES

***Mihaela-Maria Vlad*¹, Andreea Toma¹, Ioana Golu¹, Melania Balas¹, Daniela Amzar¹, Tudor Moga², Alina Popescu²**

1. Discipline of Endocrinology, "Victor Babes" University of Medicine and Pharmacy, Timisoara,

2. Discipline of Gastroenterology, "Victor Babes" University of Medicine and Pharmacy, Timisoara

Abstract body

Contrast-enhanced ultrasound (CEUS) started to be used for the visualization of microcirculation and the dynamic enhancing process of the thyroid nodules.

Aim: To evaluate the value of CEUS in differentiating malignant from benign, in selected thyroid nodules.

Patients and methods: We studied 11 cases, all females, with solid thyroid nodules detected by ultrasound (US) and classified as ACR-TIRADS 3,4 and 5. All the evaluations were done on a high-performance ultrasound machine (Aixplorer SuperSonic) using a linear high-resolution transducer. CEUS was performed with the same machine used for grayscale and Doppler US, using Sonovue as contrast-enhanced medium. In all the analyzed nodules we have the results of final pathology or the FNAB.

Results: All the thyroid nodules were solid, with the mean maximum diameter 20 ± 11 mm (range 7-48 mm). According to the ACR-TIRADS classification, there were 5 nodules ACR-TIRADS 3, 2 nodules ACR-TIRADS 4 and 4 nodules ACR-TIRADS 5. All the nodules presented internal vascularization on Doppler US. For CEUS evaluation of the nodules we analyzed the homogeneity, enhanced intensity in comparison with adjacent parenchyma, ring enhancement and border regularity, wash-in and wash-out of the contrast substance. The final pathology indicated malignancy in 4 cases (36%). Some specific aspects, like non-enhancement in solid nodules or hyperenhancement with late wash-out, were detected in malignant thyroid nodule.

Conclusion: CEUS is a new method for the evaluation of thyroid nodules, which must be integrated with other information to differentiate malignant from benign nodules.

References

Huang Y et al. Contrast-Enhanced Ultrasound Improves... Ultraschall in Med 2022; 43: 599-607

DIAGNOSTIC ACCURACY OF MULTIPARAMETRIC ULTRASOUND IN THE DIFFERENTIAL DIAGNOSIS OF PAROTID LESIONS COMPARED WITH MRI EXAMINATION

Vincenzo Dolcetti¹, Giovanni Del Gaudio¹, Patrizia Pacini¹, Carmen Solito¹, Chiara Di Bella¹, Maurizio Renda¹, Vito Cantisani¹

1. Università degli studi di Roma - La Sapienza

Abstract body

Actuality and Aim:

To evaluate the diagnostic accuracy of multiparametric ultrasound in the characterisation of the parotid gland formations, compared to MRI.

Material and Methods:

126 patients with parotid lesions were enrolled prospectively. The ultrasound evaluation was carried out by integrating B-mode ultrasound with eco-colour Doppler (CDUS), elastosonography with strain ratio (SE) and CEUS. All patients underwent FNAC or histological examination. In 60 patients who had performed pre-operative MRI, a further retrospective comparison was made with the results previously obtained from the ultrasound evaluation.

Results:

CDUS, SE and CEUS in differentiating between benign and malignant neoplasms showed a sensitivity value of 73%, 77% and 86%, and a specificity value of 78%, 80% and 97%. They showed diagnostic accuracy of 78%, 78% and 90%. The agreement with MRI was excellent ($k = 0.87$), in particular to CEUS performed on benign lesions. MRI showed diagnostic accuracy similar to multiparametric ultrasound (91%). SE [Strain Ratio (SR) > 3] revealed poor diagnostic accuracy (78%) due to the low SR values that characterise non-Hodgkin's lymphomas. In the differential diagnosis between pleomorphic adenoma and Warthin tumour, the SE (SR cut-off: 2.5) instead showed high sensitivity (93%) and good accuracy (85%). These limits are partially overcome by MRI.

Conclusions:

MPUS can represent a valid diagnostic integration and could sometimes be considered as an alternative to MRI in the evaluation of parotid lesions.

References

Sultan SR, AlKharaiji M, Rajab SH. Diagnosis of parotid gland tumours with Contrast-Enhanced Ultrasound: a systematic review and meta-analysis. Med Ultrason. 2022 May 25;24(2):211-218. doi: 10.11152/mu-3119.

ROLE OF US IN PREOPERATIVE PARATHYROID LOCALIZATION AND IN EVALUATING THYROID NODULES IN PATIENTS WITH PRIMARY HYPERPARATHYROIDISM

**Alper Özel¹, Özgül Ekmekcioglu², Nurcihan Aygün³, Eyüp Çamurcuoğlu⁴,
Selahattin Durmaz⁵, Adnan Batman⁶, Bahar Memiş⁷, Mehmet Uludağ³,
Yüksel Altuntaş⁸**

1. UHS Istanbul Sisli Hamidiye Etfal Health Research Center, Department of Radiology, 2. UHS Istanbul Sisli Hamidiye Etfal Health Research Center, Department of Nuclear Medicine, 3. UHS Istanbul Sisli Hamidiye Etfal Health Research Center, Department of General Surgery, 4. UHS Istanbul Sisli Hamidiye Etfal Health Research Center, Department of Radiology, 5. Istanbul Faculty of Medicine, Department of Radiology, 6. Koc University Faculty of Medicine, Department of Internal Medicine, 7. UHS Istanbul Sisli Hamidiye Etfal Health Research Center, Department of Pathology, 8. UHS Istanbul Sisli Hamidiye Etfal Health Research Center, Department of Internal Medicine

Abstract body

Actuality and Aim: To evaluate the role of ultrasonography (US) in parathyroid localization and further to assess concomitant thyroid nodules using a thyroid nodule risk stratification system (ACR-TIRADS) in patients with primary hyperparathyroidism (PHPT).

Material and Methods: 292 (248 female, 44 male) patients with PHPT who underwent parathyroid surgery or additional thyroid surgery with parathyroidectomy during between May 2014 and December 2022 constituted our study cohort. For preoperative parathyroid localization, US examinations in all patients and Sestamibi-scintigraphy in 280 of 292 patients were reviewed. Sensitivity and positive predictive values (PPV) were calculated for both US and SS, respectively. Nodules assigned to ACR-TIRADS levels were reviewed according to FNAB and/or surgical results or to follow up.

Results: The sensitivity and PPV were 84.5%, 99.5% and 76.7%, 96.4% for both US and SS, respectively. US found concomitant thyroid nodules in 161 patients (55.1%, 161/292), and 17 patients were confirmed to have malignancy based on surgical pathology results. 43.4% (70/161) of nodules were 10 mm or below in size. The frequency of nodules, as recommended for US follow-up or FNAB according to ACR-TIRADS, was 27.9% (45/161). 70.6% (12/17) of thyroid malignancies were papillary microcarcinomas. 4 of 5 malignant nodules (above 10 mm in size) detected on US, were in both ACR-TIRADS IV and V categories (1 ACR-TIRADS IV, and 3 ACR-TIRADS V).

Conclusions: US and SS are both useful methods in preoperative localization of parathyroid lesions. US further detects additional thyroid nodules, and ACR-TIRADS can be useful in identifying malignant ones.

References

Am Surg2002;88(2):254-259

MULTIMODAL ULTRASOUND DIAGNOSTIC IN HYPERTHYROIDISM CASES

STOIAN DANA¹, BORLEA Andreea², SPOREA Ioan³

1. Victor Babes University of Medicine and Pharmacy, Timisoara, 2. Victor Babes University of Medicine and Pharmacy Timisoara, Romania, 3. Victor Babes University of Medicine and Pharmacy, Timisoara, Romania

Abstract body

Introduction Even if Graves disease (GD) is the most frequent cause of hyperthyroidism, the number of aggression thyroiditis (DT) did increase. Currently, the golden standard of diagnostic is considered scintigraphy.

Prospective study of hyperthyroidism cases, starting March 2020-

Material – 73 aggression thyroiditis (64 subacute, 3 painless, 6 iatrogenic) and 87 GD.

Method - Multiparametric ultrasound evaluation – grey scale - exclusion of nodular goitre; collar doppler - degree of diffuse vascularisation; power doppler (PD) - flow speed at the level of the superior thyroid artery ,shear wave elastography (SWE) mean, maximum, minimum elasticity (KPA) , using MACH 30 AIXPLORER US machine, with the high frequency linear probe.

EVALUATION: Clinical picture, hormonal evaluation, inflammatory and autoimmune markers. Thyroid scintigraphy - golden standard.

Results Conventional ultrasound did show characteristic pattern in 58/73 DT and 71/87 GD cases. PW show significant higher speed values in GD cases (70/87) compared to DT (61/73). Shear wave parameters were significant different in 69/74 DT compared with low stiffness in all GD cases. The sensitivity and specificity of SWE is comparable with the one of scintigraphy PW information increase the sensitivity of the US diagnostic.

Conclusions Hypoecogenicity, speed of flow and degree of stiffness can replace scintigraphy in the final diagnostic of hyperthyroidism cases.

References

Donkol RH, Nada AM, Boughattas S. . World J Radiol. 2013 Apr 28;5(4):178-83.

Chung J, Lee YJ, Choi YJ, et al; Ultrasonography. 2020 Oct;39(4):315-330.

Golu I, Balas M, Amzar D, et al. Ultrasound Med Biol. 2022;48:S44. doi: 10.1016/j.ultrasmedbio.2022.04.128.

THE UTILITY OF VIRTUAL TOUCH IMAGING QUANTIFICATION (VTIQ) IN THE THYROID NODULES MONITORING

Vancu Mihaela¹, Lucan Eugenia Laura¹

1. The Center of Excellence in Ultrasonography DOCTOR VANCU

Abstract body

Aim

Thyroid diseases are common in the general population.

Assessing stiffness as indicator of malignancy, elastography has become an additional tool for thyroid nodules differentiation in combination with conventional ultrasonography and biopsy.

Methods

In our group practice, Share Wave Elastography, using VTIQ are performed by two physicians, using ACUSON S2000 HELX.

SWE is performed with the linear probe held with slight pressure and the patient in breath hold, making minim three acquisition in orthogonal plans.

With over six years of VTIQ experience and over 5500 thyroid investigations, including patients between 15-88 years old, we selected the most representative cases with multiple benign changes, malignant looking benign changes and typical malignant changes, according to the ultrasonographic features to the TI-RADS US classification system, following in time the thyroid lesions as TI-RADS:3 and TI-RADS:4, before and after biopsy.

Results

The speeds measured by VTIQ are significantly higher in malignant lesions than benign ones, over 3.0m/s.

Cancers tend to be stiff and also more heterogeneous than benign lesion (papillary carcinoma).

Follicular carcinomas, medullary and undifferentiated carcinoma can be soft and difficult to differentiate from benign nodules at first evaluation, but their stiffness is changing faster than benign lesions, noticed by VTIQ.

VTIQ can differentiate thyroid nodules even in the presence of autoimmune thyroiditis.

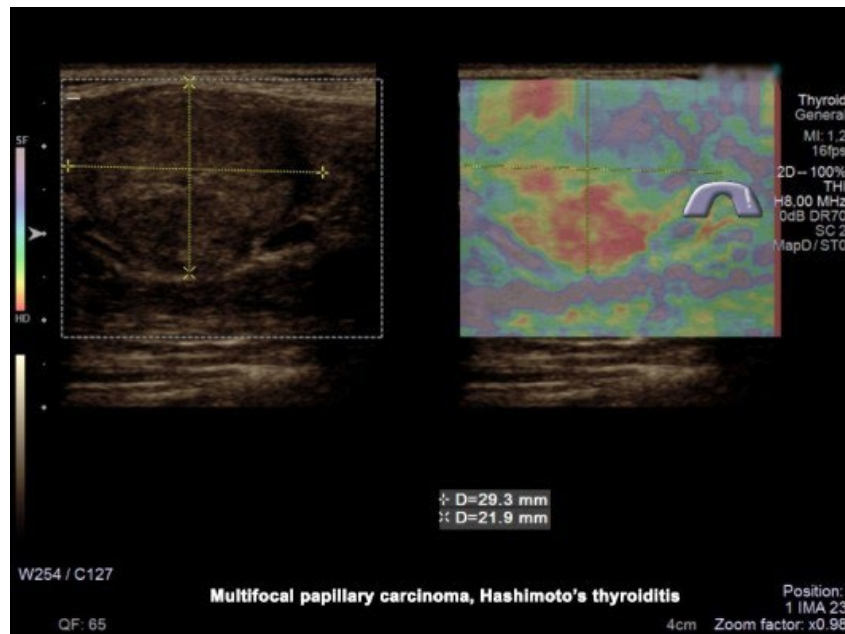
Conclusions

VTIQ is a useful complementary non-invasive and highly reproducible tool for follow up the thyroid lesions as TI-RADS:3 and TI-RADS:4.

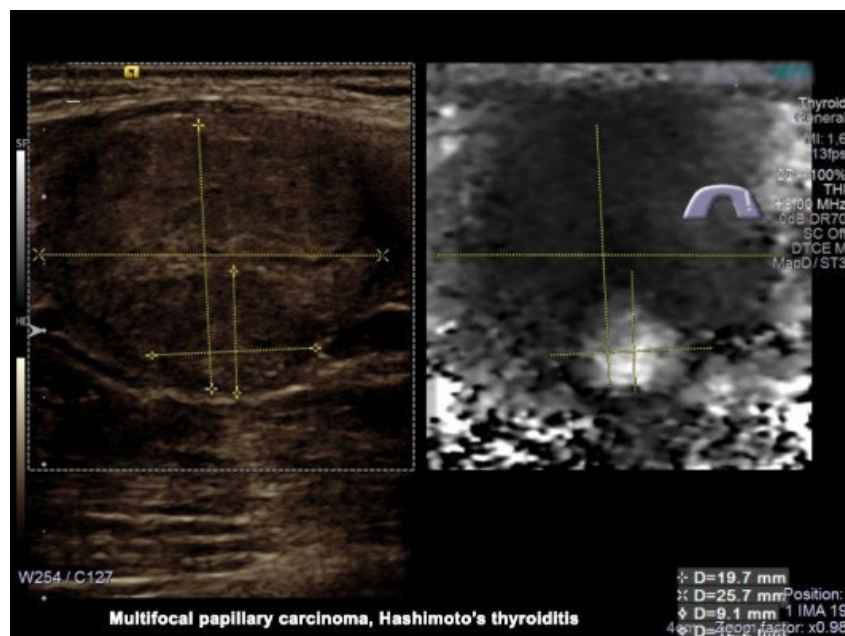
References

M.Vancu, L.E.Lucan, The contribution of advanced elastography in the thyroid nodules evaluation, Acta Medica Marisiensis, Vol.65, 2019

THE UTILITY OF VIRTUAL TOUCH IMAGING QUANTIFICATION (VTIQ) IN THE THYROID NODULES MONITORING

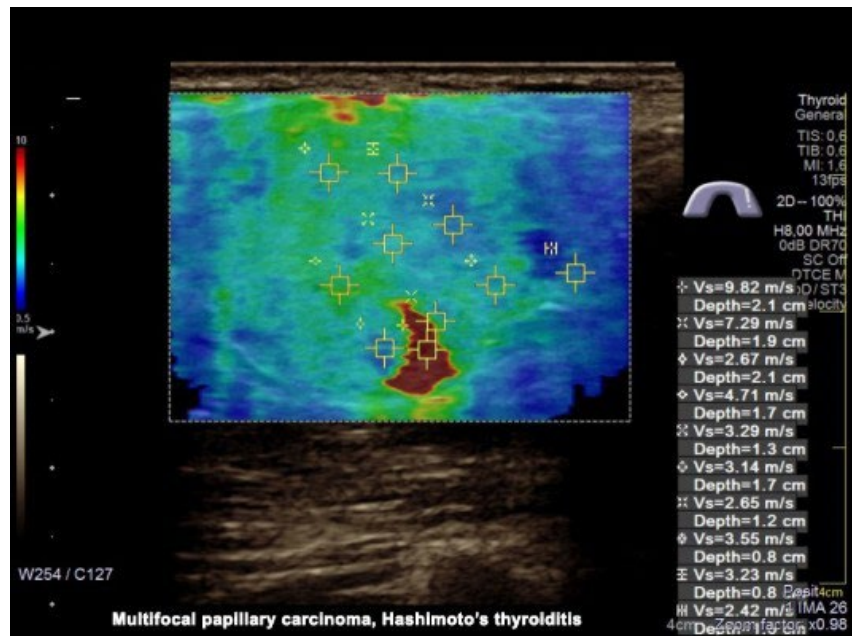


Multifocal papillary carcinoma, Hashimoto's thyroiditis



Multifocal papillary carcinoma, Hashimoto's thyroiditis

THE UTILITY OF VIRTUAL TOUCH IMAGING QUANTIFICATION (VTIQ) IN THE THYROID NODULES MONITORING



Multifocal papillary carcinoma, Hashimoto's thyroiditis

HEAD AND NECK ULTRASOUND TRAINING IMPROVES THE DIAGNOSTIC PERFORMANCE OF OTOLARYNGOLOGY RESIDENTS

Jens Jessen Warm¹, Tobias Todsen¹, Jacob Melchiors¹, Tina Toft Kristensen¹, Kristine Aabenhus¹, Kristine Eberhard¹

1. Department of Otorhinolaryngology, Head and Neck Surgery & Audiology, Copenhagen University Hospital Rigshospitalet, Denmark.

Abstract body

Objective: Otolaryngologists are increasingly using head and neck ultrasound in their daily clinical work. The objective of this study was to investigate the effect of a formal ultrasound course on head and neck residents.

Methods: Thirteen otorhinolaryngology residents participated in a ultrasonography course. Participants performed ultrasound examinations on four patient cases before and four after the course. Participants were randomly assigned to either scan the first four cases before the course or the last four cases before the course, with the remaining cases subsequently scanned. The patient cases were real patients with sonographically verified pathology recruited in the outpatient office at Rigshospitalet, mixed with healthy volunteers. Two assessors used the Objective Structured Assessment of Ultrasound Skills (OSAUS) to perform ultrasonography skill assessments, which were compared using paired t-test. Diagnostic accuracy, specificity and sensitivity were compared with McNemar's chi-squared test. The assessors were blinded to the participants' identities and course status.

Results: We found a statistically significant mean difference in the ultrasonography performance score before and after intervention (6.9, $P = 0.035$). The diagnostic accuracy increased from 62% before the course to 75% after the course ($P = 0.02$). Specificity increased from 54% prior to the course to 62% following the course, and sensitivity increased from 64% prior to the course to 79% following the course ($P = 0.02$). The intraclass correlation coefficient with "absolute agreement" was 0.63.

Conclusion: This study demonstrates that otolaryngology residents can improve their ultrasound skills and diagnostic accuracy by taking a formal hands-on neck ultrasound course

References

.

NOVEL ELASTOGRAPHY TECHNIQUES IDENTIFY FIBROSIS IN CHRONIC GLOMERULONEPHRITIS PATIENTS

Maralescu Felix-Mihai¹, Vaduva Adrian², Petrica Ligia¹, Schiller Adalbert¹, Bob Flaviu¹

1. Division of Nephrology, Department of Internal Medicine II, "Victor Babeş" University of Medicine and Pharmacy, 300041 Timișoara, Romania 2. Centre for Molecular Research in Nephrology and Vascular Disease, "Victor Babeş" University of Medicine and Pharmacy, 300041 Timișoara, Romania, 2. Discipline of Morphopathology, Department of Microscopic Morphology, Faculty of Medicine, Victor Babes University of Medicine and Pharmacy Timisoara, Timisoara, Romania.

Abstract body

Introduction: Renal biopsy represents the gold standard in the diagnosis, prognosis, and management of patients with kidney disease. The new and improved software from Hologic Supersonic Mach 30 comes as a promising noninvasive method for assessing renal tissue stiffness and viscosity. We investigated whether these elastography techniques could reveal renal tissue fibrosis in patients with chronic glomerulonephritis.

Materials and methods: 2D-shear wave elastography (SWE) PLUS and viscosity plane-wave ultrasound (Vi PLUS) assessments were performed in 38 patients with chronic glomerulonephritis, before being referred for renal biopsy. For each kidney, the mean values of five stiffness and viscosity measures were compared with the demographic, biological, and histopathological parameters of the patients.

Results: Out of 38 kidney biopsies, 2 were uninterpretable with inappropriate material. Even though these elastography techniques were unable to differentiate between separate fibrosis stages, predicting between the fibrosis and no fibrosis group we found a cut-off value of <20.77 kPa with the area under the curve (AUC) of 0.878, $p < 0.001$ with 94.1% sensitivity, and 73.6% specificity for 2D SWE PLUS measures and a cut-off value of <2.39 Pa.s with an AUC of 0.789, $p < 0.001$ with 82.3% sensitivity and 73.6% specificity for Vi PLUS measures. We also discovered a positive correlation between glomerular filtration rate (eGFR) and 2D-SWE PLUS values ($r = 0.6933$, $p < 0.0001$) and Vi PLUS values ($r = 0.3456$, $p < 0.0335$).

Conclusion: Our findings indicate that these novel elastography methods can distinguish between individuals with renal fibrosis and those without, but further research is required for them to be employed in clinical practice.

References

EVALUATION OF PERFUSION OF THE TRANSPLANTED KIDNEY BY CEUS AND STRUCTURAL ANALYSIS USING NATIVE MRI AFTER TRANSPLANTATION.

Dalia Mitraitė¹, Andrejus Bura², Antanas Jankauskas¹, Rūta Vaičiūnienė²

1. Lithuanian University of Health Sciences Kaunas Clinics hospital Radiology department,
2. Lithuanian University of Health Sciences Kaunas Clinics hospital Nephrology department

Abstract body

Background:

Donor and recipient factors are associated with recovery of renal function after transplantation (Tx). The hemodynamic and structural changes related to transplant kidney function after Tx are unknown. We present paired clinical cases in which we attempted to determine hemodynamic and structural changes in the early post-Tx period. The evaluation was performed using contrast-enhanced ultrasound (CEUS) and native magnetic resonance imaging (MRI).

Case report

In the Lithuanian University of Health Sciences Kaunas Clinics, kidneys from cadaveric donors were transplanted into 68-year-old women (1st patient) and 36-year-old men (2nd patient). 1st patient kidney transplant had immediate graft function (IGF) and 2nd patient had slow graft function (SGF). We performed CEUS and MRI in both cases.

CEUS evaluation showed that SGF wash-in slope was lower, time to peak – longer, peak intensity – lower in interlobar arteries, cortex and medulla than IGF (5,73 linear/sec, 26,14 sec, 19,40 linear, 2,08 linear/sec, 26,86 sec, 16,31 linear, 0,55 linear/sec, 35,37 sec, 6,04 linear respectively VS 9,60 linear/sec, 18,43 sec, 46,93 linear, 3,25 linear/sec, 22,25 sec, 26,69 linear, 1,50 linear/sec, 28,74 sec, 17,46 linear respectively).

MRI evaluation showed that SGF T1 MAP corticomedullary differentiation was more difficult visually and according to relaxation time than IGF (1255 ms and 1400 ms VS 1676 ms and 1913 ms). The same trend was observed in T2 MAP (84 ms and 82 ms VS 99 ms and 85 ms).

Conclusions

Our clinical cases of transplanted kidney demonstrate the possible relationship between magnetic resonance relaxometry and CEUS parameters.

References

-

DIAGNOSTIC PERFORMANCE OF THE BOSNIAK 2019 CLASSIFICATION IN COMPARISON WITH CEUS IN CYSTIC RENAL LESIONS AS INCIDENTAL FINDING

***Giovanni Del Gaudio*¹, Vito Cantisani¹, Richard G. Barr²**

1. Sapienza University of Rome, 2. Northeast Ohio Medical University, Rootstown, Ohio

Abstract body

Actuality and Aim: To determine the number of lesions which could not be classified on CT and compare the diagnostic accuracy of CT in comparison with CEUS in the evaluation of indeterminate cystic lesions.

Materials and Methods: This is a retrospective single center study. Between March 2018 and November 2022 cases where a CT (non-enhanced or enhanced) and CEUS were performed within 3 months of each other for evaluation of a renal mass were identified. The images were evaluated by two operators with different experience. Of the 1455 initial patients, 115 cases were evaluated who had indeterminate cystic renal masses, previously detected on CT. A CEUS examination was performed and classified based on two proposed classifications.

Results: Among 115 patients (mean age 70 ± 10.58 [SD]) considering 1 cystic lesion per patients, only 3 with triphasic CT protocol (without contrast: 48; with one or two phase of contrast: 64; triphasic: 3) could be assigned a Bosniak score, missing 18 diagnosis of 18 high risk lesion (Bosniak 3-4) evaluated with CEUS. Among the highly likely to be benign cysts in CT, 9 were high risk in CEUS.

Conclusion: With its improved resolution and real-time evaluation, CEUS has proven to be diagnostic in most of cases of indeterminate renal masses on CT, representing a fundamental diagnostic tool in the characterization of indeterminate cystic renal lesions in comparison to incidental findings in CT.

References

Barr RG. Use of lumason/sonovue in contrast-enhanced ultrasound of the kidney for characterization of renal masses-a meta-analysis. *Abdom Radiol (NY)*. 2022 Jan;47(1):272-287.

PRACTICE MAKES PERFECT: THE EFFECT OF WORK EXPERIENCE IN DETERMINING ACCIDENTAL KIDNEY CALCULI

***Jurgis Petkevicius*¹, Algirda Venclauskiene¹, Tomas Jurevicius¹**

1. Lithuanian University of Health Sciences Kaunas Clinics

Abstract body

Actuality and Aim: Global prevalence of nephrolithiasis in the population has been steadily increasing (recurrence of ~5-year rate of >50%). The aim of the study is to determine the sensitivity and specificity of the ultrasound (US) of accidental kidney calculi when are evaluated by doctors with different work experience: radiology residents, radiologists >5 years of experience, and radiologists with >10 years of experience.

Materials and Methods: 54 patients underwent a native abdominal or abdominal-pelvic CT scan and an additional renal US examination. US videos of 100 kidneys were viewed by radiology residents and radiologists with different work experience. Their results were compared with the CT study data.

Results: The sensitivity and specificity of the US examination for the detection of accidental renal stones were determined by the radiologists: regardless of the size of the stones (sensitivity 63,6%, specificity 87,0%), <5mm (sensitivity 28,6%, specificity 90,3%), and ≥5mm (sensitivity 57,5%, specificity 95,9%). Radiology residents: regardless of the size of the stones (sensitivity 31,8%, specificity 84,2%), calculi <5mm (sensitivity 14.3%, specificity 89,9%) and ≥5mm (sensitivity 23,1%, specificity 93,1%).

Conclusions: The results conclusively demonstrate that the radiologists with more work experience were able to reach higher sensitivity and specificity.

References

1. Trinchieri A. Epidemiology of urolithiasis: an update. Clin Cases Miner Bone Metab.2008;May-Aug;5(2):101-106.
2. V. K. Sigurjonsdottir, H. L.Runolfssdottir, O.S. Indridason et al. Impact of nephrolithiasis on kidney function. BMC Nephrology; 2015 Aug 28;16:149.
3. Saeed R. Khan, Margaret S. Pearle, William G. Robertson et al. Kidney stones. Nat Rev Dis Primers.2017;Nov;2:16008.

RADIOGRAPHERS' INDIVIDUAL PERSPECTIVES ON SONOGRAPHY – A SURVEY OF EUROPEAN FEDERATION OF RADIOGRAPHER SOCIETIES (EFRS)

Malene Roland Pedersen¹, ***Barbara Kraus***², ***Rute Santos***³, ***Gill Harrison***⁴

1. Sygehus Lillebaelt, Vejle Hospital, Beriderbakken 4, DK-7100 Vejle, 2. Department of Health Sciences, Radiological Technology, University of Applied Sciences FH Campus Wien, Favoritenstrasse 226, A-1100, Vienna, Austria, 3. Polytechnic Institute of Coimbra, Coimbra Health School, Department of Clinical Physiology, Rua 5 de Outubro - SM Bispo, Apartado 7006, 3046-854, Coimbra, Portugal f Laboratory for Applied, 4. Society and College of Radiographers, 207 Providence Square Mill Street, London, SE1 2EW, UK

Abstract body

Radiographers can work with many different modalities, one being ultrasound. In Europe there are differing opinions about how radiographers should take in the role in ultrasound in relation to examination, particularly report writing. Aim was to explore the radiographer's views on working within sonography.

Methods: In 2019 an electronic survey was disseminated to radiographer members by European Federation of Radiographer Societies (EFRS) national radiographer societies. The survey aimed to investigate radiographers' practice, legal responsibilities, report writing, educational level, experiences of support and mentoring.

Results: 561 radiographers participated, most (92%) reported performing ultrasound scans. Challenges with legislation, protectionism and lack of high-quality education restricted often radiographers. A total of 60% had postgraduate education and carried out a wide range of examinations. A full interpretative report including advice on further investigations is performed by 52%, whilst 22% provide a checklist or descriptive report. The majority had clear protocols, good mentoring and support in the workplace. Peer review of their work was less common.

Conclusion: In 21 (n = 25) countries radiographers perform ultrasound examinations, however variance in educational levels (ranges from no formal education or short courses to an MSc in ultrasound). Report writing practice differs across the EFRS countries responding to the survey, as does peer review to enhance skills and clinical practice.

References

Harrison G, et al. The role of radiographers in ultrasound: a survey of the national societies within the European Federation of Radiographer Societies (EFRS). *Radiography* 2021;27:761e7.
EFRS. Development of the radiographer role. EFRS guidance document. Available from: <https://api.ehrs.eu/api/assets/posts/128>.

MULTISEPTATE “HONEYCOMB” GALLBLADDER – DIAGNOSTIC VALUE OF CONTRAST-ENHANCED ULTRASOUND

Katerina Lyoncheva-Kaneva¹, ***Aneliya Decheva***¹, ***Radin Tzonev***¹,
Veselin Marinov², ***Ivan Galev***³

1. Acibadem City Clinic Tokuda Hospital - Department of Gastroenterology, 2. Acibadem City Clinic Tokuda Hospital - Department of Hepatobiliary and Pancreatic Surgery, 3. Acibadem City Clinic Tokuda Hospital - Department of Pathology

Abstract body

Multiseptated gallbladder(MSG) is a rare ultrasound finding. There are about 150 cases of MSG reported between 1952 and 2022 (1) . The etiology is unclear as there are multiple theories regarding the pathophysiology of MSG, the main being a congenital anomaly or MSG as a reaction to a chronic inflammation.

We are reporting a 31.y.o. female who presented to our hospital with no complaints and atypical ultrasound image of the gallbladder found in the course of a preventative visit.

Ultrasonography of the abdomen was performed, showing hyperechogenic heterogenic content of the lumen, No evidence of gallbladder wall thickening, pericholecystic fluid, or cholelithiasis were found. There were no signs of biliary obstruction. Scanning with high frequency ultrasound probe reveals multiple septations in the gallbladder forming a honeycomb structure. Contrast-enhanced ultrasound(CEUS) has shown contrasting of the septa walls, verifying the structure described in the high frequency probe scanning.

Since there is no possibility of differentiating a benign multiseptated gallbladder disease from a malignant one just by the method of ultrasound or computed tomography(CT) the case was discussed with a surgical team, and after evaluating the risks and the benefits of surgical management a laparoscopic cholecystectomy was performed. Intraoperative macroscopic evaluation described multiseptated lumen with incomplete septa.

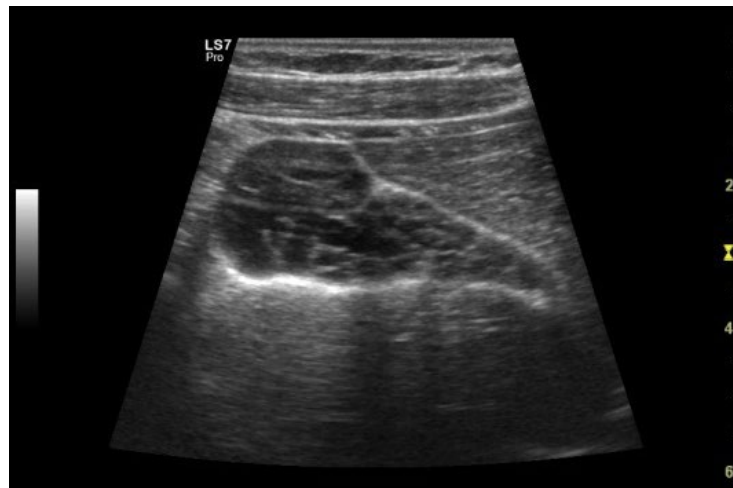
Histology disclosed several Rokitansky-Aschoff sinuses.

Conclusion: There was a higher grade of correspondence between the CEUS finding and the surgical specimen compared to CT.

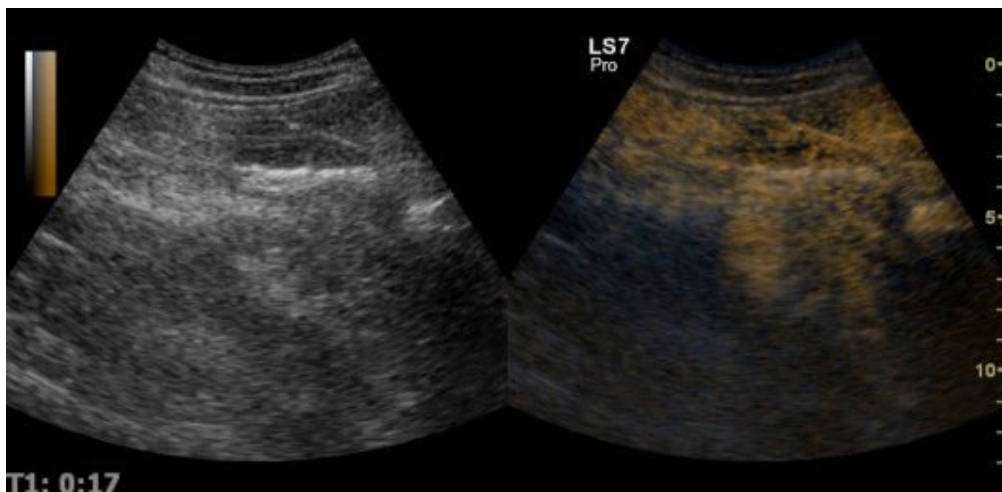
References

1. Terkawi RS, Qutob D, Hendaus MA. Understanding multiseptated gallbladder: A systematic analysis with a case report.

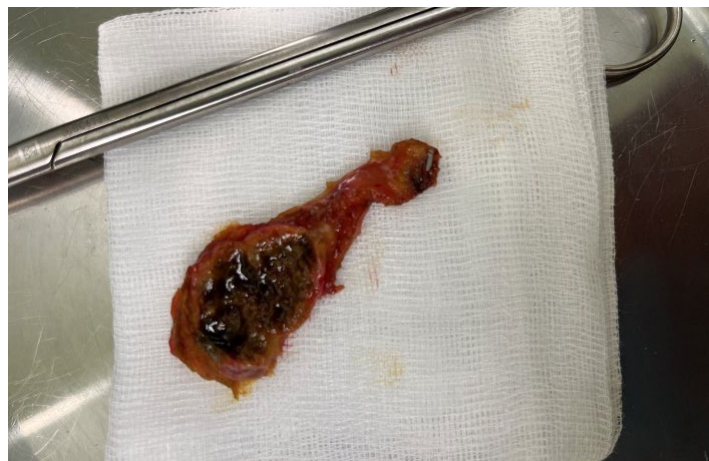MULTISEPTATE “HONEYCOMB” GALLBLADDER – DIAGNOSTIC VALUE OF CONTRAST-ENHANCED ULTRASOUND



High frequency ultrasound -
multiseptated gallbladder.



CEUS -
multiseptated
gallbladder.



Surgical specimen -
multiseptated gallbladder.

SONOGRAPHIC DIAGNOSIS OF A POTT'S PUFFY TUMOR IN A 5-YEAR-OLD-GIRL

Dr. Marie Brandt¹, Dr. Marie Brandt¹, Prof. Dr. Karl-Michael Schebsch², Tommaso Araceli², Elena Kuhn³, Prof. Dr. Christopher Bohr¹, Prof. Dr. Julian Künzel¹

1. Department of Otorhinolaryngology, Head and Neck Surgery, University Hospital of Regensburg, Germany, 2. Department for Neurosurgery, University Hospital of Regensburg, Germany, 3. Department of Pediatrics, University Hospital of Regensburg, Germany

Abstract body

Background

A Pott's Puffy Tumor (PPT) is a rare medical condition developed in patients with an inefficiently treated frontal sinusitis. It is defined by an osteomyelitis of the frontal bone accompanied by an extra- or intracranial abscess. Leading symptoms are a swollen forehead and severe headache. Common imaging methods like MRI, CT and ultrasound are available to lead to the correct diagnosis. Therapy includes antibiotics, endoscopic sinus surgery and brain abscess drainage by neurosurgery. (1)

Case report

On July 22, a 5-year-old girl presented an expanding swelling of the forehead and an increasing headache. Physical examination showed a doughy, tender swelling in the centre of the forehead. Inflammatory markers were elevated in the blood test. Ultrasound revealed a subgaleal hypoechoic mass typical of PPT and quickly led to consecutive MRI scanning. Emergency combined neurosurgery and otorhinolaryngology surgery was performed. The microbiological results indicated an infection with *Streptococcus anginosus*. Therapy was completed with antibiotics for six weeks.

Conclusions

PPTs are uncommon and might show inconclusive clinical findings. A delay in diagnosis can lead to serious complications. Ultrasound is a crucial component of the point of care clinical investigation. It is an easily accessible device that can prevent children from radiation through a CT scan. (2) We detected a PPT in a five-year-old by ultrasound of the forehead. Due to a prompt diagnosis, followed by an urgent MRI scan and surgery, the child recovered without further complications.

References

1. Koltsidopoulos et al. Laryngoscope 2020. 2.[]
- Reddan et al. J Med Radiat Sci 2018.

JAUNDICE IN A NEWBORN? ULTRASOUND DIAGNOSIS CONFIRMED: BILIARY ATRESIA

***Ioan Tiberiu Tofolean*¹, *Mihaela Tanco*¹**

1. Ovidius University of Constanta

Abstract body

Background: The role of conventional ultrasound remains undervalued, despite the easily available and non-invasive character of the investigation. It is stated that the diagnostic accuracy of the method doesn't exceed 80 % in biliary atresia cases, but is important in excluding other etiologies of obstructive jaundice and is highly suggestive in evaluation of liver aspect and stiffness, presence of ascites, and vasculature patency.

Case report: We report the case of 7 weeks old female, admitted in Pediatrics department for prolonged jaundice, aggravated progressively, associated with acholic stools and hyperchromic urine.

The conventional abdominal and pelvic ultrasound examination revealed absence of patent common biliary duct, with pseudogallbladder image (a transonic wedge-shaped image, but with no proper wall identified) in the area where usually normal gallbladder shows.

Conclusions: The patient was referred to a specialized pediatric surgery center in another city, where the decision for diagnosis confirmation was performing a Magnetic Resonance Cholangiopancreatography (MRCP). The investigation confirmed type III biliary atresia and the patient underwent portoenterostomy (Kasai procedure), with good postprocedural evolution.

Acknowledgements: Ultrasound proved again as an important investigation method for positive and differential diagnosis regarding biliary pathology in pediatric population also.

References

1. Wang KS. Newborn screening for biliary atresia. *Pediatrics*. 2015;136(6):e1663-e1669
2. Erlichman J, Loomes KM. Biliary atresia. UpToDate website. www.uptodate.com/contents/biliary-atresia External link. Updated December 5, 2022.
3. Siddiqui AI, Ahmad T. Biliary Atresia. [Updated 2022 Jun 27]. In: StatPearls [Internet]. Treasure Island (FL): StatPearls Publishing; 2022 Jan-. Available from: <https://www.ncbi.nlm.nih.gov/books/NBK537262/>

INCIDENTAL DETECTION OF ACCESSORY LEFT RENAL POLAR VEIN DURING ABDOMINAL USG

***Enes Serbetci*¹, Husamettin Alper Kimyonok¹, Mehmet Savas Yer¹, Yusuf Gunduz¹, Abdullah Soydan Mahmutoglu¹**

1. Istanbul Education and Research Hospital, Radiology Department

Abstract body

Venous anomalies, mainly occurring due to the failure of the embryological development, are frequently observed(1). Venous anomalies of the retroperitoneal region have clinical implications mainly in retroperitoneal surgeries.

A 31-years-old male patient admitted to Emergency Service with complaints of flank pain and hematuria. Patient referred to Radiology department for abdominal USG with suspicion of nefrolithiasis. During examination with the help of doppler USG, a dilated vascular structure that drained the lower pole of the left kidney was detected. The vascular structure drained in to the left common iliac vein. The patient referred to MR Angiography which revealed that left renal vein was normal and it was accompanied by an accessory dilated vein that drained lower pole of left kidney to left common iliac vein. Also the patient referred to CT scan which revealed a calculus in the left distal ureter.

Determination of the renal vasculature is critical for safe nephrectomy(2). The aim of this article is to emphasize the importance of color doppler USG examination to detect possible renal vascular variations.

References

- 1) Anupma gupta, Raman gupta, Rikki singal. Congenital Variations of Renal Veins: Embryological Background And Clinical Implications. Journal of Clinical and Diagnostic Research. 2011 November (Suppl-1), Vol-5(6): 1140-1143
- 2) Ahmed Eldefrawy, Mohan Arianayagam, Prashanth Kanagarajah, Kristell Acosta, and Murugesan Manoharan. Anomalies of the inferior vena cava and renal veins and implications for renal surgery. Cent European J Urol. 2011; 64(1): 4-8.

CONTRAST ENHANCED ULTRASOUND (CEUS) FOR IMAGING AND SURGICAL PLANNING OF A SECOND BRANCHIAL CLEFT FISTULA

Maximilian Rink¹, Julian Künzel¹, Christopher Bohr¹, Ernst-Michael Jung²

1. Klinik und Poliklinik für Hals-, Nasen- und Ohrenheilkunde, Universitätsklinikum Regensburg,

2. Institut für Röntgendiagnostik, Universitätsklinikum Regensburg

Abstract body

Background

Second branchial cleft fistulas should be removed because of the risk of inflammation. Complete resection is crucial for success in the long term (1). Preoperative imaging can provide the surgeon with valuable information about the length of the fistula tract and its relationship to large vessels. The established methods (B-scan ultrasound, MRI, CT) all have inherent disadvantages (2). In the present case, the fistula tract could be completely visualised by CEUS with intraductal administration of contrast medium. To our knowledge, this is the first description of this technique.

Case

The patient was a 6-year old boy with a fistula known since birth. In addition, there was a cyst dorsocranial to the right tonsil. Intraoperatively CEUS was performed which allowed a complete visualisation of the fistula tract up to the cyst. As the entire path of the duct was known, a minimally invasive procedure could be done with only one cervical incision. The excision in toto was successful.

Conclusion

Visualising a fistula tract in the way we described is an innovative and gentle approach. CT, MRI or colouring can thus be dispensed with.

References

1: Shen et al., Second branchial cleft anomalies in children: a literature review, *Pediatric Surgery International* (2018) 34:1251-1256

2: Mehmi et al., Importance and Impact of Appropriate Radiology in the Management of Branchial Cleft Anomalies, *Indian J Otolaryngol Head Neck Surg* (October 2019) 71(Suppl 1):S953-S959

CEUS IN THE DIAGNOSIS OF A PARATHYROID ADENOMA – CASE REPORT

Andreea-Daniela Toma¹, Mihalea Vlad¹

1. "Victor Babes" University of Medicine and Pharmacy Timisoara, Romania

Abstract body

The parathyroid adenomas are located around the thyroid gland or even intrathyroidal and, in certain situations, can be confused with thyroid nodules.

The aim of this presentation is to assess the value of CEUS in the differentiation of a parathyroid adenoma from a thyroid nodule.

Case-presentation: We report a case of a 29-year-old female patient who was referred to our clinic for assessment of a thyroid incidentaloma. The patient's medical history revealed an episode of acute renal colic. 2D-ultrasound showed a solid, intense hypoechoic nodule in the lower pole of the left thyroid lobe with regular margins (9/10mm) and the blood supply by Doppler appeared to arise from a polar artery (extrathyroidal blood supply) an aspect very suggestive for a parathyroid lesion. 2D-SWE indicated a homogeneous aspect, with very low stiffness. CEUS showed a homogeneous lesions with similar enhancement and wash-in to the thyroid parenchyma. Laboratory tests performed later indicated increased PTH level and hypercalcemia. The parathyroid scintiscan was positive for a parathyroid adenoma. Minimally invasive parathyroidectomy was performed and pathology confirmed a parathyroid adenoma.

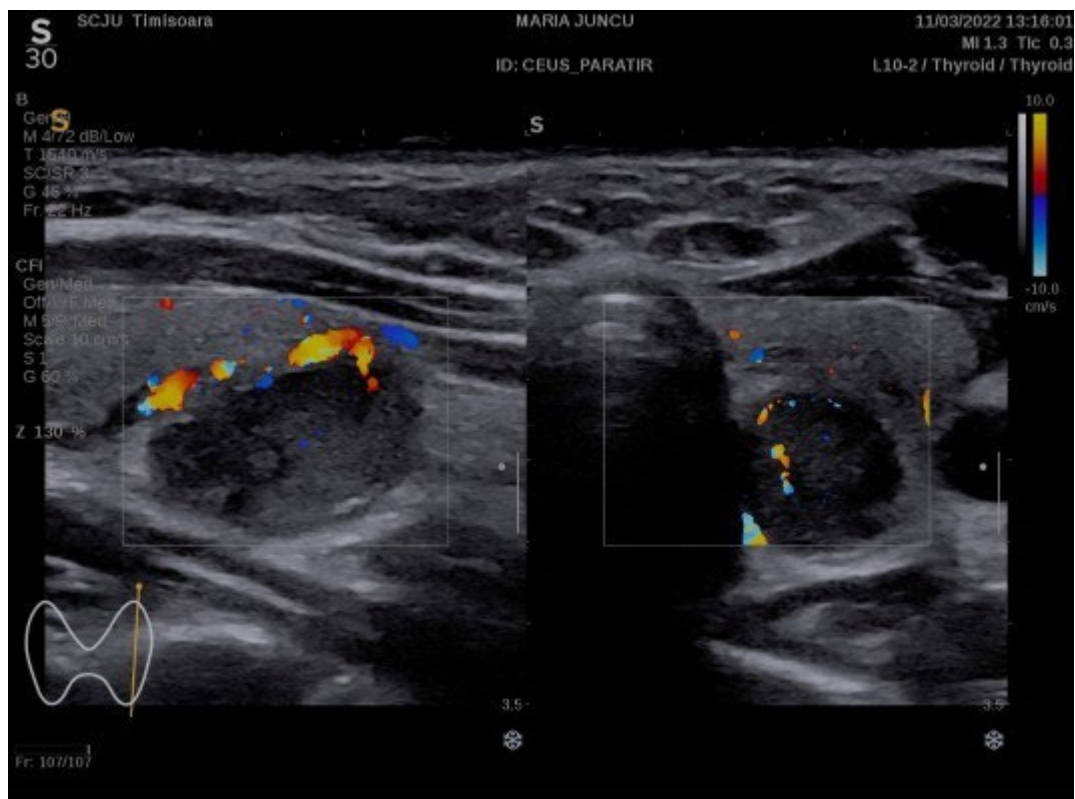
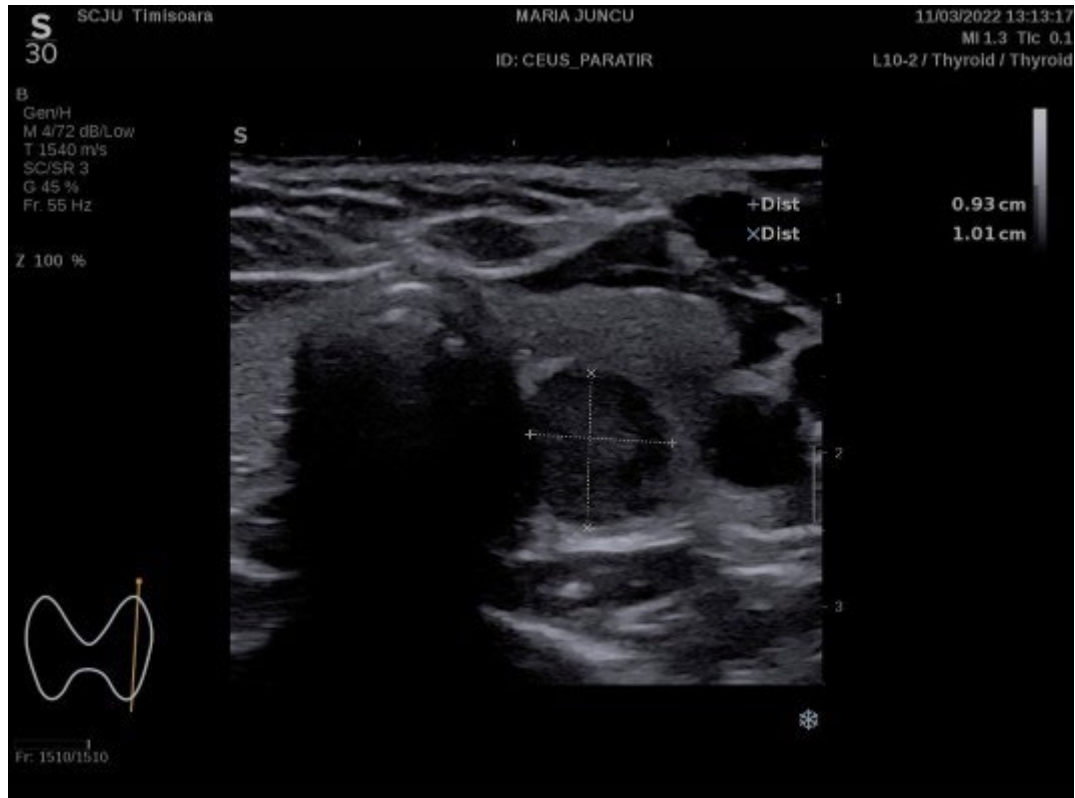RESULTS: In this case, CEUS did not achieved good performance in the differential diagnosis between parathyroid adenoma and thyroid nodule.

CONCLUSION: CEUS did not provide additional information regarding to a clear diagnosis of the parathyroid adenoma compared to results of US and scintiscan.

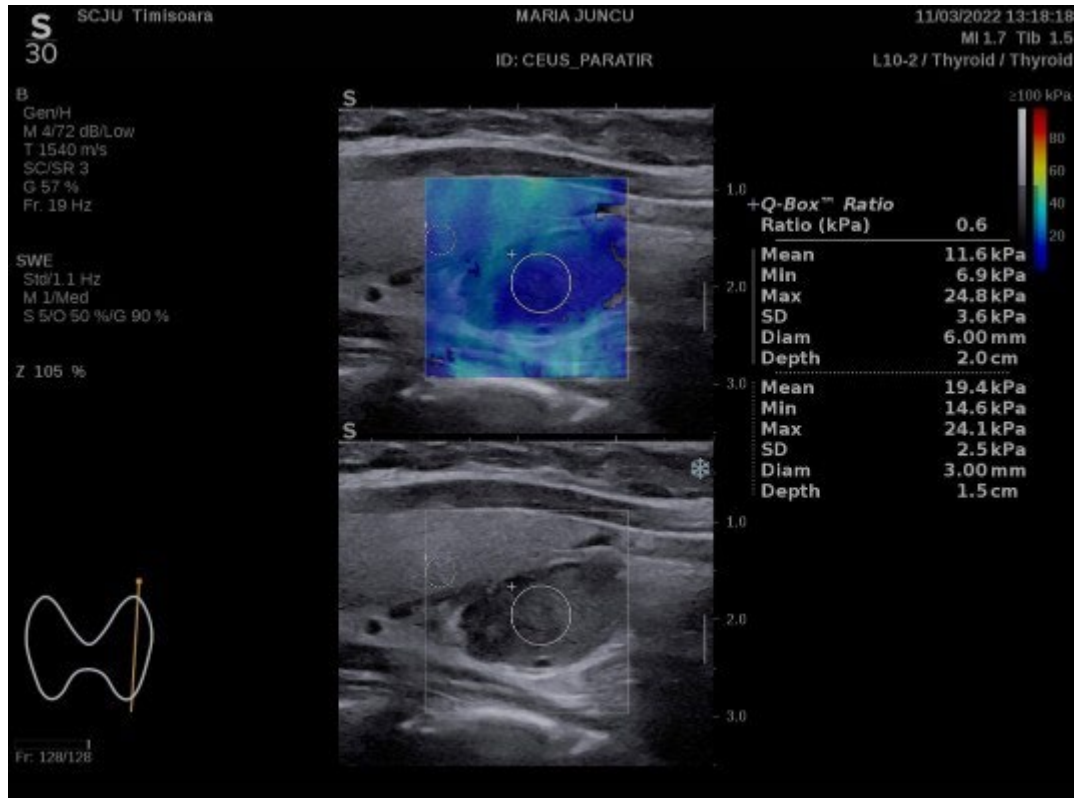
References

REFERENCES: E. Karakas, S. Kann, H. Hoffken, et al. Does contrast-enhanced cervical ultrasonography improve preoperative localization results in patients with sporadic primary hyperparathyroidism? J Clin Imaging Sci. 2012;2:64. doi:10.4103/2156-7514.103054. Epub 2012 Oct 31.

CEUS IN THE DIAGNOSIS OF A PARATHYROID ADENOMA – CASE REPORT



CEUS IN THE DIAGNOSIS OF A PARATHYROID ADENOMA – CASE REPORT



RHABDOMYOLYSIS AFTER INTENSE EXERCISE IN ULTRASOUND – CASE REPORT

Paweł Walisiewicz¹, Wojciech Kosiak¹

1. University Medical Center in Gdańsk

Abstract body

BACKGROUND

Rhabdomyolysis is a condition in which skeletal muscle are damaged. It is most often caused by toxins, injuries or convulsions. This paper presents a case of rhabdomyolysis resulting from strenuous training and the use of ultrasonography in diagnosis and treatment.

CASE REPORT

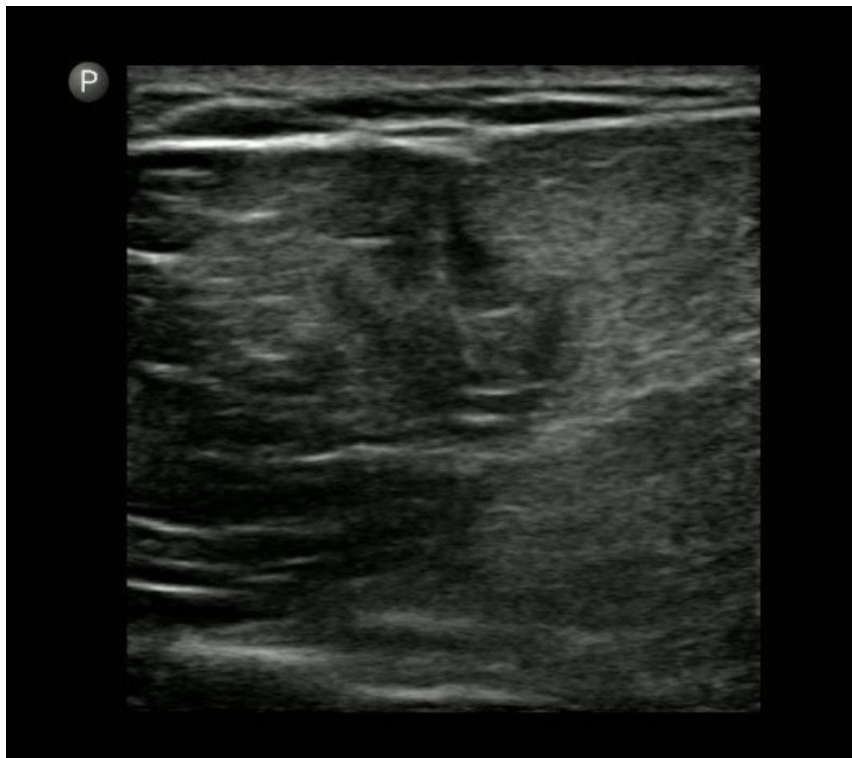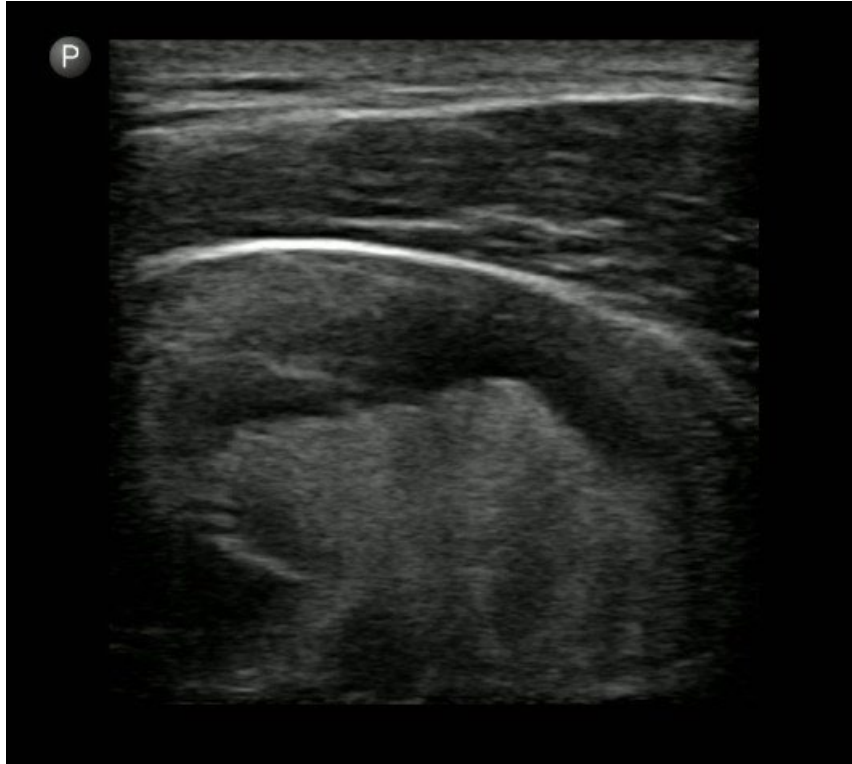A 28-year-old man after strenuous cross-fit training. One hour after the training, increasing pain ailments appeared in the upper limb girdle muscles, triceps muscles of the arm and the right serratus anterior muscle, with swelling and limitation of mobility. After a few hours, the patient presented with dark-brown urine. In laboratory tests: typical features of myoglobinuria in urinalysis, slightly elevated level of aminotransferases, CK 2500U/l. Ultrasound showed obliteration of typical muscle echostructure, edema and increased echogenicity of frosted glass type in deltoid muscles, supraspinatus muscles, triceps muscles and the right serratus anterior muscle. Analgesic treatment, intensive intravenous and oral fluid therapy were used. After identifying damaged muscles and consulting a physiotherapist, targeted rehabilitation was started. Gradual clinical improvement was obtained. In control tests carried out 4 days after the injury: ALT 535U/l, AST 1252U/l, CK >42670U/l, with a downward trend in subsequent tests. The control ultrasound examination showed gradual normalization of the muscle's image.

CONCLUSIONS

Point-of-care ultrasonography is helpful in the diagnosis and monitoring of rhabdomyolysis treatment and planning the rehabilitation of patients. The current state of knowledge doesn't define the role of ultrasound in the differential diagnosis of rhabdomyolysis with other myopathies and the time of normalization of the US image, which requires further research.

References

RHABDOMYOLYSIS AFTER INTENSE EXERCISE IN ULTRASOUND – CASE REPORT



THYROID VOLUME MEASUREMENT WITH FREEHAND THREE-DIMENSIONAL ULTRASOUND COMPARED TO TWO-DIMENSIONAL ULTRASOUND

Klara Bay Rask¹, Tobias Todsén¹, Fatemeh Makouei¹, Tina Toft Kristensen¹,
Marcus Hans Jakowlew Wessman¹

1. Department of Otorhinolaryngology, Head and Neck Surgery & Audiology,
Rigshospitalet, Copenhagen

Abstract body

Actuality and Aim :

Conventional two-dimensional ultrasound (2D) is one of the imaging modalities used to visualize the thyroid gland; however, the dynamic nature of the image makes it operator-dependent, which decreases the repeatability of the measurements. Freehand three-dimensional (3D) ultrasound techniques have been proposed as a promising tool for obtaining volumetric data on the thyroid.

Method:

We used 2D and 3D ultrasound to prospectively measure the volumes of 17 thyroids from patients referred for a total thyroidectomy. Using 2D ultrasound, an operator estimated the volume of each lobe by the ellipsoid formula. Two physicians evaluated 3D ultrasound images of the thyroids and performed semiautomated segmentation to estimate the volume. The data were then compared to the water displacement of the excised thyroids with a paired T-test. The interclass correlation coefficient was used to determine the intra- and inter-operator reliability of the two clinicians using the 3D technique. To investigate agreements of all comparisons we made Bland-Altman plots.

Results:

Results showed that the mean difference between the reference and 3D and 2D was 1.5% (95%CI -15.7-18.6%, $p=0.85$) and 23.7% (95%CI 14.2-33%, $p<0.001$) respectively. The inter-operator reliability was 0.995 $p<0.001$ and intra-operator reliability was 0.996 and 0.993 $p<0.001$ for operators 1 and 2 respectively.

Conclusion:

The mean 3D ultrasound measurements were closer to the water displacement compared to 2D ultrasound. However, the confidence interval was wide. 2D ultrasound was systematically underestimating the thyroid volume. Operators demonstrated a high degree of correlation and agreement.

References

THE FIRST 5 TARGETED TRANS-PERINEAL PROSTATE BIOPSIES DIAGNOSE THE MAJORITY OF PROMIS CRITERIA CANCER IN PATIENTS WITH A LIKERT 4 OR 5 SCORE ON MPMRI

**Adam Morrell¹, W. M. Stevens¹, E. Adiotomre¹, O. Hulson¹, A. Khan¹,
R. Lapham¹, P. Melling¹, S. Pierre¹, J. Smith¹**

1. Department of Radiology, St James's University Hospital,
Leeds Teaching Hospitals NHS Trust, Leeds, England

Abstract body

Introduction

Locally the total number of prostate biopsies taken by practitioners is variable and this is reflected within the literature with no consensus. There is a trend towards taking more biopsies in order to increase cancer detection rate and minimise need for repeat biopsy however, this increases complication rates and the diagnosis of clinically insignificant cancers. NICE guidelines suggest multiple prostate biopsies for histological diagnosis of cancer in those patients with a Likert 4 or 5 score on their mpMRI scan. Depending on the treatment planned, some patients need systematic TP biopsy, but in frail patients, those with limited treatment options or extensive disease, a cancer diagnosis may be all that is required.

Aims and Methods

To see if the first 2-5 targeted transperineal (TP) biopsies give a diagnosis of PROMIS criteria cancer in patients with a likely prostate cancer on mpMRI. 375 patients had an mpMRI for suspected prostate cancer between January and June of 2021 in a large volume quaternary centre. 367 were given a Likert score of which 108 were scored Likert 4 or 5. Of these, 94 patients were sent for biopsy. 70 of the biopsied patients were ultimately diagnosed with PROMIS criteria cancer. A separate pot was sent containing the first 2-5 targeted biopsies in 69 of the 70.

Results

The median number of biopsies in all patients sent for biopsy was 12 (range 3-19). The first 2-5 targeted biopsies showed PROMIS criteria cancer in 65 of the 69 (94.2%) Likert 4 and 5 patients diagnosed with cancer. 62/69 (89.9%) showed the maximum length or grade of cancer in the first 2-5 targeted biopsies. All 4 of the missed cancers were ISUP 2 or less and located in the apex of the gland.

Conclusion

A cancer diagnosis is usually obtained in the first 2-5 targeted biopsies in patients with a Likert score of 4 or 5. Further biopsies may be required for treatment planning or for lesions in the apex of the gland where cancers can be missed.

References

-

RENAL ELASTOGRAPHY TO PREDICT THE THERAPEUTIC RESPONSE OF THE NEPHROLOGICAL PATIENT

***Nicoletta Mancianti*¹, Sacco Palmino², Tripodi Sergio³, Guarnieri Andrea¹, Belluardo Massimo¹**

1. Department of Emergency-Urgency and Transplantation, Nephrology, Dialysis and Transplantation Unit, University Hospital of Siena, Siena, Italy, 2. Department of Radiological Sciences, Diagnostic Imaging Unit, "Azienda Ospedaliera Universitaria Senese", Siena, Italy, 3. Department of Oncology, Pathology Unit, University Hospital of Siena, Siena, Italy

Abstract body

Introduction

Chronic kidney disease is a pathology burdened by high mortality and characterized by a progressive course. The main pathogenetic process underlying this progression is represented by matrix deposition extracellular in the interstitium, resulting in fibrosis.

Early identification and quantification of renal fibrosis make it possible to optimize supportive therapy to delay the progression of impaired organ function.

The gold standard for assessing the extent of renal fibrosis is the biopsy, a sensitive and specific method, but invasive and therefore burdened by possible serious complications; it is consequently not repeatable with high frequency for follow-up purposes.

A non-invasive method based on ultrasound, elastography, has been proposed to quantify organ fibrosis. Elastography has already demonstrated adequate specificity and sensitivity results in the hepatic field, which has certified it as a method included in the diagnostic guidelines.

The purposes of our experience were:

- 1) verify the possible correlations of the renal elastography with the share of chronic renal histological damage biopsy demonstrated
- 2) evaluate the predictivity of nephrological elastography concerning kidney injury evolution.

Aims and Methods

Forty-one patients admitted to the Nephrology, Dialysis, and Transplant Unit of the University Hospital of Siena, who underwent renal biopsy, were enrolled in the study. In the biopsy, the 5 main histological parameters indicative of chronic renal damage were detected: total chronicity score and the 4 partial scores (glomerulosclerosis, interstitial fibrosis, tubular atrophy, and arteriosclerosis). Elastography was performed on all patients to estimate renal stiffness using Young's Modulus (YM). All patients also underwent a basal multi-parametric evaluation concerning blood and urinary data, ultrasound, and renal eco color-doppler. Patients were divided into responders, partial-responders, and non-responders based on the criteria established by the KDIGO guidelines; correlations between YM and baseline multi-parametric assessment and responsiveness to therapy were then sought. The follow-up data regarding the renal disease evolution were recorded.

Results

No correlation was found between YM and the 5 chronic renal damage histological scores.

The total chronic histological score correlates significantly with serum creatinine levels at the biopsy ($P = 0.0007$). Patient responsiveness was associated with YM: the distribution of YM saw lower values in the responder group, intermediate in partial-responders, and higher in non-responders; this distribution was statistically significant ($P = 0.036$). Fig.1

Conclusion

The predictivity of the therapeutic response is a determining factor in the modulation of the treatment, with potentially significant repercussions on the patient's prognosis. Our experience is the first study evaluating renal YM's predictivity on response to nephrological therapy

References

-

MULTI-APERTURE ULTRASOUND IMAGING AND ELASTOGRAPHY OF THE ABDOMINAL AORTA: FROM BENCH TO BEDSIDE

Vera H.J. van Hal¹, Hans-Martin Schwab¹, Hein de Hoop¹, Jan-Willem Muller², Marc R.H.M. van Sambeek², Richard G.P. Lopata¹

1. Photoacoustics & Ultrasound Laboratory Eindhoven (PULS/e), dept. of Biomedical Engineering, Eindhoven University of Technology, De Rondon 70, 5612 AP Eindhoven, The Netherlands,
2. Photoacoustics & Ultrasound Laboratory Eindhoven (PULS/e), dept. of Biomedical Engineering, Eindhoven University of Technology, De Rondon 70, 5612 AP Eindhoven, The Netherlands. Department of Vascular Surgery, Catharina Hospital Eindhoven, P.O. Box 1350, 5602 ZA Eindhoven, The Netherlands

Abstract body

Introduction

Abdominal aortic aneurysms (AAA) are large dilatations of the abdominal aorta, that are typically asymptomatic until a life-threatening rupture occurs. Knowledge of AAA geometry and local mechanical wall parameters using ultrasound is paramount for risk stratification and intervention planning. However, such an assessment is limited by the lateral lumen-wall contrast and resolution of conventional ultrasound. We therefore introduce multi-aperture bistatic imaging, a new imaging concept, to improve abdominal ultrasound. Here, two curved array transducers scan the aorta from different directions while both probes receive simultaneously on each transmit event.

Aims and Methods

The advantage of multi-aperture ultrasound was at first investigated in simulations and in an experimental study on ex vivo porcine aortas. Moving towards in vivo application, multi-aperture imaging can be hampered by aberrations. Therefore, an algorithm was developed to reconstruct images based on the underlying speed-of-sound distribution. Finally, the performance of multi-aperture bistatic imaging of the abdominal aorta is assessed in healthy volunteers (N = 20).

Results

Using dual-transducer ultrasound, a larger part of the vessel circumference can be visualized (+200%), yielding more accurate strain results (+15dB). Successful multi-aperture imaging was shown in the presence of aberration, yielding an excellent alignment of image features and an 80% reduction in position error. The in vivo results show both the feasibility and promise of multi-aperture ultrasound. The lumen-wall contrast-to-noise ratio is increased by 5dB. Strain improves by 9dB, revealing more accurate and homogeneous data compared to conventional ultrasound (Fig. 1).

Conclusion

Multi-aperture ultrasound imaging can provide the clinician with vital information about the mechanical state of AAAs. Our future vision is the use of this concept while imaging the abdomen with a large, flexible transducer. Ongoing work focuses on the clinical application of multi-aperture acquisition, using probe holders that will allow the simultaneous use of multiple probes by the operator, and 3-D multi-aperture imaging.

References

-

INFARCTION OF REGENERATIVE NODULES IN LIVER CIRRHOSIS AFTER IMPLANTATION OF TRANSJUGULAR INTRAHEPATIC PORTOSYSTEMIC SHUNT (TIPS)

***Fleur Sophie Gittinger*¹, Tino Wieczorek¹, Ingolf Schiefke¹**

1. Klinikum St. Georg Leipzig, Department of Gastroenterology and Hepatology,
Delitzscher Str. 141, 04129 Leipzig, Germany

Abstract body

Background: Infarction of regenerative nodules (RN) in liver cirrhosis has been reported after hypovolemic shock after variceal bleeding or septicemia. Presenting as hypoattenuating lesions on CT scans and necrotic tissue in histology, infarcted RN can appear as single or multiple lesions and might be mistaken for HCC.

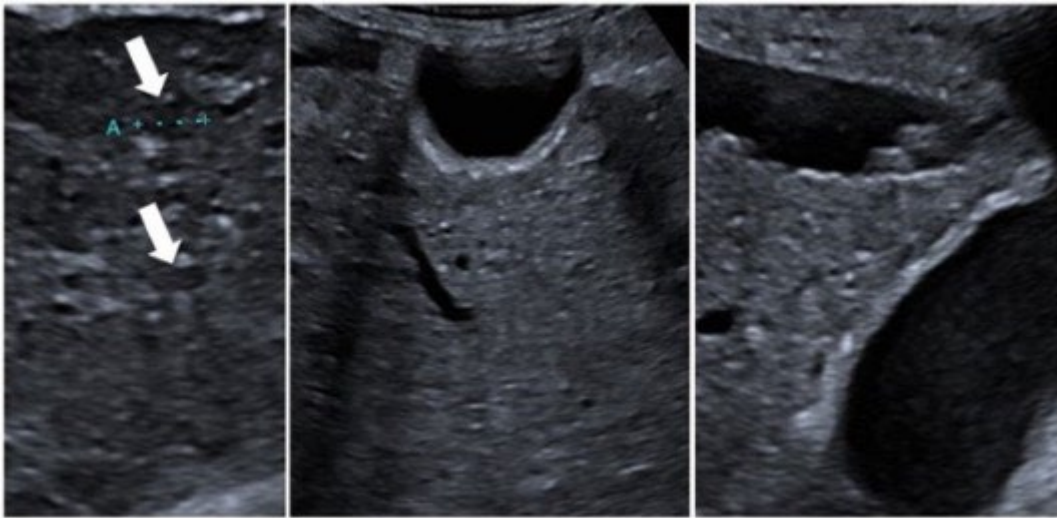
Case report: A 70-year-old patient with alcohol-related liver cirrhosis Child B and refractory ascites was planned for TIPS placement. An ultrasound and doppler ultrasound prior to TIPS showed regenerative nodules <1cm and hepatopetal flow in all portal veins, a CT scan ruled out malignant lesions. TIPS placement was performed without any complications, blood pressure remained stable at all times and portal pressure gradient was reduced from 24 to 3mmHg. The first ultrasound after placement showed multiple round, hypoechogenic lesions up to 17mm in the liver without vascularization on CEUS and hypoattenuation on a CT scan; initially, there was no flow in both intrahepatic portal veins visible on doppler ultrasound, but CEUS excluded thrombosis. Following placement only transaminases and bilirubin levels increased, but quickly normalized. Within two weeks ascites production decreased and doppler ultrasound showed signs of TIPS patency with increased hepatofugal intrahepatic portalvenous flow. Unfortunately, death occurred within one month after TIPS.

Conclusions: Placement of TIPS leads to a decrease of portal venous and compensatory increase of arterial blood supply in the liver. Infarction of RN has been described after systemic hypovolemic shock. In this case, no hypovolemia had occurred but changes in intrahepatic blood supply probably led to infarction of RN.

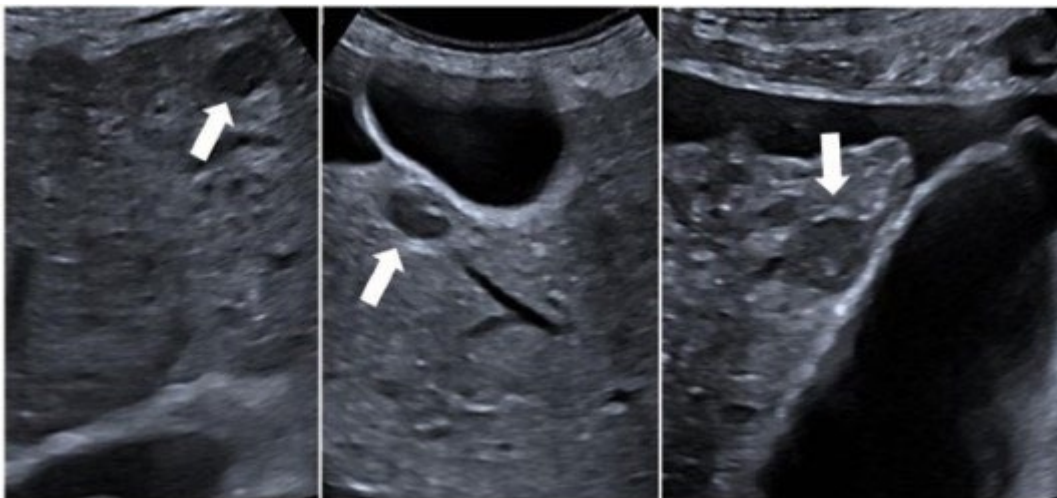
References

.

INFARCTION OF REGENERATIVE NODULES IN LIVER CIRRHOSIS AFTER IMPLANTATION OF TRANSJUGULAR INTRAHEPATIC PORTOSYSTEMIC SHUNT (TIPS)

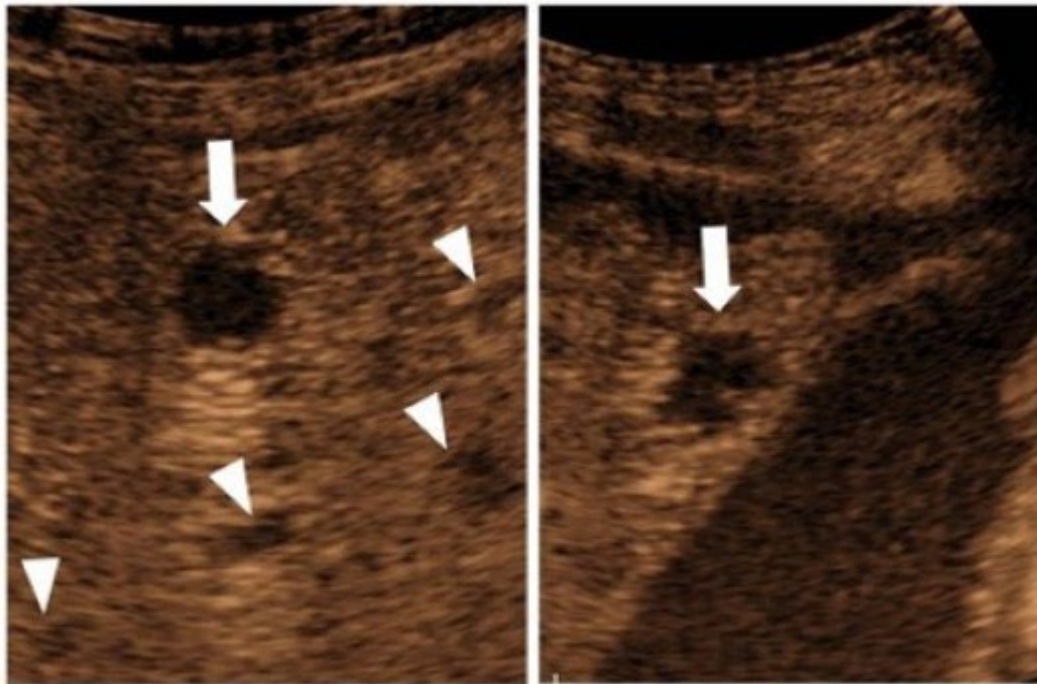


Liver before TIPS with small regenerative nodules (arrows).



Liver after TIPS with necrotic regenerative nodules (arrows).

INFARCTION OF REGENERATIVE NODULES IN LIVER CIRRHOSIS AFTER IMPLANTATION OF TRANSJUGULAR INTRAHEPATIC PORTOSYSTEMIC SHUNT (TIPS)



CEUS liver with necrotic regenerative nodules (arrows and arrow heads).

BEYOND LOCALIZATION OF PARATHYROID: CEUS AS GATEWAY TO MORPHOLOGY

Sergejs Pavlovics¹, Maija Radzina², Rita Niciporuka³, Madara Ratniece⁴, Madara Mikelsone⁵, Mara Liepa⁶, Peteris Prieditis⁶, Arturs Ozolins³, Zenons Narbutis³

1. Radiology Research Laboratory, Riga Stradins University, LV-1007 Riga, Latvia. 2. Diagnostic Radiology Institute, Pauls Stradins Clinical University Hospital, LV-1002 Riga, Latvia. 3. Radiology Research Laboratory, Riga Stradins University, LV-1007 Riga, Latvia. Diagnostic Radiology Institute, Pauls Stradins Clinical University Hospital, LV-1002 Riga, Latvia. Faculty of Medicine, University of Latvia, LV-1586 Riga, Latvia. 4. Department of Surgery, Riga Stradins University, LV-1007 Riga, Latvia. Department of Surgery, Pauls Stradins Clinical University Hospital, LV-1002 Riga, Latvia. 5. Radiology Research Laboratory, Riga Stradins University, LV-1007 Riga, Latvia. 6. Faculty of Medicine, Riga Stradins University, LV-1007 Riga, Latvia. 5. Department of Statistics, Riga Stradins University, LV-1007 Riga, Latvia. 6. Radiology Research Laboratory, Riga Stradins University, LV-1007 Riga, Latvia. 2. Diagnostic Radiology Institute, Pauls Stradins Clinical University Hospital, LV-1002 Riga, Latvia

Abstract body

Introduction

Differentiating between parathyroid lesions may be challenging on B-mode ultrasound (US). The aim was to evaluate the findings of contrast-enhanced ultrasound (CEUS) in hyperplastic and neoplastic parathyroid lesions.

Aims and Methods

Prospective study included 88 patients (18-83 years, F:M=74:14) with hyperparathyroidism scheduled for parathyroidectomy. Multiparametric ultrasound - US, Color Doppler, Superb Microvascular Imaging (SMI), CEUS (SonoVue 1ml vs. 2ml) images obtained and quantitative postprocessing performed (VueBox). Results compared with postoperative morphology.

Results

Most characteristic US features of parathyroid adenoma (PA) vs hyperplasia (PH) were: hypoechoic, well defined lesions with central increased echogenicity (67% and 52%, respectively), cystic inclusions (54% and 59%, respectively) with feeding vessel (93% for both), PA's were larger on average ($p=0.001$). CEUS showed peripheral hypervascularity in early arterial phase (median=10s), quickly reaching peak contrast concentration (median=15s), following early washout (median=27s) in PA and homogenous enhancement dynamics in PH with rapid washout ($p=0.001$). The most common histological subtype of adenoma was chief-cell adenoma (79%, $n=59$). Number of adenomas (61% of oxyphil subtype) presented with different pattern - predominantly central enhancement. CEUS sensitivity for parathyroid pathology prior to postprocessing vs after postprocessing -90% vs 98.2% and specificity 72.2% vs 85.3%, regardless the quantity of contrast media used ($p=0.1$).

Conclusion

CEUS showed high sensitivity and specificity in differentiation of parathyroid lesions, including subtypes of adenoma – majority of those are characterized by peripheral uptake, central washout and slower hemodynamics, compared to hyperplasia with homogeneous enhancement and rapid washout, whereas oxyphil adenomas showed predominantly central enhancement, therefore CEUS can be considered as a valuable patient selection tool prior surgery.

References

-

FOCUSED LUNG ULTRASOUND FOR IN-HOME ASSESSMENT OF OLDER ADULTS; A PILOT AND FEASIBILITY STUDY

Siri Aas Smedemark¹, Falster C², Laursen CB², Jarbøl DE³, Rosenvinge FS⁴, Andersen-Ranberg K¹

1. Dept. of Geriatric Medicine, Odense University Hospital. Dept. of Clinical Research, University of Southern Denmark, 2. Dept. of Clinical Research, University of Southern Denmark. Dept. of Respiratory Medicine, Odense University Hospital, 3. Research Unit of General Practice, Dept. of Public Health, University of Southern Denmark, 4. Dept. of Clinical Microbiology, Odense University Hospital Research Unit of Clinical Microbiology, University of Southern Denmark

Abstract body

Introduction

Delayed recognition of disease among older adults can hinder timely management and increase the risk of hospital admission.

Focused Lung Ultrasound (FLUS) carried out in the older patient's home may support clinical decision-making when acute respiratory disease is suspected. The aim of this study was to investigate if FLUS is feasible in patients' home and whether it has a potential clinical impact

Aims and Methods

The study was carried out from September 2021 to November 2021 in Kolding Municipality, Denmark. A FLUS trained physician accompanied an acute community nurse (ACN) when visiting citizens aged 65+y with acute respiratory symptoms referred for an in-home acute health assessment. The ACN carried out a clinical assessment and gave a presumptive diagnosis. FLUS was performed by the physician using a handheld device (Philips Lumify®, C5-2 curved array transducer) and followed a standardized 14 scanning zone protocol using predefined questions regarding pneumothorax, pleural effusion, interstitial syndrome, pneumonia, and other obvious pathology. Clinical impact was measured by comparing ACNs presumptive diagnoses to FLUS findings to see whether FLUS identified missed diagnoses and conditions.

Results

One hundred consecutive individuals, referred for an ACN assessment, were included. The average age was 81.6 (SD±8.4). FLUS was performed in 100%, and detected less than three patients with pneumothorax, 32 patients with pleural effusions (six of which were moderate to large), eight patients with interstitial syndromes, 24 patients with pneumonia, and 16 patients with other pathologies. ACNs presumptive diagnoses compared to FLUS findings showed that FLUS identified 21 patients with a condition in need of treatment that was not identified in the presumptive diagnoses.

Conclusion

In-home assessment of older adults with FLUS is highly feasible, and holds a potential for an earlier clinical intervention, as FLUS helps identifying clinical important conditions in need of treatment, otherwise missed by ACNs.

References

-

SONOGRAPHIC ASSESSMENT OF THE TRANSPLANTATION-RELATED COMPLICATIONS IN RENAL GRAFT RECIPIENTS

Maryla Kuczyńska¹, Anna Drelich-Zbroja¹, Michał Sojka¹, Tomasz Jargiełło¹

1. Department of Interventional Radiology and Neuroradiology,
Medical University of Lublin, Lublin, Poland

Abstract body

Introduction

Kidney transplantation remains the most effective method of renal replacement therapy, in which the graft is able to take over all the functions of the healthy organ. About 1000 cadaver kidney transplantations are performed in Poland each year. Graft function should be regularly assessed following the transplantation, both in laboratory tests and imaging examinations to identify possible complications of the surgical procedure or early signs of the graft rejection. Nonetheless, some patients still require biopsy with pathologic evaluation of the specimen, in order to identify the pathology that leads to function deterioration of the graft.

Aims and Methods

A retrospective evaluation of the US examinations in 489 patients following renal graft biopsy was performed to assess the incidence, and type of the procedure-related complications. All ultrasound examinations were performed using Logiq 7 and 9 (GE Healthcare, 4C and 12L probes) by the same protocol, including B-mode, color and spectral Doppler analysis of the graft.

Results

Peritransplant collections were diagnosed in 146/489 subjects. Vascular complications occurred in 14 patients (2.8%) and mostly affected the arterial renal system. There were diagnosed: 9 stenoses (including one case of stenosis of each of the double renal arteries), 1 occlusion, 1 thrombosis of transplant renal artery and 1 external iliac artery dissection distal to the site of anastomosis. Venous thrombosis developed in 2 patients. Post-biopsy complications were detected in 9 cases: 6 arteriovenous fistulae and 3 haematomas. One patient required endovascular embolization of the bleeding vessel. No cases of posttransplant lymphoproliferative disorder were detected in the study cohort.

Conclusion

Renal transplantation and graft biopsy bear a relatively low, but significant risk of peri-procedural complications. Ultrasound examination is an effective method of identifying both the surgical technique-related and vascular complications, enabling qualification for further surgical or endovascular treatment.

References

-

AUTO POINT SHEAR WAVE ELASTOGRAPHY AND ULTRASOUND DERIVED FAT FRACTION: ARE THEY PROMISING TOOLS TO DETECT LIVER FIBROSIS AND STEATOSIS

***Isabel Garrido*¹, Rosa Coelho¹, Guilherme Macedo¹**

1. Serviço de Gastrenterologia, Centro Hospitalar Universitário de São João, Porto, Portugal

Abstract body

Introduction

Auto Point Shear Wave Elastography (auto-pSWE) is a new liver stiffness quantification tool designed to reduce liver elastography exam time. Ultrasound Derived Fat Fraction (UDFF) is a new measurement tool to assess hepatic steatosis. The aim of the study was to assess the diagnostic accuracy of conventional pSWE, auto-pSWE and UDFF.

Aims and Methods

Patients with chronic liver disease who had already performed liver biopsy were consecutively recruited from our outpatient department to participate in this cross-sectional study. Conventional pSWE (obtaining 10 measurements through 10 acquisitions), auto-pSWE (automatically obtaining 15 measurements by a single acquisition), and UDFF (one measurement obtained by one acquisition) of the liver were performed in March 2022.

Results

A total of 44 patients were included, the majority female (56.8%), with a median age of 56 years old (IQR 46-61). The Pearson correlation coefficient between UDFF and histologic steatosis was 0.584 ($p < 0.001$). The UDFF identified patients with a higher probability of having histologic steatosis: the area under the receiver operating characteristic curve (AUROC) values for diagnosing steatosis >grade 0 was 0.768 (95%CI 0.593-0.943, $p = 0.014$), for steatosis >grade 1 was 0.842 (95%CI 0.719-0.965, $p < 0.001$) and for steatosis >grade 2 was 0.844 (95%CI 0.727-0.961, $p = 0.001$). The difference between conventional pSWE and auto-pSWE methods was not significant ($p = 0.165$). The AUROCs for diagnosing fibrosis stage >1, >2 and >3 was 0.782 (95%CI 0.643-0.921, $p = 0.003$), 0.817 (95%CI 0.654-0.979, $p = 0.014$) and 0.864 (95%CI 0.686-1.000, $p = 0.038$) for pSWE and 0.816 (95%CI 0.676-0.956, $p = 0.001$), 0.842 (95%CI 0.647-1.000, $p = 0.005$) and 0.747 (95%CI 0.428-1.000, $p = 0.109$) for auto-pSWE, respectively.

Conclusion

UDFF tool provides a simple, non-invasive and low-cost tool for quantifying the hepatic fat fraction with a high degree of agreement with histologic biopsy. The auto-pSWE has equal accuracy as conventional pSWE in measuring liver stiffness, with the advantage of time effectiveness.

References

-

LIVER STEATOSIS ASSESSMENT BY NEW ULTRASOUND-BASED QUANTITATIVE METHODS

Camelia Foncea¹, Alina Popescu¹, Raluca Lupusoru², Cotrau Radu¹, Adrian Burdan¹, Ariana Pascu¹, Tudor Moga¹, Roxana Sirli¹, Ioan Sporea¹

1. Department of Gastroenterology and Hepatology, Department of Internal Medicine II, Center for Advanced Research in Gastroenterology and Hepatology "Victor Babes" University of Medicine and Pharmacy Timisoara, Center for Advanced Hepatology Research of the Academy of Medical Sciences, Timisoara,

2. Department of Gastroenterology and Hepatology, Department of Internal Medicine II, Center for Advanced Research in Gastroenterology and Hepatology "Victor Babes" University of Medicine and Pharmacy Timisoara. Center for Advanced Hepatology Research of the Academy of Medical Sciences, Timisoara.

Center for Modeling Biological Systems and Data Analysis, Department of Functional Sciences, "Victor Babes" University of Medicine and Pharmacy Timisoara, Romania

Abstract body

Aims

The aim of this study was to evaluate and to establish cut-off values for two new quantitative ultrasound (QUS) parameters, TSI (tissue scatter-distribution imaging) and TAI (tissue attenuation imaging) in early diagnosis of liver steatosis (LS), as compared to controlled attenuation parameter (CAP).

Methods

A prospective study was conducted in which LS was assessed in the same session by QUS (Samsung Medison RS85, CA1-7A probe) and CAP (FibroScan Compact M530, M/XL probes). Reliable measurements were defined for CAP the median value of 10 measurements with IQR/M<0.3, and for QUS, five consecutive measurements of TAI and TSI acquired by a color-coded map. TAI and TSI were automatically calculated and considered reliable when reliability index, R2>0.6. The CAP cut-off value used for the whole cohort for at least mild steatosis (S1) were 248 dB/m [1]; for ALD (alcoholic liver disease) cohort, 268 dB/mm[2]; for NAFLD (non-alcoholic liver disease) cohort 294dB/m [2]. Demographic and health related data were recorded

Results

A total of 285 patients, with a mean age of 56.1±12.4, 114 female and 171 male, were included in the study. According to aetiology, 164 (57.5%) patients had NAFLD, 61(21.4%) ALD, and 60 (21.1%) were other etiologies (viral, cardiac, autoimmune). The obtained TSI and TAI cut-off values for the diagnosis of at least mild steatosis (S1) are presented in Table 1.

Table 1. Cut-off values of TAI and TSI for S1

Variable Overall NAFLD ALD TSI

S1 >96.2

AUC=0.74, p<0.0001, Se=87.9%, Sp=53.0%; >96.5

AUC=0.73, p<0.0001, Se=90.9%, Sp=47.9%; >94.9

AUC=0.70, p=0.003 Se=72.9%, Sp=75.0%; TAI S1

>0.73

AUC=0.82, p<0.0001, Se=78.3%, Sp=71.6%; >0.75

AUC=0.81, $p<0.0001$, Se=57.5%, Sp=90.8%; $v>0.66$

AUC=0.74, $p<0.0001$, Se=84.8%, Sp=57.1%;

There were no differences between the performance of TAI and TSI according to the DeLong test, $p=0.18$ and $p=0.24$. A strong direct correlation was observed between TAI and CAP $r=0.701$, moderate between TSI and CAP $r=0.56$ for the all cohort, but for NAFLD and ALD subgroups moderate correlations were found between TAI and CAP $r=0.66$, and $r=0.66$ respectively and TSI and CAP $r=0.56$ and 0.66 , respectively.

In univariate regression analysis, the factors associated with TSI were hypertension, Diabetes mellitus (DM), and obesity, and all p -values were <0.0001 , but in multivariate analysis, only hypertension($p=0.001$) and obesity($p=0.0005$) were associated. For TAI, in univariate analysis, the same factors: hypertension($p=0.004$), obesity($p=0.0006$) and DM ($p=0.002$) were associated, but in multivariate analysis, DM was the only factor associated, $p=0.02$. Age and gender were not correlated with any method, TSI or TAI.

Conclusion

TAI and TSI are feasible non-invasive methods for screening and diagnosis LS, with good accuracy. Patients with NAFLD presented highest cut-off values, probably by the presence of DM and obesity, conditions independently associated with TAI and TSI values.

References

1. Karlas T, Petroff D, Sasso M, Fan JG, Mi YQ, de Lédinghen V et al. Individual patient data meta-analysis of controlled attenuation parameter (CAP) technology for assessing steatosis. *J Hepatol*. 2017 May;66(5):1022-1030.

ABERRANT RIGHT SUBCLAVIAN ARTERY SHOULD NOT BE USED AS A SURROGATE MARKER FOR ANEUPLOIDY AFTER A NORMAL FIRST TRIMESTER

Marianna Chatzioannou¹

1. Alexandra Maternity Hospital, Athens University

Abstract body

Aims

Aberrant right subclavian artery (ARSA) is a relatively rare ultrasonographic marker that has been associated with Down's syndrome and 22q11.2 deletion. Its predictive accuracy, however, remains arbitrary as published cohorts do not present comparable findings. The purpose of the present cohort study is to present the experience of our hospital.

Methods

We screened 5,933 pregnancies that performed their antenatal screening in our hospital between 2015-2019. Cases that were identified with ARSA were offered amniocentesis during the second trimester of pregnancy and fetal karyotype was assessed. In all cases molecular karyotyping was performed. Maternal age, as well as gestational age at delivery were also recorded. Descriptive statistics were evaluated using the Microsoft Excel. Only cases with low-risk first trimester screening result ($<1:1000$) were included in the study.

Results

Overall, we identified 84 ARSA cases that did not present other ultrasonographic markers (major or minor) that could predict fetal aneuploidy. Amniocentesis was offered in all of them during the second trimester of pregnancy (median week 22, range 21-24). Fetal karyotype was normal in all cases. Neonatal anomalies were not detected and all cases delivered a healthy neonate at a median gestational age of 38 weeks (range 32-41 weeks).

Conclusion

Aberrant right subclavian artery without additional ultrasonographic findings should not be considered a predictive factor of fetal aneuploidies in women with a normal first trimester screening; hence, routine invasive screening should not be offered in cases without additional risk factors.

References

-

SONOTEAM – STUDENT NETWORKING FOR BETTER ULTRASOUND SKILLS

Monika Zbroja¹, **Weronika Mielnik**¹, **Maryla Kuczyńska**², **Anna Drelich-Zbroja**²

1. Students' Scientific Society at the Department of Interventional Radiology and Neuroradiology, Medical University of Lublin, 2. Department of Interventional Radiology and Neuroradiology, Medical University of Lublin

Abstract body

Learning objectives

SonoTEAM is an initiative bringing together students of the academic community focused on acquiring practical skills in ultrasonography, known as the “Stethoscope of the 21st century”.

Background

It is a proposal to create a learning grid aimed at real involvement of students in the educational process. Project supervisors will train a group of student-trainers, who will then conduct further courses for the academic community. Ultimately, it is planned to expand the described model of classes to all academic centers in the country through promotional activities. As a part of the pilot project, it is planned to train the first 100 student-trainers with the possibility of funding the participation of the above students in commercial ultrasound courses, in order to diversify the educational process and to initiate the first series of training courses on the basics of ultrasound organized by student-trainers for the academic community (about 1,000 people).

Findings

Student-trainer will acquire theoretical and practical skills based on a curriculum consisting of several basic modules (as proposed by EFSUMB committee on education).

Conclusions

The SonoTEAM initiative creates favorable conditions for the promotion of academics on the international arena, on the one hand by inviting foreign guests to share their knowledge in lectures and meetings, but also by presenting the project and its results during scientific meetings on the European and worldwide arena. Supervisors will also ensure that student-trainers participate as co-organizers/trainers in practical workshops for students and young doctors, accompanying National as well as European radiological events.

References

not applicable

IDENTIFYING ADVANTAGES AND DISADVANTAGES IN ULTRASOUND TRAINING OF STUDENTS IN GERMANY

Nils Daum¹, Sophie-Luise Saenger², Tino Hofmann³, Christoph F. Dietrich⁴

1. Charité–Universitätsmedizin Berlin, corporate member of Freie Universität Berlin and Humboldt Universität zu Berlin, Germany, 2. Technische Universität Dresden, Faculty of Medicine Carl Gustav Carus, Fetscherstr. 74, 01307 Dresden, Germany, 3. University Witten/Herdecke – Department of General Medicine I and Interprofessional Care, Alfred-Herrhausen-Str. 50, 58455 Witten, Germany, 4. Kliniken Hirslanden Beau Site, Salem und Permanence, Allgemeine Innere Medizin (DAIM) Kliniken Beau Site, Salem und Permanence

Abstract body

Actuality and Aim

Ultrasound teaching in medical student education is delivered in varied ways in German Universities.

As there is currently no standardized curriculum for student ultrasound teaching in Germany, our study addresses key topics that should be represented and their advantages and disadvantages.

Methods

Through several consensus conferences between us and students and teachers from universities around the world, we identified relevant topics that should be represented in a model curriculum. These were divided into advantages and disadvantages on the basis of previously published data and expert opinions. Through a collaborative decision-making process, we declared relevant key themes [1]. These will be critically evaluated in a further process in terms of advantages and disadvantages based on the scientific literature and expert opinions.

Results

We identified 4 levels of university contacts to include into the process: Dean's office, the supervisory department for ultrasound teaching and/or the Skillslab, responsible persons for didactics and the student tutors. Teaching materials, basic conditions, the relation between theory and practice were defined as well as preclinical and clinical parts of undergraduate education in ultrasound and Learning Objectives Tests.

Conclusion

We were able to define some key topics which will be further evaluated based on their advantages and disadvantages presented in previously published literature.

References

Dietrich CF, et al. Medical Student Ultrasound Education: A WFUMB Position Paper. *Ultrasound in Medicine and Biology*. 2019;45(2):271-81 Doi:10.1016/j.ultrasmedbio.2018.09.017.

UNDERGRADUATE ULTRASOUND EDUCATION IN GERMANY – A STUDENTS' PERSPECTIVE

Sophie-Luise Saenger¹, Nils Daum², Tino Hofmann³, Gregor Barth⁴, Alexander Krutz⁴, Christoph F. Dietrich⁵

1. Technische Universität Dresden, Faculty of Medicine Carl Gustav Carus, Fetscherstr. 74, 01307 Dresden, Germany, 2. Charité–Universitätsmedizin Berlin, corporate member of Freie Universität Berlin and Humboldt Universität zu Berlin, 3. University Witten/Herdecke, Department of General Medicine I and Interprofessional Care, Alfred-Herrhausen-Str. 50, 58455 Witten, Germany, 4. Brandenburg Institute for Clinical Ultrasound (BICUS), Brandenburg Medical School (Theodor Fontane), Neuruppin, Germany, 5. Kliniken Hirslanden Beau Site, Salem und Permanence, Allgemeine Innere Medizin (DAIM) Kliniken Beau Site, Salem und Permanence

Abstract body

Introduction

Ultrasound teaching in undergraduate medical student education is accomplished very heterogeneously at the various universities within Germany.

What do students want from sonography teaching in German medical schools and what is their motivation for becoming student member in specialist ultrasound societies?

Methods

The student working group “AG Studierende in der Deutschen Gesellschaft für Ultraschall in der Medizin (DEGUM)” gathered students’ opinions from a variety of student tutors of different universities and skills labs within Germany. Student leaders were interviewed and views from the annual official working group meeting were collated with the views of student tutors for ultrasound and their student head of the skills lab.

Results

The most important issue identified was the need for uniform, standardized and quality-controlled contents of ultrasound into the basic curriculum. Ultrasound should be included in mandatory teaching in medical school and quality assured at national level [1]. Students think there should be a standard compendium for student education in ultrasound. The highest motivation for becoming member in specialist societies, such as DEGUM, apart from the proof of own qualification is gaining proper knowledge in ultrasound as well as interacting with experts.

Conclusion

Currently university faculties independently determine the content of their curriculum. Specialist societies should be making recommendations for a Universal Curriculum for undergraduate ultrasound education.

References

[1] Dietrich CF, et al. Medical Student Ultrasound Education: A WFUMB Position Paper. *Ultrasound in Medicine and Biology*. 2019;45(2):271-81 Doi:10.1016/j.ultrasmedbio.2018.09.017.

MOBILE OUTPATIENT ULTRASOUND DIAGNOSTICS (HHUS) IN SPECIALIZED OUTPATIENT PALLIATIVE CARE (SAPV) PERFORMED BY QUALIFIED NURSES

David Boten Boten¹, Hendra Lo², CHRISTIAN JENSSEN³, Dieter Nürnberg³, Nils Daum³

1. Brandenburg Medical University, Institut Clinical Ultrasound / BICUS Neuruppin, Germany,

2. Brandenburg Medical University, Institut Clinical Ultrasound / BICUS, Neuruppin,

3. Brandenburg Medical University, Institut Clinical Ultrasound / BICUS, Neuruppin, Germany

Abstract body

Actuality and Aim

The state of Brandenburg in Germany faces significant challenges in providing adequate medical care in the future, largely due to demographic changes. Non-physician users such as nurses have been shown to improve patient care in under-served regions by using handheld ultrasound (HHUS). In a previous pilot study (POCUS 1.0), it was demonstrated that nurses could use ultrasound during home visits to avoid unnecessary changes in therapy or patient trips to the doctor. The study aims to demonstrate the efficacy of training non-physicians in ultrasound for outdoor palliative care patient diagnosis.

Material and Methods

The objective of the POCUS 2.0 study is to create an effective ultrasound curriculum for nurses and to investigate the impact of HHUS on patient management. The study involves 16 palliative nurses from 4 ambulant services and 2 hospices who receive 3 days of structured ultrasound training and are supervised by tutors. Results are validated by experts and tele-teaching is used to review the training and results.

References

1. Ministerium für Umwelt GuV. Künftige Sicherstellung der gesundheitlichen Versorgung in Brandenburg Grundlagen, Handlungsfelder und Maßnahmen/ Version 2012.
2. Wagner M, Shen-Wagner J, Zhang KX, Flynn T, Bergman K. Point-of-Care Ultrasound Applications in the Outpatient Clinic. South Med J. 2018;111(7):404-10.
3. Adler D, Mgalula K, Price D, Taylor O. Introduction of a portable ultrasound unit into the health services of the Lugufu refugee camp, Kigoma District, Tanzania. International Journal of Emergency Medicine. 2008;1(4):261-6.

IMPLEMENTATION OF A NATIONAL REGISTER FOR INTERVENTIONAL ULTRASOUND (INVUS) IN GERMANY

**Nils Daum¹, Dominik Antonius Seckinger¹, Constantin Remus¹,
Dieter Nürnberg¹, Christian Jenssen², Nicole Eder²**

1. Brandenburg Institute for Clinical Ultrasound (BICUS), Medical University Brandenburg "Theodor Fontane", Faculty of Health Sciences, Neuruppin, Germany, 2. Krankenhaus Märkisch-Oderland, Department of Internal Medicine, Strausberg/Wriezen, Germany

Abstract body

Aim

Interventional ultrasound (INVUS) has become an essential part of daily clinical practice due to many advantages over other procedures (1,2). However, the current state of research on risk factors and adverse events is mostly based on monocentric or retrospective studies that focus on specific interventions (1,3). The goal is the implementation of a prospective registry that aims at a comprehensive and comparative evaluation of the safety and efficacy of the different INVUS procedures.

Methods

In preparation for the INVUS register, a pilot study focused on abdominal procedures was currently being conducted at 9 study centers. In addition to patient-specific data, technical variables, risk factors, quality of outcomes, and adverse events are recorded in a web-based documentation system.

Results

A total of 934 ultrasound (US)-guided interventional procedures have been included in the pilot study. Following the successful implementation of an online abdominal mask for recording INVUS-related complications, additional data is now being collected for thoracic and vascular procedures. In addition to the expansion, the official registry will also be launched in the next quarter.

Conclusion

In the pilot phase, a first online-based mask for abdominal INVUS procedures was successfully implemented. Further on, new masks will be introduced and the official register study will be started.

References

1. Dietrich CF, Nuernberg D (Eds.). Interventional Ultrasound. Stuttgart, Thieme 2015.
2. Lorentzen T, et al. EFSUMB Guidelines on Interventional Ultrasound. *Ultraschall Med* 2015;36:E1-14.
3. Strobel D, et al. Incidence of bleeding in 8172 percutaneous ultrasound-guided intraabdominal diagnostic and therapeutic interventions. *Ultraschall Med* 2015;36:122-131.

THE INFLUENCE OF CARDIOVASCULAR CONCOMITANT DISEASES ON PLAQUE VULNERABILITY IN CEUS ASSESSMENT

***Marcin Czeczulewski*¹, Ewa Kopyto¹, Karolina Nieoczym¹,
Małgorzata Matuszek¹, Eryk Mikos¹, Maja Kopyto¹, Adam Czarnecki¹,
Karol Stępnia¹, Maryla Kuczyńska²**

1. Students Scientific Society at the Department of Interventional Radiology and Neuroradiology,
Medical University of Lublin, 2. Department of Interventional Radiology and Neuroradiology,
Medical University of Lublin

Abstract body

Actuality and Aim: Determining vulnerability is a challenge in atherosclerotic plaque imaging. The criterion for instability is the detection of neovascularisation in the plaque lipid core. The study aimed to investigate the influence of atherosclerosis risk factors on plaque vulnerability in CEUS assessment.

Material and methods: This prospective study was conducted on patients referred for carotid ultrasound examination. History of atherosclerosis risk factors was obtained from the patients. Inclusion criteria were echolucent atherosclerotic plaques (type 1-2 Grey-Weale scale) with a thickness of > 2.5 mm. 24 eligible plaques in 21 patients were identified and assessed for thickness, echogenicity, location and degree of stenosis. 1.5 ml of SonoVue contrast medium (Bracco, Italy) was administered intravenously and flushed with 10 ml of 0.9% saline. As contrast appeared in the carotid artery, the plaque was examined for contrast enhancement.

Results: The average thickness of the plaques was 28.2 mm. Of the plaques examined, 10 were uniformly echolucent and 14 were predominantly echolucent. The plaques were located in the common carotid artery (14) and the internal carotid artery (10). No contrast enhancement was detected in 6 plaques, mild enhancement in 14 and marked enhancement in 4. Of the patients, 13 had hypertension, 4 had ischaemic heart disease, 4 had diabetes and 7 used tobacco. There were no statistically significant associations between atherosclerosis risk factors and plaque contrast enhancement ($p > 0.05$).

Conclusions: CEUS provides valuable information on atherosclerotic plaque vulnerability. However, the influence of concomitant disease on plaque CEUS characteristics was not found.

References

NA

PITFALLS IN ADPKD COMPLICATIONS - CYST HEMORRHAGE DIAGNOSED WITH CEUS

Elvira-Ioana Buda¹, Cristian Chirilă¹, Ana Elena Cadar¹, Smaranda Ioana Codreanu¹, Mirela Liana Gliga¹

1. George Emil Palade University of Medicine, Pharmacy, Science, and Technology of Targu Mures

Abstract body

Background:

Autosomal dominant polycystic kidney disease (ADPKD) is the most frequent genetic nephropathy characterized by kidney cysts formation and extra-renal manifestations. There are several cyst complications that can impair the patient's quality of life.

Case report:

We present the case of a 62-year-old male patient, with maternal inherited ADPKD, diagnosed in 2007, using the modified Pei-Ravine criteria. He presented at the Nephrology Department of the Mures County Hospital accusing pain in the left lumbar region. The patient is known with multiple comorbidities such as chronic kidney disease stage III, type II diabetes, secondary hypertension, and ischemic cardiomyopathy.

Regarding the lab result, the urine test highlighted the presence of proteinuria and the urea and creatinine revealed an impaired kidney function (eGFR: 42 ml/min/1,73m²).

The ultrasound described an intense inhomogeneous cyst with echogenic material within. Given that the clinical and paraclinical investigations did not find any signs of infection or cyst rupture, contrast-enhanced ultrasound (CEUS) was performed in order to make the final diagnosis and exclude malignancy. After a bolus injection of 1,8 ml of SonoVue, no enhancement was detected during the entire examination. Therefore, we concluded that an intracystic organized hematoma was present. The patient was re-evaluated after 3 months and the intracystic lesion disappeared.

Conclusions:

Abdominal CEUS can eliminate the need of performing more elaborate and nephrotoxic tests in the case of complicated cysts in ADPKD patients with kidney failure, where exposure to iodinated contrast or gadolinium is not an option.

Acknowledgements:

I have nothing to acknowledge.

References

None

IOTA METHODS TO DISTINGUISH BETWEEN BENIGN AND MALIGN ADNEXAL LESIONS DISCOVERED BY ULTRASONOGRAPHY

Andreea Puiu¹

1. State University of Medicine and Pharmacy "Nicolae Testemitanu"

Abstract body

Actuality: Ultrasound diagnosis of ovarian malignancy is mainly subjective and diagnostic performance depends on the examiner's experience. Ultrasound-based diagnostic models are developed to assist clinicians with different levels of training and expertise to distinguish between benign and malignant ovarian tumors.

Aim: To evaluate the diagnostic performance of IOTA Simple Descriptors, Simple Rules and ADNEX model used by a beginner examiner to discriminate benign and malignant ovarian lesions.

Material and methods: This is a retrospective review of stored images of 192 women with adnexal lesions, including 77 (40.10%) malignant and 115 (55.90%) benign lesions. Assessment was performed by an unexperienced examiner, but familiar with the IOTA terms, descriptors and methods of malignancy risk estimation. The presumptive diagnosis of ovarian malignancy was determined by subjective Simple Descriptors and Simple Rules; and computer-assisted ADNEX model. Only ultrasound features were evaluated, without considering serum CA125 values. The examiner's findings were compared with the histology of surgically managed tumors or expert's opinion in the case of lesion follow-up.

Results: For differentiation benign and malignant tumors ADNEX model had 76.72% SE, 94.78% SP, 90.77% PPV and 85.83% NPV. Simple Descriptors could be applied in 81 (42.19%) lesions, with 80% SE, 98.59% SP, 88.89% PPV and 97.22% NPV. Simple Rules could be applied in 161 (83.85%) cases, with 53.45% SE, 97.09% SP, 91.18% PPV and 78.74% NPV.

Conclusions: Even used by beginner, IOTA ADNEX model has a good accuracy in benign and malignant differentiation. All methods provided high specificity in malignancy exclusion, allowing accurate benign tumors detection.

References

1

GALLBLADDER POLYP - ULTRASOUND DIAGNOSIS AND MANAGEMENT

***Danielius Nepomniščis*¹, *Raminta Lukšaitė-Lukštė*¹**

1. Vilnius University Faculty of Medicine

Abstract body

Learning objectives: Describe the morphological characteristics of a gallbladder polyp: size, growth rate, shape, echogenicity, vascularity, and the patient's additional risk factors to differentiate non-neoplastic from neoplastic polyps. Evaluate the microvascular pattern of non-neoplastic and neoplastic gallbladder polyps using contrast-enhanced ultrasound. Use this knowledge to recommend subsequent follow-up intervals or surgical treatment necessity.

Background: Gallbladder polyps are common incidental findings during abdominal ultrasound examination. In the general population, the incidence of polyps is 3-6%. Generally, gallbladder polyps are non-neoplastic cholesterol polyps. Only 6% of malignant gallbladder tumours have been reported to be of polypoid origin, the vast majority deriving from flat dysplastic epithelium. Abdominal ultrasound to group polyps into 3 risk groups: extremely low, low, and intermediate risk, which allows the best decision to be made in the treatment or follow-up of this rare but lethal pathology.

Findings: Gallbladder polyps up to 10 mm have a very low chance of becoming malignant, but those larger than 15 mm require surgical treatment in any case. During the follow-up examination a polyp growth of more than 4 mm is considered an unnatural rapid growth for non-neoplastic lesion. Only focal wall thickening, and shape of polyp influence the risk group. The echogenicity, vascularity and number of polyps has no effect on risk stratification. A 3-year follow-up is sufficient to detect neoplastic polyp.

Conclusions: Polyp size, growth rate, shape and focal wall thickening are key findings in abdominal ultrasound to make a clinical decision for follow-up frequency or surgical treatment.

References

-

BASICS OF KNEE ULTRASOUND EXAMINATION AND INTERESTING CASES FROM RESIDENTIAL EXPERIENCE

Monika Mikeliene¹

1. Vilnius University Hospital Santaros Klinikos

Abstract body

LEARNING OBJECTIVES

To review the anatomy relevant to the ultrasound examination of the knee and to present several illustrative cases.

BACKGROUND

Knee is a complex joint, usually examined using cross-sectional imaging modalities such as CT and MRI. Nevertheless, ultrasound is an often-overlooked modality that is inexpensive, time-efficient and safe method for assessing superficial structures of the knee as well as joint effusion.

FINDINGS

Structures of the knee that can be evaluated by ultrasound are divided into four main compartments: anterior (suprapatellar recess, synovium, quadriceps tendon, patella, patellar tendon and patellar retinacula), medial (medial collateral ligament, outer border of the medial meniscus), lateral (lateral collateral ligament, outer border of the lateral meniscus) and posterior (gastrocnemius-semimembranosus bursa).

CONCLUSIONS

Knee ultrasound can be used as an initial modality and may serve as an efficient substitute in trained hands.

ACKNOWLEDGEMENTS

Special thanks to Aurelija Domarkienė for the assistance.

References

-

FROM MOUTH TO ANUS – ULTRASOUND AS THE LEADING IMAGING MODALITY IN THE PEDIATRIC CLINICAL SETTING

**Monika Zbroja¹, Weronika Mielnik¹, Olga Pustelniak¹, Katarzyna Drelich¹,
Julia Budzyńska¹, Magdalena Leśniewska¹, Ilona Koziół¹,
Agnieszka Brodzisz², Magdalena Woźniak²**

1. Students' Scientific Society at the Department of Pediatric Radiology, Medical University of Lublin,
2. Department of Pediatric Radiology, Medical University of Lublin

Abstract body

Actuality and Aim

Acute abdomen is a condition that occurs unexpectedly and progresses rapidly. The aim of study is to show the importance of ultrasound in diagnostics of acute abdomen.

Materials and Methods

The study enrolled 312 patients (3 weeks - 18 years) with acute abdominal pain for whom US was performed. Patients were divided into four groups:

- (a) 189 - appendicitis susp.
- (b) 63 - pylorostenosis susp.
- (c) 49 - inflammatory bowel disease susp.
- 11 - intestinal intussusception susp.

Results

Group (a): of 79 patients with US image of appendicitis, 52 underwent surgery - the diagnosis was confirmed histopathologically in all cases. In 27 subjects US failed to visualize the appendix; no further diagnostic workup or intervention was required.

52 patients from group (b) were qualified for surgery based on US images and clinical symptoms, and the diagnosis was confirmed intraoperatively.

In 36 patients of group (c) US images indicated active Crohn's disease, while in 4 patients - ulcerative colitis. The findings were confirmed by MRE and histopathologically.

All patients in group (d) had US image consistent with intestinal intussusception. Severe wall thickening prompted the diagnosis of Burkitt lymphoma. Laboratory, bone marrow evaluation and MR/CT scans confirmed the diagnosis.

Conclusion

Children with abdominal complaints, have an abdominal US performed first. US is a reliable imaging modality in differential diagnosis of the acute abdomen; in our series, all US findings were later confirmed histopathologically or intraoperatively.

References

Pemmerl S, Hüfner A. The Acute Abdomen: Etiology and Clinical Presentation, doi: 10.1055/a-1007-4174.

THE USE OF ULTRASONOGRAPHY IN DIAGNOSIS OF THE MOST COMMON GASTROINTESTINAL TUMOR IN CHILDREN

**Weronika Mielnik¹, Monika Zbroja¹, Katarzyna Drelich¹, Olga Pustelniak¹,
Ilona Koziol¹, Julia Budzyńska¹, Magdalena Leśniewska¹, Agnieszka Brodzisz¹,
Magdalena Woźniak¹**

1. Students' Scientific Society at the Department of Pediatric Radiology, Medical University of Lublin

Abstract body

Actuality and Aim: Burkitt's lymphoma is the most malignant tumor of the lymphatic system. This tumor is most often diagnosed incidentally in children who have "acute abdominal" symptoms. The aim of the study was to assess the use of ultrasound in the diagnosis of Burkitt's lymphoma.

Material and Methods: The study involved 18 children (10 girls and 8 boys) aged over 5 years. Patients reported severe abdominal pain mainly located in the right iliac fossa. In all, ultrasound examination of the abdomen and gastrointestinal tract was performed using Siemens apparatus with a 3.5-5 MHz convex probe and L4 - 7.5 MHz linear probe.

Results: In all children ultrasound examination showed intussusception of the ileocecal region. All patients had low-echogenic, significantly thickened intestinal wall; in case of 7 children with enlarged intestinal lumen and in 11 with the narrow lumen. In the colour Doppler option, moderate vascular flow signals were visible in all patients. Additionally, surrounding lymph nodes were enlarged. In 9 patients fluid between intestinal loops was presented. Due to the thickening of the wall of the affected intestine, Burkitt's lymphoma was suspected. Laboratory tests, bone marrow and MR / CT scans evaluation of the abdominal cavity and pelvis confirmed the initial US diagnosis.

Conclusions: Ultrasound examination allows for fast and accurate diagnosis of patients with symptoms of "acute abdomen". It is also a useful and helpful tool in diagnosing Burkitt's lymphoma.

References

1. López C. et. al. Burkitt lymphoma. doi: 10.1038/s41572-022-00404-3
2. Roschewski M, et. al. Burkitt's Lymphoma. doi: 10.1056/NEJMra2025746.

NEUROSONOGRAPHY IN NEONATE PATIENTS: ANATOMY, TECHNIQUE, INDICATIONS AND MOST COMMON FINDINGS

Ligita Bespalovaite¹, Algirdas Besevicius¹

1. Lithuanian University of Health Sciences

Abstract body

Actuality and Aim: Neurosonography is a simple, established non-invasive technique for the intracranial assessment of preterm and normal term newborns. It can be performed at the bedside without any need for sedation or specific monitoring. Because of the high incidence of pathology in gestationally immature neonates, screening sonography is required for every infant.

Materials and methods: A systemic search for relevant studies was performed from Medline (PubMed), Lippincott Williams and Wilkins, SpringerLink and Cochrane Library databases, ScienceDirect.

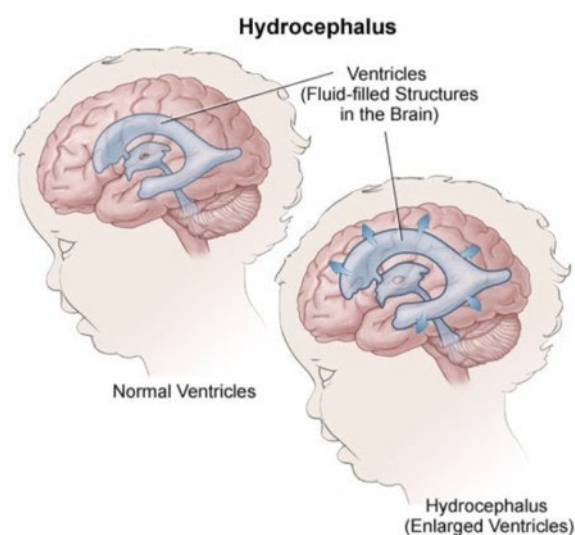
Results: The common pathologies and their US appearance, as well as typical indications and applications of neurosonography are listed. The sonographic features of intracranial hemorrhage include areas of increased echogenicity in the region of the germinal matrix, within the ventricles, or in the surrounding cerebral parenchyma. Premature neonates are also at risk for ischemic disease, particularly periventricular leukomalacia, which is accurately diagnosed sonographically and implies a poor prognosis in almost every infant affected. Intracranial sonography is also an excellent method to evaluate abnormalities that are not associated with gestational immaturity. Neurosonography offers excellent anatomic imaging of the brain when evaluating for congenital anomalies, because sections may be obtained in a multitude of orientations.

Conclusion: Sonography represents an excellent modality to evaluate the infant and neonatal brain. In a number of diseases it may be diagnostic alone. The informed clinician, however, should keep in mind those instances where a complimentary modality, such as MRI scan can add additional or essential information, needed to accurately determine the diagnosis.

References

Maller VV, Cohen HL. Neonatal Head Ultrasound

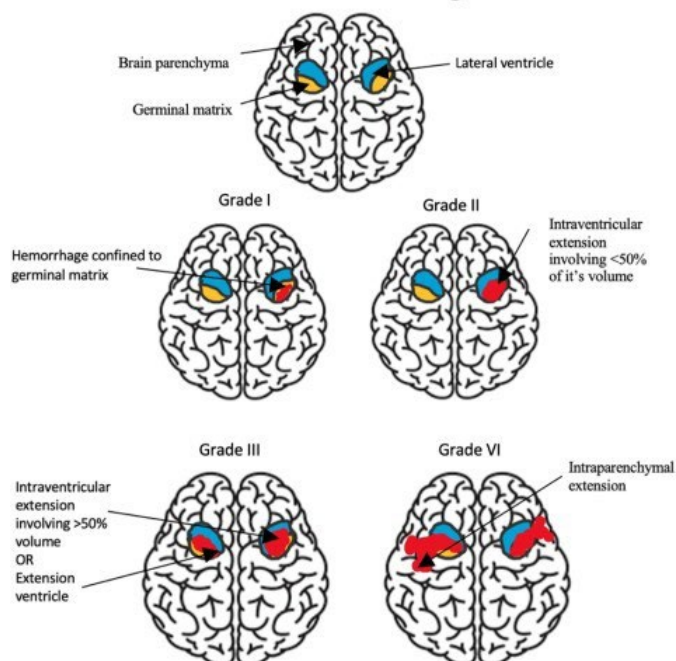
NEUROSONOGRAPHY IN NEONATE PATIENTS: ANATOMY, TECHNIQUE, INDICATIONS AND MOST COMMON FINDINGS



Schematic view of normal ventricles and hydrocephalus.

GERMINAL MATRIX HEMORRHAGE

Normal coronal view through the brain



Grades of germinal matrix intraventricular hemorrhage (grades I to IV).

ACUTE ABDOMEN IN PREGNANCY

Giedrius Ledas¹, Ignė Gecaitė-Paukštė¹

1. Vilnius University

Abstract body

Learning objectives: Evaluate changes of abdominal organs anatomy during pregnancy. Summarise physiological sonographic findings and physiological changes in laboratory tests since both of these play a significant role in clinical decision making. Present the most common causes of acute abdominal pain in pregnancy excluding obstetric pathology.

Background: Acute abdomen in pregnancy is a complex clinical scenario with unique challenges. Clinical assessment can be difficult because some signs of pathological processes such as nausea and vomiting overlap with these of a normal pregnancy. Ultrasound is first line imaging method regardless of trimester. Acute inflammatory and vascular conditions if not diagnosed and treated appropriately poses a significant risk to the mother and fetus.

Findings: With pregnancy progression, the uterus ascends to the abdominal cavity and dislocates abdominal organs, for example, the cecal pole and appendix moves into the upper right quadrant. Some sonographic findings like hydronephrosis are observed as physiological phenomenon in the majority of healthy pregnancies. The imaging features of most abdominal pathologies on ultrasound are identical to those outside of pregnancy, but some conditions, for example, gallstone diseases are more common.

Conclusions: Acute abdomen in pregnancy is a clinical challenge with a wide range of differential diagnoses and, if these conditions are left untreated, devastating outcomes. Knowledge of physiological sonographic findings during pregnancy is essential for accurate diagnosis.

References

Lie G, Eleti S, Chan D, Roshen M, Cross S, Qureshi M. Imaging the acute abdomen in pregnancy: a radiological decision-making tool and the role of MRI. *Clinical Radiology*. 2022 Sep 1;77(9):639-49.

ULTRASOUND BI-RADS CLASSIFICATION

Indrė Lekienė ¹

1. Vilnius University Faculty of Medicine

Abstract body

One of the most important examinations of the breast is breast ultrasound. Breast ultrasound is very challenging for a radiologist because every woman has a different structure of the breast - especially it is difficult when a woman has a lot of fibrocystic changes to evaluate the suspicious areas or lumps.

Most of the time when a woman comes to the doctor with a palpable lump, they have to undergo an ultrasound to evaluate the breasts. Radiologists have to decide if the changes in a breast tissue look suspicious and does it need biopsy or a further investigation. Because of these reasons it is very important to have systematic rules to evaluate these changes - the most common classification in the world is Breast Imaging-Reporting System (BI-RADS) - it provides standardised breast imaging terminology, report organisation and assessment structure. So, I'll talk about how to use this classification in a daily routine and improve the outcomes of the patients.

References

<https://www.acr.org/Clinical-Resources/Reporting-and-Data-Systems/Bi-Rads>

<https://link.springer.com/article/10.1007/s13244-018-0636-z> <https://link.springer.com/article/10.1007/s00330-022-08617-6>

<https://www.ncbi.nlm.nih.gov/pmc/articles/PMC8590403/> <https://www.ncbi.nlm.nih.gov/pmc/articles/PMC8445238/>

<https://link.springer.com/article/10.1007/s00330-016-4612-z>

THE BICUS ULTRASOUND CERTIFICATE – HOW STUDENTS IN BRANDENBURG CAN HAVE THEIR ULTRASOUND SKILLS CERTIFIED IN THE NEAR FUTURE

Tamy Borbe¹, Alexander Krutz¹, Isabell Zeiger¹, Constantin Remus¹

1. Brandenburg Medical University Theodor Fontane, Brandenburg Institute
for Clinical Ultrasound / BICUS, Neuruppin, Germany

Abstract body

Objectives:

Brandenburg Medical School offers its students the opportunity to undergo a profound student ultrasound training within the framework of supervised practical trainings. The goal of the authors was to develop a certificate for students to certify thereby acquired skills in a standardized way. Students who have participated in all required courses should have a proof in their work as future physicians to continue learning where they left off and to facilitate obtaining further national and international ultrasound certifications.

Material:

For the creation of the requirements catalog, we followed along the guidelines of the German Society for Ultrasound in Medicine (DEGUM). We considered which training formats are applicable and can be provided by us as a SkillsLab and how much practical experience the students have to gain. Of course, the maximum quantitative scope of such a catalog must also be taken into account in order to be able to be completed alongside regular medical studies.

Results:

We have created a catalog of nine points, one of which includes substitute services. The basis for obtaining a certificate is a structured ultrasound course. Building on this, various teaching formats are then used to further expand and deepen the skills and knowledge. Students who meet all prerequisites must then pass an OSCE exam, which specifically tests the practical skills they have learned.

Conclusion:

The ultrasound certificate will be introduced at our university in the coming semester. It remains to be seen how this additional offer will be accepted by the students.

References

X

TO PUNCTURE OR NOT TO PUNCTURE: PROFIT-LOSS BALANCE OF THE TRANSPLANT RENAL BIOPSY. US ASSESSMENT OF THE PROCEDURE-RELATED COMPLICATIONS

Olga Pustelniak¹, ***Anna Drelich-Zbroja***², ***Maryla Kuczyńska***²

1. Students' Scientific Society at the Department of Interventional Radiology and Neuroradiology, Medical University of Lublin, Lublin, Poland, 2. Department of Interventional Radiology and Neuroradiology, Medical University of Lublin, Lublin, Poland

Abstract body

Actuality: Kidney transplantation is the most effective method of renal replacement therapy - the transplanted organ is able to take over all the functions performed by healthy kidney. The function of the kidney after transplantation should be regularly observed in laboratory tests and imaging examinations. However, in some patients, it is necessary to perform a posttransplant biopsy in order to clearly identify the pathology that may lead to damage function of the kidney or transplant rejection. The aim of the study was to assess the type of complications occurring after a biopsy of a transplanted kidney and to assess the effectiveness of ultrasound in diagnosing them.

Materials and Methods: A retrospective evaluation of the results of US examinations in 489 patients after biopsy of a transplanted kidney was performed in terms of the incidence of complications. All ultrasound examinations were performed in the radiology department with the use of Logiq 7 and 9 devices in B-mode presentation and in color and spectral Doppler options.

Results: Complications after biopsy were found in 9 patients: 6 arteriovenous fistulas and 3 hematomas. One of the patients required the embolization of the damaged vessel by the endovascular method.

Conclusion: Ultrasound examination with the use of Doppler option is an effective method to detect complications after a biopsy of a transplanted kidney, which allows for qualification for endovascular treatment.

References

M D Patel, S W Young, J S Kriegshauser, N Dahiya. Ultrasound-guided renal transplant biopsy: practical and pragmatic considerations. *Abdom Radiol (NY)*. 2018 Oct;43(10):2597-2603. doi: 10.1007/s00261-018-1484-5

INCIDENCE AND CLINICAL RELEVANCE OF INCIDENTAL FINDINGS IN UPPER GASTROINTESTINAL ENDOSCOPIC ULTRASOUND EXAMINATIONS (IFEUS)

***Isabell Zeiger*¹, Dieter Nürnberg², Christian Jenssen³**

1. Medical University Brandenburg "Theodor Fontane", Neuruppin, Germany and Brandenburg Institute for Clinical Ultrasound (BICUS), Neuruppin, Germany, 2. Medical University Brandenburg "Theodor Fontane", Neuruppin, Germany and 3. Brandenburg Institute for Clinical Ultrasound (BICUS), Neuruppin, Germany, 3. Medical University Brandenburg "Theodor Fontane", Neuruppin, Germany, Department of Internal Medicine, Klinikum Märkisch-Oderland, Strausberg/Wriezen, Germany and Brandenburg Institute for Clinical Ultrasound (BICUS), Neuruppin, Germany

Abstract body

Objectives:

Since the quality of clinical imaging is continuously improving, incidental findings (IFs) become more common. In endoscopic ultrasound (EUS) examinations there are both – endoscopic and sonographic IFs. The aim of this project is to evaluate frequency and clinical relevance of IFs in upper gastrointestinal (ugi) EUS examinations in a Brandenburg hospital. This study refers to the recommendation of the World Federation of Ultrasound in Medicine and Biology to provide more data on the issue of IFs (1).

Materials:

The retrospective single center cross-sectional study included 344 out of 456 uGI EUS examinations between 01/01/2022 and 31/12/2022 at a Brandenburg primary care hospital. We selected IFs described in EUS reports.

Results:

Overall, 224 new IFs were found in 130 of 344 patients (37.8%). 68 IFs (30.4%), were located in the pancreas, 57 (25.5%) in the uGI tract (esophagus, stomach, duodenum) and 51 (22.8%) in the liver. After taking age and co-morbidity into account, clinical relevance remained in 100 (44.6%) cases (secondary clinical relevance). 94 examinations (27.3%) based on an indication referring to an IF in another imaging method.

Conclusion:

IFs from abdominal cross-sectional imaging are a common indication for uGI EUS examinations. Conversely, the high spatial resolution means that IFs are surprisingly frequently generated by EUS itself, a substantial proportion of which are considered clinically relevant.

References

(1) Dietrich CF, Westerway S, Nolsoe C, Kim S, Jenssen C. Commentary on the World Federation for Ultrasound in Medicine and Biology Project "Incidental Findings". *Ultrasound Med Biol.* 2020;46(7):1815-20

ULTRASOUND TRAINING IN E-LEARNING FORMAT. IS IT PRACTICABLE ?

David Boten¹, **Benedikt Beilstein**¹, **Sophie-Luise Sanger**², **Nils Daum**³

1. Brandenburg Medical School Theodor Fontane (MHB), Campus Neuruppin, Fehrbelliner Strae 38, 16816 Neuruppin, Germany, 2. Technische Universitat Dresden, 3. Charite – Universitatsmedizin Berlin, corporate member of Freie Universitat Berlin and Humboldt Universitat zu Berlin

Abstract body

Introduction:

Practical clinical skills are essential components of everyday medical practice. Particularly in ultrasound training, practical implementation is an essential component in order to be able to produce and interpret ultrasound images oneself.

There are some scientific approaches to teaching practical skills via an online-based platform that have demonstrated the effectiveness of such a teaching approach. In some cases, online-based simulations or videos even showed better results than traditional learning courses.

Ultrasound education via an online-only course has some limitations, especially with regard to the hands-on learning experience. Nevertheless, it is possible to provide students with both theoretical and practical content via online formats such as Mentimeter (<https://www.mentimeter.com/>) or interactive synchronous online tutorials [1]. A list of pros and cons are contrasted in Table 1.

Summary:

Teaching practical skills via online-only formats has some limitations. The independent performance of certain examination techniques on real patients is an essential component of any practical learning content. However, at this stage, these technologies are not optimally suited for teaching practical skills that are otherwise possible in peer-to-peer teaching. However, certain basics of ultrasound training can also be usefully supplemented with online formats and offer the possibility of imparting knowledge through interactive teaching.

References

1. Daum N and Boten D et al. Erwerb von Medienkompetenz zur Durchfhrung eines synchronen Online-Tutoriums zur Entwicklung fachlich-methodischer Basiskompetenzen in der medizinischen Aus- und Weiterbildung. Jahrestagung der Gesellschaft fr Medizinische Ausbildung (GMA); September; Zrich, Schweiz 2021.

ULTRASOUND TRAINING IN E-LEARNING FORMAT. IS IT PRACTICABLE ?

Table 1: Pros and Cons of telemedical ultrasound training

Pro	Con
Recognition of structures and pathologies is taught primarily through visual diagnoses on the ultrasound image and can not only be taught through suitable online formats, but the knowledge taught can also be tested (e.g. Mentimeter)	An important component of ultrasound training is the hands-on experience of setting up ultrasound images and cannot be practically taught via telemedicine alone
Newer synchronous online offerings can also impart theoretical and practical knowledge digitally	It requires both technical and specific didactic knowledge to teach online formats, especially in relation to practical trainings
Newer online formats can also show the transducer position and sonographic setting on the patient digitally	Direct feedback from the lecturer is only possible with the appropriate technical equipment
Costs for many devices can be saved through a higher number of participants	
Especially in developing countries, online formats are very well accepted due to the limited access to ultrasound teaching on site	

ANALYSIS OF THE SUBHARMONIC RESPONSE OF DEFINITY, SONAZOID, AND LUMASON IN AN IN VITRO FLOW SYSTEM

Hailee Mayer¹, Cara Esposito¹, Priscilla Machado¹, Trang Vu¹, Ga Won Kim¹, Kirk Wallace², Flemming Forsberg¹

1. Department of Radiology, Thomas Jefferson University, 2. GE HealthCare, Niskayuna, NY 12309, USA

Abstract body

Actuality and Aim: The subharmonic response of ultrasound contrast agents (UCAs) can be used to noninvasively estimate ambient pressures using the SHAPE technique. Previous studies have shown that most commercial UCAs, such as Definity (Lantheus Medical Imaging) and Sonazoid (GE HealthCare), have an inverse linear relationship between subharmonic signals and hydrostatic pressure. However, the observed subharmonic behavior of Lumason (aka SonoVue; Bracco), has varied across studies. Hence, this study directly compared the subharmonic responses of Lumason, Sonazoid and Definity in an in vitro flow system using a commercial ultrasound scanner.

Methods: The UCAs were suspended in a closed loop, dynamic pressure pump flow system, which produced pressures ranging from 0-40 mmHg. A Logiq E10 scanner (GE HealthCare) with a C1-6 probe (transmitting/receiving at 2.50/1.25 MHz) was used to collect subharmonic signals over 5s in triplicate following calibration. As the reference standard hydrostatic pressures were acquired using a pressure catheter (Millar) and a digital oscilloscope (LeCroy). The average ambient pressure values were correlated with the subharmonic amplitudes using linear regression.

Results: Definity and Sonazoid showed an inverse linear relationship with pressure (slope=-0.33 dB/mmHg, $r=0.82$ and slope=-0.24 dB/mmHg, $r=0.91$) as expected, while Lumason showed a direct linear relationship (slope=0.47 dB/mmHg, $r=0.82$).

Conclusions: Lumason's behavior, as a function of the hydrostatic pressures tested, was opposite to that of Definity and Sonazoid. Given these conflicting results, compared to the published literature, further investigations into Lumason's subharmonic response to ambient hydrostatic pressure changes are needed.

Acknowledgements: NIH R01DK118964 and R01DK098526

References

N/A

CORRELATION BETWEEN VISCERAL AND SUBCUTANEOUS FAT AND EPICARDIAL FAT IN DIABETICS AND NON-DIABETICS – ULTRASOUND STUDY

***Alexandra André*¹, João Paulo Figueiredo¹, Susana Jorge², Joaquim Castanheira¹, Jaquelina Tavares¹, Paulo Matafome³**

1. Polytechnic of Coimbra, Health School, Rua 5 de Outubro, 3045-043 Coimbra, Portugal, **2.** ACes Baixo Mondego, USF Mondego, São Martinho do Bispo, Coimbra, **3.** Institute of Physiology and Institute of Clinical and Biomedical Research (ICBR), Faculty of Medicine, University of Coimbra, 3000-548 Coimbra, Portugal

Abstract body

Type II Diabetes Mellitus (DMT2) is a chronic disease characterized by the presence of peripheral insulin resistance, as well as insufficient insulin secretion by pancreatic β cells. Obesity is a major risk factor, leading to insulin resistance in organs like the skeletal muscle, the adipose tissue, and the liver. We aimed to correlate changes in the visceral (VF), subcutaneous (SF) and epicardial fat (EF) in individuals with DMT2 to evaluate ectopic fat deposition and compared them with healthy individuals. Material and Methods: A sample of 25 individuals DM T II (n=14) non-diabetics (n=11), age [48-82] was studied and a protocol was used to evaluate visceral and subcutaneous fat through ultrasound, and epicardial fat through echocardiography. Individuals with chronic disease were excluded. Results: To all individuals a positive and significant correlation between VF and SF ($\rho=0,658$; $p<0,05$) was found, as well as between VF and EF ($\rho=0,624$; $p<0,05$). VF and EF were correlated specially in individuals with diabetics, who revealed a more significant correlation between measurements of VF and EF ($\rho=0,872$; $p<0,05$) than non-diabetics ($\rho=0,406$).. Conclusions: A stronger correlation was observed between EF and VF than with SF in individuals with DM T II. The excessive presence of EF may be associated with a higher risk of cardiovascular disease, both due to the factors released by the epicardial fat, but also due to the higher presence of visceral fat in these patients. US is an accurate and efficacy to evaluate VF, SF and EF

References

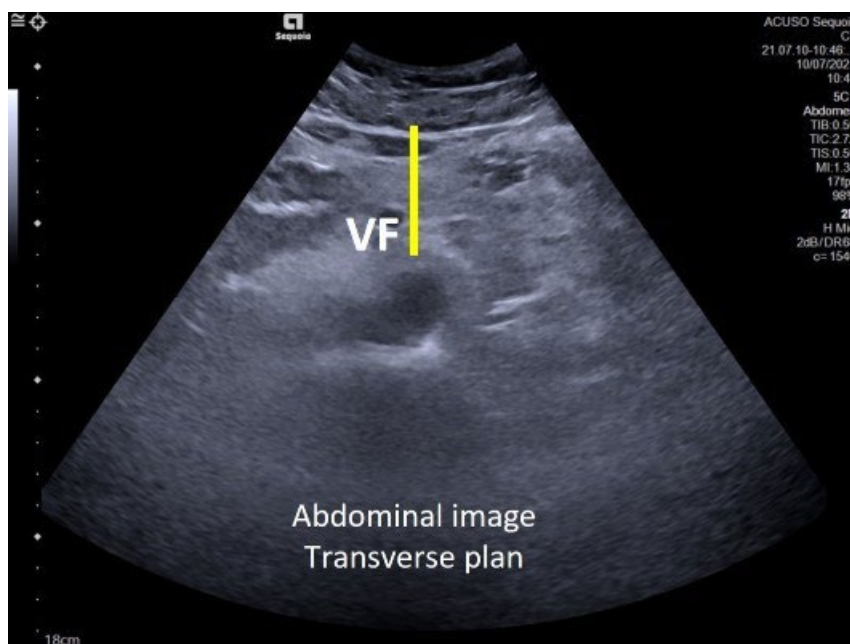
DOI:

10.1097/MED.0b013e3283293015

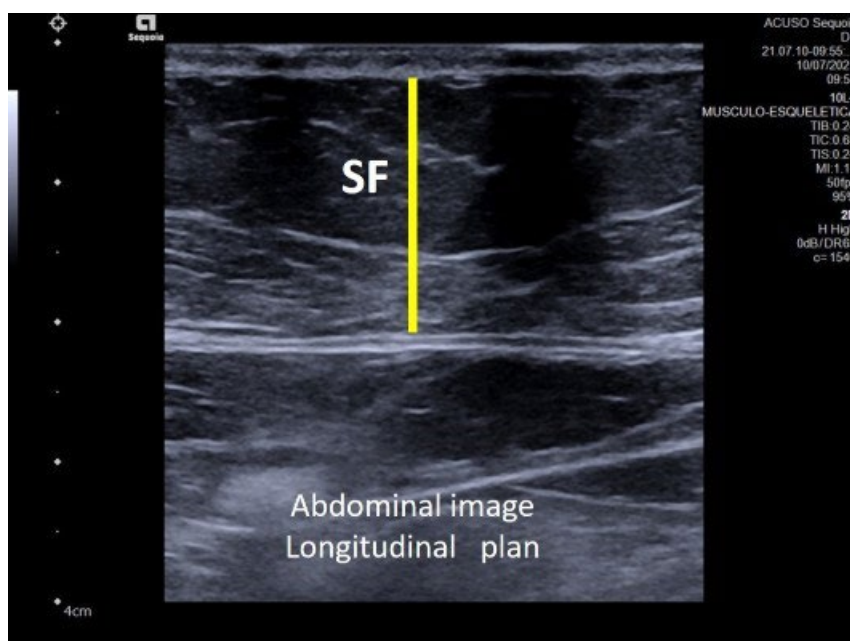
10.21037/hbsn.2019.11.28

10.1016/j.euje.2005.12.014.

CORRELATION BETWEEN VISCERAL AND SUBCUTANEOUS FAT AND EPICARDIAL FAT IN DIABETICS AND NON-DIABETICS – ULTRASOUND STUDY

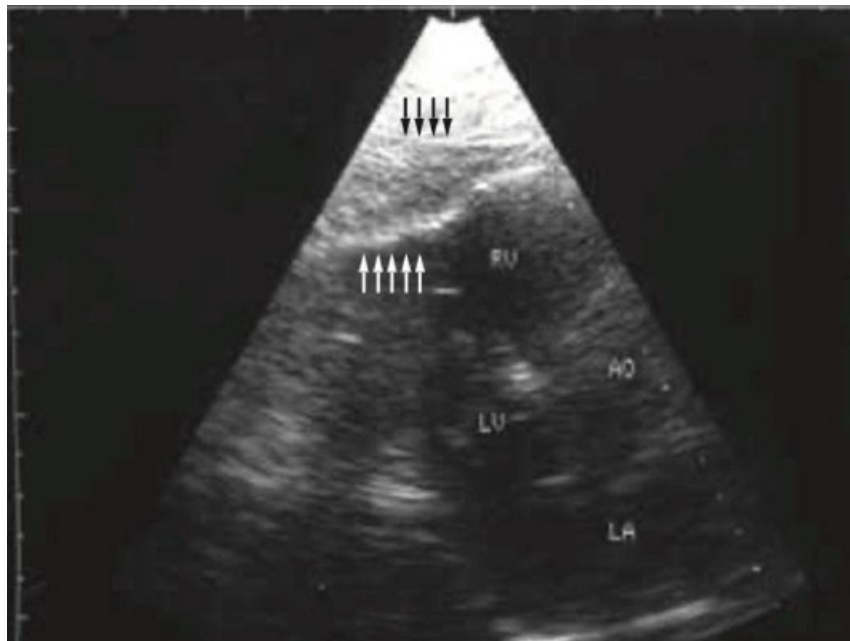


Visceral Fat Ultrasound Evaluation.



Subcutaneous Fat Ultrasound Evaluation.

CORRELATION BETWEEN VISCERAL AND SUBCUTANEOUS FAT AND EPICARDIAL FAT IN DIABETICS AND NON-DIABETICS – ULTRASOUND STUDY



Epicardial Fat - Ecocardiography.

THE ASSESSMENT OF LIVER SHEAR WAVE DISPERSION (VIPLUS) IN A HEALTHY COHORT

***Alexandru Popa*¹, *Roxana Sirli*², *Ioan Sporea*², *Andreea Borlea*³, *Alina Popescu*¹**

1. Division of Gastroenterology and Hepatology, Department of Internal Medicine II, Center for Advanced Research in Gastroenterology and Hepatology, "Victor Babes" University of Medicine and Pharmacy, E. Murgu Square, Nr. 2, 300041 Timisoara, Romania, 2. Division of Gastroenterology and Hepatology, Department of Internal Medicine II, Center for Advanced Research in Gastroenterology and Hepatology, "Victor Babes" University of Medicine and Pharmacy, E. Murgu Square, Nr. 2, 300041 Timisoara, 3. Division of Endocrinology, Department of Internal Medicine II, "Victor Babes" University of Medicine and Pharmacy, E. Murgu Square, Nr. 2, 300041 Timisoara

Abstract body

Background and Aims: It is hypothesized that necro-inflammatory changes influence the propagation of shear waves (dispersion). Therefore, novel imaging techniques that explore the dispersion properties of shear waves have been developed, which can serve as an indirect tool for evaluating the viscosity of the liver (Vi PLUS). Defining the reference values for healthy participants of various ages and genders is crucial.

Method: 131 consecutive participants with healthy livers were enrolled in this prospective study conducted at a tertiary Gastroenterology and Hepatology center. Normal abdominal US examination, normal LS values evaluated by TE (LS<6 kPa), normal Controlled Attenuation Parameter (CAP) value (less than 248 dB/m), absence of obesity (BMI<30), normal blood count, and normal liver function tests were the inclusion criteria.

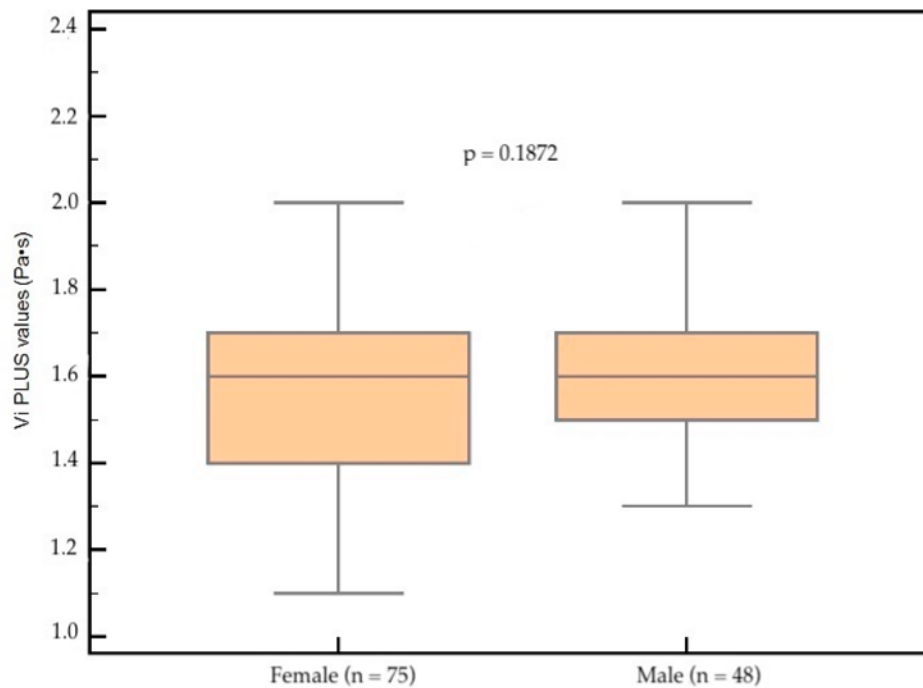
Results: Using 2D-SWE and Vi PLUS, valid measurements were obtained in 93.9% (123/131). The mean liver Vi PLUS value obtained in subjects with healthy livers (n=123) was 1.57 ± 0.20 Pa·s for females and 1.62 ± 0.21 Pa·s for males, respectively. No significant differences between Vi PLUS mean values were found ($p=0.1872$). Mean Vi PLUS values were significantly lower in subjects with normal weight (1.53 ± 0.19 Pa·s) compared to overweight subjects (1.67 ± 0.19 Pa·s) ($p=0.0001$). In the univariate regression analysis: age ($p<0.001$), BMI ($p<0.001$), abdominal circumference ($p<0.001$), LS values by FS ($p<0.001$) and LS values by 2D-SWE ($p<0.001$) were associated with Vi PLUS values.

Conclusion: Vi PLUS is a highly feasible method. The overall mean value of liver viscosity in the cohort of participants with healthy livers was 1.59 Pa·s.

References

Sugimoto. Clinical utilization of shear wave dispersion imaging in diffuse liver disease. *Ultrasonography* 2020.

THE ASSESSMENT OF LIVER SHEAR WAVE DISPERSION (VIPLUS) IN A HEALTHY COHORT



Vi PLUS values according to gender.

THE ROLE OF BREAST ULTRASOUND IN BREAST CANCER SCREENING

Jacob Roxana¹

1. Victor Babes University of Medicine and Pharmacy Timisoara, Discipline of Radiology and Medical Imaging

Abstract body

Actuality and Aim: One of the most prevalent cancers in the world and the leading cause of mortality and suffering in women is breast cancer. Because breast cancer cannot be cured once it has spread to other parts of the body, early detection is essential. The purpose of this research is to show the value of bedside breast ultrasound in the early detection of breast cancer.

Material and Methods: The three-month study included 47 female patients admitted to the “Dr. Victor Babes” Hospital of Pneumoftiziologie and Infectious Diseases in Timisoara. Patients were questioned about their personal history, comorbidities, and family history of breast cancer-related pathologies before being evaluated with bedside ultrasound.

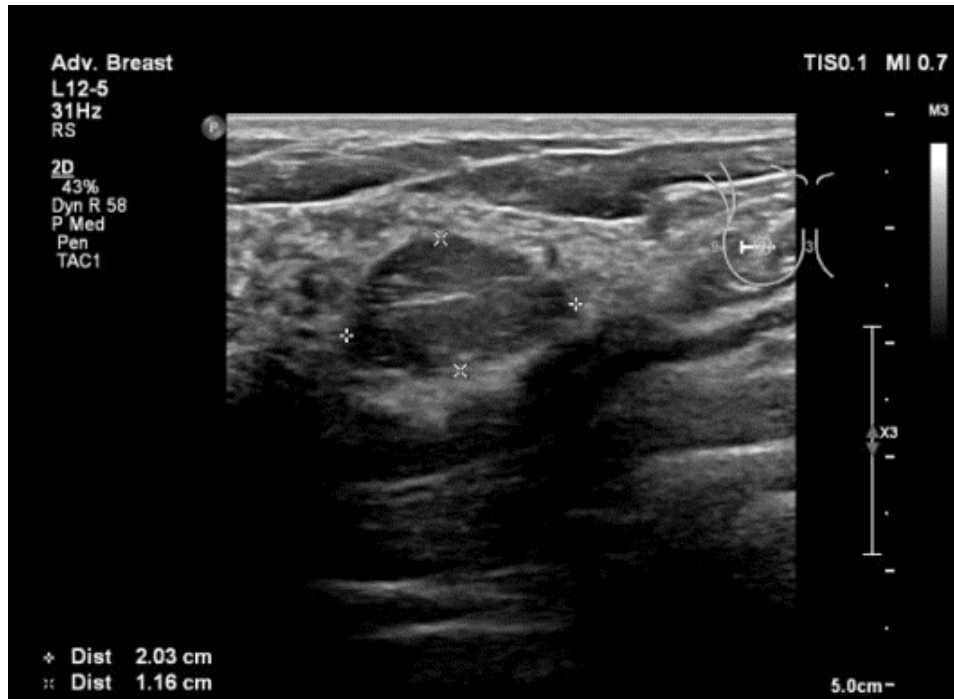Results: Two of the 47 patients were already diagnosed with breast cancer, so they were excluded from the study. Three patients were found with suspicious lesions, one of whom claimed to have symptoms - a palpable mass in the right breast - and two who had neither symptoms nor palpable lumps; they were further evaluated using mammography, breast MRI, and ultrasound-guided breast biopsy. The remaining 5 patients had fibroadenomas-related masses, while 17 had cysts.

Conclusions: Although mammography is the gold standard for breast cancer screening, breast ultrasound is a very useful technique that is more accessible and affordable. Breast ultrasound can detect palpable lesions as well as characterize masses seen on mammography. This imaging technique can also detect axillary adenopathy, which is important in the staging of breast cancer.

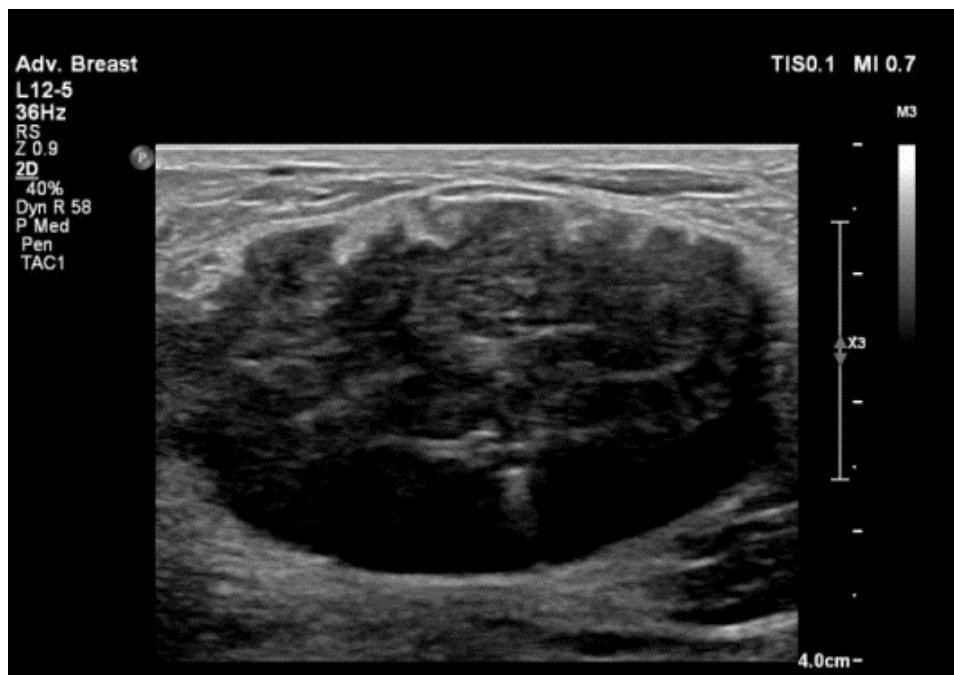
References

Harbeck N., Gnant M. Breast Cancer. Lancet. 2017;389:1134-1150. doi: 10.1016/S0140-6736(16)31891-8.

THE ROLE OF BREAST ULTRASOUND IN BREAST CANCER SCREENING



Solid lesion found in the right breast.



Big solid lesion that was not palpable.

QUANTIFICATION OF LIVER VISCOSITY IN TYPE 2 DIABETES MELLITUS PATIENTS USING ULTRASOUND SHEAR WAVE DISPERSION (VISCOSITY)

Alexandru Popa¹, Roxana Sirli², Ioan Sporea², Andreea Borlea³, Alina Popescu²

1. Division of Gastroenterology and Hepatology, Department of Internal Medicine II, Center for Advanced Research in Gastroenterology and Hepatology, "Victor Babes" University of Medicine and Pharmacy, E. Murgu Square, Nr. 2, 300041 Timisoara, 2. Division of Gastroenterology and Hepatology, Department of Internal Medicine II, Center for Advanced Research in Gastroenterology and Hepatology, "Victor Babes" University of Medicine and Pharmacy, E. Murgu Square, Nr. 2, 300041 Timisoara, Romania, 3. Division of Endocrinology, Department of Internal Medicine II, "Victor Babes" University of Medicine and Pharmacy, E. Murgu Square, Nr. 2, 300041 Timisoara

Abstract body

Background: Novel imaging techniques that explore the dispersion properties of shear waves as a marker of hepatic inflammation have been developed (ViPLUS). The present study aimed to evaluate liver viscosity in a cohort of NAFLD patients with and without diabetes mellitus.

Method: Prior to enrollment, all patients were examined using abdominal ultrasonography and using the Transient elastography (TE) and Controlled Attenuation Parameter (CAP). The presence of liver steatosis on abdominal ultrasonography and CAP values above 248 dB/m were considered as inclusion criteria. To prevent bias, only individuals without liver fibrosis were included in this study (TE < 6 kPa). All patients were examined using ViPLUS method embedded on the Supersonic MACH30 ultrasound system.

Results: 351 patients were included in the study: 101 with diabetes mellitus (DM) and 250 without DM. Statistically significant differences were found between the groups with and without DM for ViPLUS (median = 1.85 Pa·s vs. 1.70 Pa·s; U = 7792, p = 0.0001). A weak, positive correlation was found between ViPLUS and the abdominal circumference (r = 0.268, p = 0.0001) and the presence of diabetes (r = 0.228, p < 0.0001). No statistically significant correlations were established between ViPLUS and transaminases, age, cholesterol, triglycerides level or GGT.

Conclusion: There were statistically significant differences between groups with and without diabetes for ViPLUS.

References

Sugimoto, K. Clinical utilization of shear wave dispersion imaging in diffuse liver disease. *Ultrasonography* 2020.

A NATIONAL REGISTER FOR INTERVENTIONAL ULTRASOUND (INVUS) IN GERMANY: PRELIMINARY RESULTS OF A PILOT STUDY

**Eder Nicole¹, Zeiger Isabell², Daum Nils², Seckinger Dominik Antonius²,
Nürnberg Dieter², Jenssen Christian¹**

1. Krankenhaus Märkisch-Oderland, Department of Internal Medicine, Strausberg/Wriezen, Germany; Brandenburg Institute for Clinical Ultrasound (BICUS), Medical University Brandenburg "Theodor Fontane", Faculty of Health Sciences, Neuruppin, Germany, 2. Brandenburg Institute for Clinical Ultrasound (BICUS), Medical University Brandenburg "Theodor Fontane", Faculty of Health Sciences, Neuruppin, Germany

Abstract body

Aim

Interventional ultrasound (INVUS) has become an essential part of daily clinical practice (1,2). However, the current state of research on risk factors and adverse events is mostly based on monocentric or retrospective studies and are often limited in scope (1,3). A prospective register for INVUS procedures may improve the scientific data base.

Material and Methods

In preparation for an INVUS register, a pilot study focusing on abdominal procedures is currently being conducted at 9 study centers. Technical variables, risk factors, quality of outcomes, and adverse events are recorded.

Results

A total of 934 ultrasound (US)-guided interventional procedures have been included to date (83.3% diagnostic, 16.7% therapeutic); preferentially involving the liver (46.9%), pancreas (20.6%) and lymph nodes (12.2%) (Table 1). Adverse events occurred more frequently in the therapeutic group and were mostly associated with pain. Bleeding was observed in 2.4% (therapeutic) and 10.1% (diagnostic) (Table 2).

Conclusion

Based on the pilot study, a nationwide register has been established, which will collect prospective data on diagnostic and therapeutic percutaneous and endoscopic US-guided procedures for a 5-year period starting in the 2nd quarter of 2023. The register includes abdominal, thoracic, and vascular procedures and may be expanded to other areas in the future. The aim is to provide a comparative assessment of outcome quality, adverse events, and their predictors to improve the evidence base of guideline recommendations.

References

1. Dietrich CF, Nuernberg D (Eds.). Interventional Ultrasound. Thieme 2015.
2. Lorentzen T, et al. Ultraschall Med 2015;36:E1-14.
3. Strobel D, et al. Ultraschall Med 2015;36:122-131.

A NATIONAL REGISTER FOR INTERVENTIONAL ULTRASOUND (INVUS) IN GERMANY: PRELIMINARY RESULTS OF A PILOT STUDY

Table 1: Types and targets of INVUS procedures

Parameter	total		diagnostic		therapeutic	
	N	%	N	%	N	%
type of intervention						
diagnostic puncture	778	83,3	778	100		
catheter drainage	121	13,0			121	77,6
drainage puncture	24	2,6			24	15,4
cholangiodrainage	8	0,9			8	5,1
ablation	3	0,3			3	1,9
probe						
curved array	584	62,5	460	59,1	124	79,5
linear array	28	3,0	28	3,6	0	0,0
EUS longitudinal	311	33,3	281	36,1	30	19,2
EUS rigid	1	0,1	1	0,1	0	0,0
target of intervention						
liver	438	46,9	385	49,5	53	34,0
pancreas	192	20,6	160	20,6	32	20,5
lymph node	114	12,2	114	14,7	0	0,0
adrenal glands	22	2,4	22	2,8	0	0,0
kidney	16	1,7	11	1,4	5	3,2
GIT	25	2,7	17	2,2	8	5,1
spleen	3	0,3	3	0,4	0	0,0
gallbladder	11	1,2	4	0,5	7	4,5
bile ducts	4	0,4	0	0,0	4	2,6
other	95	10,2	49	6,3	46	29,5
not specified	14	1,5	13	1,7	1	0,6
total	934		778		156	

Table 2: Adverse events in diagnostic and therapeutic INVUS procedures

adverse events	total (n = 934)		diagnostic (n= 778)		therapeutic (n= 156)	
	N	%	N	%	N	%
hypotension	15	10,0	14	12,8	1	2,4
cardiac arrhythmia	2	1,3	2	1,8	0	0,0
ventilatory failure	11	7,3	9	8,3	2	4,9
aspiration	3	2,0	3	2,8	0	0,0
interventional pain	43	28,7	29	26,6	14	34,1
postinterventional pain	45	30,0	27	24,8	18	43,9
vasovagal reaction	5	3,3	5	4,6	0	0,0
relevant bleeding	12	8,0	11	10,1	1	2,4
infection	8	5,3	7	6,4	1	2,4
free fluid	2	1,3	2	1,8	0	0,0
hemothorax	0	0,0	0	0,0	0	0,0
pneumothorax	0	0,0	0	0,0	0	0,0
perforation	1	0,7	0	0,0	1	2,4
fistula	1	0,7	0	0,0	1	2,4
pancreatitis	0	0,0	0	0,0	0	0,0
thrombosis	1	0,7	0	0,0	1	2,4
material issues	1	0,7	0	0,0	1	2,4
total	150		109		41	

MULTIPARAMETER CONTRAST ENHANCED ULTRASOUND IS USEFUL FOR DETECTING DIFFUSE AND FOCAL LIVER LESIONS IN PATIENTS WITH DIABETES MELLITUS

Rostyslav Bubnov¹, ***Oleksandr Mukhomor***¹

1. Clinical Hospital "Pheophania" of State Affairs Department

Abstract body

Background

Diabetes mellitus type 2 (DMT2) can cause diffuse and focal lesions of liver. Differentiation with malignant lesions requires CT contrast media associated with various adverse effects. Enhancing ultrasound (US) with modalities like sonoelastography [1] and contrast-enhanced ultrasound (CEUS) can dramatically increase its quality.

The Aim was to study relevance of CEUS to evaluate liver parenchyma in patients with DMT2.

Methods

We included 43 patients (22 females; aged 23 to 72 years): 23 patients with DMT2 and fatty liver (NAFLD; LF1-3); and 20 healthy controls. Patients with cancer, chronic hepatitis, bile stones, obstructive jaundice were excluded. All patients underwent general clinical, lab tests; multiparameter US of liver, Doppler, noninvasive flow evaluation, SWE (Applio). In 2 patients, who presented heterogenic pattern of liver parenchyma and suspicious to lesions we did CEUS (SonoVue, Bracco Imaging).

Results

We detected common US signs of fatty liver: right liver lobe size was 166 ± 9 mm vs 133 ± 8 mm in controls; SWE was 7.4 ± 1.7 kPa (6-13 kPa) vs 4.2 ± 0.8 kPa in controls; in focal lesions isoechoic in grey scale CEUS showed contrast cumulation in venous phase, and SWE showed increased stiffness to 8-11 kPa. CEUS and noninvasive flow evaluation helped to display complex vasculature, low vascularization, visualize vascular flow in areas of heterogeneity on grey scale.

Conclusions

Multiparameter US is effective for evaluating liver parenchyma in patients with DMT2. CEUS helped in accurate diagnosis of both diffuse and focal lesions in particular to detect hidden lesions.

References

Bubnov R, Mukhomor O. Turk J Gastroenterol. 2019;30(Suppl. 3):S313.

ULTRASOUND AND MR NEUROGRAPHY FEATURES OF UPPER LIMB NERVE INJURIES

Mahesh Prakash Prakash¹, Raghuraman Soundararajan¹, Anindita Sinha¹

1. PGIMER

Abstract body

Learning objectives- To illustrate the imaging features of common nerve injuries of upper limb on ultrasound (USG) & magnetic resonance neurography (MRN).

Background- Nerves of upper limb are prone to various injuries like trauma, traction, shear and ischemia. The various imaging features depend on congestion of nerve, edema, fibrosis, and axonal damage. Imaging including Ultrasound and MRI plays important role for evaluation of these pathologies and immensely helpful for guiding management of these. We will illustrate the USG and MRI features of these pathologies for education of radiologists and trainee.

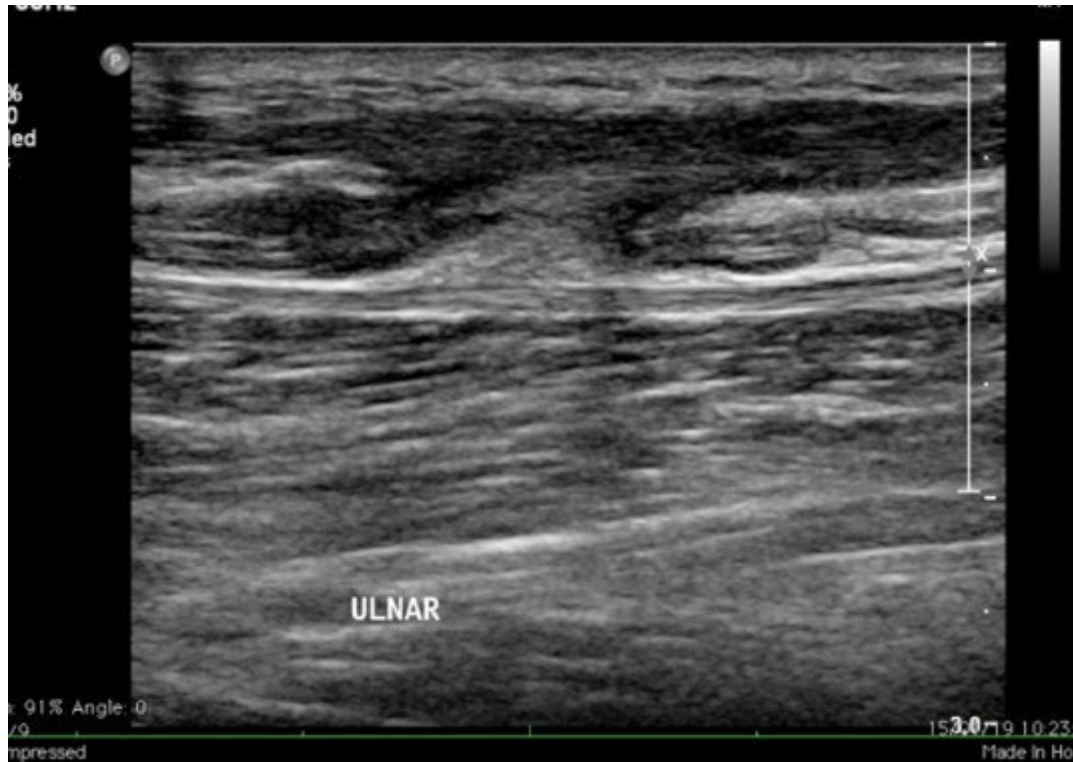Findings- Imaging features of traumatic neuropathy depend upon type of trauma like cut injury or blunt injury. Imaging findings vary from neuropraxia to complete transection of nerve fibres with end neuroma formation and can be graded according to Seddon and Sunderland classifications. In Neuropraxia, Nerve appears mildly thickened and hypoechoic on Ultrasound. MRI shows T1 hypo intensity and T2 hyperintensity of the nerve in this mild form of injury. There can be neuroma in continuity in more severe form of injury. In cases of complete transection of nerve like in cut injuries, there will be disruption of nerve fibres with gap in continuity. Ultrasound and MR neurography are very useful to show exact nerve definition and end neuromas in these cases and ultimately helpful for surgeons in the management.

Conclusions- Ultrasound MRI are good modalities to show nerve injuries

References

Holzgrefe R.E. et. Imaging of the Peripheral Nerve: Concepts and Future Direction of Magnetic Resonance Neurography and Ultrasound. J. Hand Surg. 2019;44:1066-1079

ULTRASOUND AND MR NEUROGRAPHY FEATURES OF UPPER LIMB NERVE INJURIES



Ultrasound image of ulnar nerve injuries with end neuroma formation.

SHEAR-WAVE ELASTOGRAPHY AND VISCOSITY ASSESSMENT IN PATIENTS WITH CHRONIC AUTOIMMUNE THYROIDITIS

Dana Stoian¹, Andreea Borlea¹, Ioan Sporea¹, Alexandru Popa¹, Alina Popescu¹

1. University of Medicine and Pharmacy Victor Babes Timisoara

Abstract body

Chronic autoimmune thyroiditis (CAT) is the most frequent cause of hypothyroidism in developed countries. The ultrasound (US) evaluation may suggest the diagnosis and elastography usually helps confirming the imaging diagnosis. Viscosity assessment is a novel elastography-based technique, with great potential in clinical setting. Our study aimed to evaluate the diagnostic performance of shear-wave elastography (2D SWE PLUS) and viscosity planewave ultrasound (Vi PLUS) in detecting autoimmune thyroiditis using the Hologic Mach 30 ultrasound device. In 308 cases, valid measurements were obtained: 155 cases without thyroid disease and 153 cases with chronic autoimmune thyroiditis (95.95% feasibility). Both Vi PLUS and 2D-SWE PLUS showed statistically significant differences between the healthy group and the CAT group (2.5 ± 0.4 vs 2.8 ± 0.5 , $p < 0.0001$ respectively 13.5 ± 3.3 vs 23.1 ± 8.3 , $p < 0.0001$). The diagnostic performance was poor for Vi PLUS alone (AUC=0.69; cut-off > 2.5 Pa·s, se=68.6%; sp=64.52%) and good for 2D-SWE PLUS alone (AUC=0.861; cut-off > 18.4 kPa, se=69.9%; sp=92.2%). The presence of CAT, the thyroid volume, levothyroxine replacement therapy, and age all had a positive correlation with Vi PLUS. There were statistically significant differences between the CAT subgroup getting thyroid replacement therapy and the subgroup receiving no therapy: 24.74 ± 8.33 vs 21.93 ± 8.12 kPa ($p = 0.0380$) for 2D-SWE PLUS and 3 ± 0.5 vs 2.7 ± 0.4 Pa·s for Vi PLUS ($p = 0.0193$). Elastography-based methods improve the classic ultrasound evaluation: 2D-SWE PLUS performed somewhat better in distinguishing CAT from normal thyroid tissue, while Vi PLUS made a slightly better assessment regarding the functional status.

References

Dighe M et al, Med Ultrason 2017

Stoian D et al, Diagnostics 2022

NON-ALCOHOLIC FATTY LIVER DISEASE AND SUBCLINICAL PERIPHERAL ATHEROSCLEROSIS IN A POPULATION AFFECTED BY FAMILIAL HYPERCHOLESTEROLE

***Alberto Mondelli*¹, Antonio Gallo²**

1. AOU Modena, Medicina Interna, Modena, Italy, 2. Sorbonne University, Department of Endocrinology and Metabolism, Paris, France

Abstract body

There are no data on the association between non-alcoholic fatty liver disease (NAFLD) and subclinical atherosclerosis in people affected by Familial Hypercholesterolemia (FH). This study investigates the influence of NAFLD on subclinical peripheral atherosclerosis in an asymptomatic FH population.

A total of 169 consecutive asymptomatic young individuals affected by genetically defined Heterozygous FH (HeFH) with no prior history of cardiovascular disease, diabetes or secondary steatosis were enrolled and underwent carotid/femoral ultrasonography. NAFLD was assessed by CT, defined as liver/spleen density ratio <1 or liver density < 40 HU.

Measurements of the carotid and femoral arteries were performed using a Philips ultrasound machine with a 9 MHz transducer. C-IMT was measured on the common carotid and the mean c-IMT between the right and left was calculated for each subject. The percentage of stenosis was assessed using the ECST method. Femoral IMT (f-IMT) was measured on the common femoral artery. c-IMT and f-IMT were detected using QLAB software.

Of the study participants 22 (12,4%) had CT-diagnosed NAFLD.

No difference was found for c-IMT ($p=0,91$), carotid plaque ($p=0,35$), f-IMT ($p=0,48$) and femoral plaque ($p=0,8$).

Statins could influence the atherosclerosis evolution in both NAFLD and non-NAFLD group (no difference in percentage of intake). Selecting an FH population not on statin would be appropriate to assess whether NAFLD may have an impact on peripheral atherosclerosis in these subjects.

References

Nonalcoholic Fatty Liver Disease Is Associated With Arterial Distensibility and Carotid Intima-Media Thickness: (from the Multi-Ethnic Study of Atherosclerosis): E.Oni et al. 2019, American Journal of cardiology

THYROID VISCOSITY ASSESSMENT IN A HEALTHY POPULATION - A PROMISING NOVEL ELASTOGRAPHY-BASED EVALUATION

Andreea Borlea¹, Dana Stoian¹, Ioan Sporea¹, Luciana Moisa Luca², Alexandru Popa¹

1. University of Medicine and Pharmacy Victor Babes Timisoara, Dep Internal Medicine 2,

2. Dr D Medical Center, Ultrasound Department

Abstract body

Currently there is growing evidence of the diagnostic utility of elastic indices other than linear stiffness, such as tissue viscosity. In diffuse thyroid disease, viscosity may be helpful in differentiating between inflammation and fibrosis. This study aimed to evaluate the feasibility of viscosity plane-wave ultrasound (Vi PLUS) embedded on the SuperSonic Mach 30 machine, to determine the range of normal for thyroid viscosity values and the factors that influence it. The Vi PLUS evaluation is made in the same time with shear-wave elastography (2D SWE PLUS) measurements), with the the UltraFast software for image acquisition. 115 valid measurements were obtained, Vi PLUS proved to be a highly feasible method (95.1%). Mean values for normal thyroid viscosity ranged between 1.3 and 3.5 Pa·s, with a mean value of 2.42 ± 0.41 Pa·s, with no significant differences between the right and left thyroid lobe ($p=0.863$). A strong, positive correlation was found between 2D-SWE PLUS values and thyroid ViPLUS ($r = 0.608$, $p < 0.0001$). No significant correlations were found between 2D SWE, respectively Vi PLUS and gender, age, BMI or depth. ViPLUS is a cutting-edge ultrasound-based method that is reproducible and feasible for the evaluation of thyroid parenchyma. Our results are encouraging, ViPLUS may be used in clinical practice along with 2D-SWE, for the multiparametric ultrasound evaluation of the thyroid. Our results open the way for further studies that may use this novel elastography tool in detecting thyroid pathology.

References

Popa, A. et al Diagnostics 2021; Sugimoto,

K.; et al. Ultrasonography 2019;

THE PLACE OF CONTRAST-ENHANCED ULTRASOUND IN ASSESSING THYROID CARTILAGE INVASION IN LARYNGEAL CANCER.

Milda Pucetaite¹, **Rytis Tarasevicius**², **Silvija Ryskiene**¹, **Dalia Mitraite**¹,
Saulius Vaitkus¹

1. Lithuanian University of Health Sciences, 2. Lithuanian University of Health Sciences Kaunas Clinics

Abstract body

Actuality:

Detection of thyroid cartilage invasion is one of the most difficult tasks for a radiologist staging laryngeal cancer. Cross-sectional modalities do not have satisfactory diagnostic accuracy for non-ossified thyroid cartilage invasion detection. Contrast-enhanced ultrasound (CEUS) has the potential to detect tumor invasion to the non-ossified non-contrast-enhancing thyroid cartilage.

Aim: To evaluate the usefulness of CEUS, contrast-enhanced computed tomography (CECT), and magnetic resonance imaging (MRI) in assessing non-ossified thyroid cartilage invasion in laryngeal cancer.

Methods: Twenty-one patients with laryngeal carcinoma initially had CECT, followed by CEUS and sixteen of the patients also had MRI before surgery. Four patients had more than one possible invasion site. In total twenty-five, possible invasion sites were detected and evaluated. CEUS characteristics of possible thyroid cartilage invasion were evaluated. The imaging findings of CEUS, CECT, and MRI findings were compared with the postoperative histopathological findings which were chosen as a gold standard.

Results: In total 9 thyroid cartilage invasion sites were detected on histopathological examination. The sensitivity, specificity, and accuracy in the detection of thyroid cartilage invasion were 88.9%, 81.2%, and 84.0% for CEUS, 66.7%, 81.2%, and 76.0% for CECT, and 100.0%, 53.8%, and 66.7% for MRI, respectively. The thyroid cartilage invasion accuracy was significantly different between CEUS and MRI ($P<0.05$), CECT and MRI ($P<0.05$), there was no statistically significant difference between CEUS and CECT.

Conclusion: CEUS showed reliable diagnostic properties for detecting laryngeal carcinoma invasion to non-ossified thyroid cartilage compared with MRI as a complementary study to CECT.

References

-

ULTRASONOGRAPHY AND CONTRAST-ENHANCED ULTRASONOGRAPHY IN GASTROINTESTINAL ACUTE GRAFT-VERSUS-HOST-DISEASE SEVERITY QUANTIFICATION

**Ioanitu Elena Simona¹, Lipan Lavinia², Saftoiu Adrian³, Simu Razvan⁴,
Tanase Alina Daniela⁵**

1. „Carol Davila” University of Medicine and Pharmacy, Bucharest; Internal Medicine Clinic, Fundeni Clinical Institute, Bucharest, 2. Bone marrow transplantation Dept, Fundeni Clinical Institute, Bucharest, Romania, 3. „Carol Davila” University of Medicine and Pharmacy, Bucharest, Romania, 4. „Carol Davila” University of Medicine and Pharmacy, Bucharest, Romania; Internal Medicine Clinic, Fundeni Clinical Institute, Bucharest, Romania, 5. „Carol Davila” University of Medicine and Pharmacy, Bucharest, Romania; Bone marrow transplantation Dept, Fundeni Clinical Institute, Bucharest, Romania

Abstract body

Actuality and Aim. Acute graft-versus-host disease (aGVHD) is one of the most frequent complications after allogeneic stem cell transplant, with gastrointestinal involvement being associated with increased morbidity and mortality. We intent to present our experience using US, CEUS and Weber quantification score in diagnosis and staging of gut aGVHD after allogeneic stem cell transplantation.

Material and Methods. Between January 2019 and March 2022, in Fundeni Clinical Institute, 168 allogeneic stem cell transplants were performed. 20/168 patients were readmitted into the hospital with non-infectious diarrhea and gut aGVHD suspicion. In 12/20 patients, gut aGVHD was histopathologically confirmed. All patients underwent GIUS and CEUS, but in 9/12 patients, CEUS was performed after starting Medrol therapy. In these 12 patients, a risk score based on US and CEUS was calculated, analyzing the bowel wall, bowel lumen and the presence of ascites. Depending on the severity, a score was assigned for each sub-group from 0 (normal appearance) to 3 (the most severe impairment).

Results. 11/12 patients had a score over 7, but the patients in whom CEUS was performed before Medrol therapy had the highest scores, all over 10.

Conclusions. US is an effective non-invasive method to identify the severity of gastrointestinal GVHD and to monitor response to treatment. Based on these results, we aim to introduce US and CEUS as standard investigations for aGVHD.

References

Weber D et al. Non-invasive diagnosis of acute intestinal graft-versus-host disease by a new scoring system using ultrasound morphology, compound elastography, and contrast-enhanced ultrasound. Bone Marrow Transplant. 2019;54(7):1038-48.

COMBINED DUPLEX ULTRASOUND AND ELASTOGRAPHY IN PATIENTS WITH CERVICAL LYMPH NODES AND COVID-19 MILD INFECTION

Doina Georgescu¹, Ioana Ionita¹, Oana-Elena Ancusa¹, Despina Calamar-Popovici¹, Ciprian Rosca¹, Daniel Lighezan¹

1. "V Babes" University of Medicine and Pharmacy, Timisoara

Abstract body

Actuality and Aim: Covid-19 infection could sometimes manifest by cervical lymph node enlargement, that however still imply a differential diagnosis effort, where combined duplex ultrasound-elastography as first step evaluation has a place to be determined. Material and Methods: 53 patients: 28 men, 25 women, average age 19-54 years, referred for cervical lymph node enlargement imaging, that eventually turned to be secondary to Covid-19 infection, joined this observational study. Patients undertook clinical examination, CBC, several blood tests, as well as duplex examination and elastography of lymph nodes. When necessary, fine needle aspiration (FNA) was performed. Results: Tenderness at probe's compression was observed in 84.33%, short-to-long axis ratio >0.5 in 3.77%, fatty hilum in 84.9%, hypoechoic aspect in 75.46%, nodules homogeneity in 79.24%, margins regularity in 94.55% of patients. Central Doppler signal was present in 83.01%, peripheral signal in 15.09%, mixed signal in 1.88% and resistivity index>0.6 in 5.66%. Elastography revealed spotty hard areas in 5.66% and necrose zones in 3.77%. 1 patient eventually experienced FNA with histology of reactive lymphadenitis. 92.22% of patients displayed benign, inflammatory features.

Conclusions. Combined examination duplex ultrasound-elastography, as first step examination was reliable in discriminating between malign/suspicious and benign, being an important asset in cervical lymphadenopathy approach.

References

1. Wang B, Guo Q, Wang JY, et al. Ultrasound Elastography for the Evaluation of Lymph Nodes. Front Oncol, 11, 714660 (2021). <https://doi.org/10.3389/fonc.2021.714660>
2. Al-Ani, R.M., Rashid, R.A. Unpredicted clinical manifestation of COVID-19: a unique case report and review of literature. Egypt J Otolaryngol 38, 122 (2022). <https://doi.org/10.1186/s43163-022-00312-z>

DEEP LEARNING-BASED DETECTION OF VESSELS ASSISTING VEIN CANNULATION PROCEDURE UNDER ULTRASOUND GUIDANCE

Andrius Sakalauskas¹

1. TELEMED, Ultrasound Medical Systems, Savanoriu pr. 178A, Vilnius, LT-03154

Abstract body

Actuality and Aim

It is standard in the field of vein cannulation to use ultrasound to guide catheter insertion. Ultrasound guidance reduces rate of complications, and procedure is performed faster. Rate of complications could be reduced by 57 % and failure rate by 86 % in case of jugular vein cannulation [1]. Ultrasound guided cannulation procedure requires a specialist to scan for blood vessels and manually identify them in the obtained image. The image analysis tools assisting the specialist to identify and track vessels are highly welcome. The study aims – to develop real-time vessel detection algorithm assisting the ultrasound guided vein cannulation procedure.

Material and Methods

Vessel detection algorithm was developed on the basis of convolutional neural network (CNN) YOLOv2. Database for CNN training was collected and consisted of 4148 B mode images and annotations. Database were divided into parts 60/40 % for training and validation purposes. Algorithm was trained in the MATLAB environment and later deployed into C++ DLL library for faster execution.

Results

Algorithm performance metrics showed vessels detection average precision – 87.5 %, accuracy expressed by F-score = 86.2 %, and execution time <20 ms in C++ environment.

Conclusions

Real-time algorithm for vessel detection was developed. It detects close to 90 % of vessels in the images. Algorithm tracks the vessels during scanning and allows operator easily identify them.

References

- [1] C. Ayoub, C. Lavallée, A. Denault. Ultrasound guidance for internal jugular vein cannulation: Continuing Professional Development. Canadian Journal of Anesthesia, 57, p. 500-514, 2010.

A RARE CAUSE OF NECK MASS IN AN ADULT WOMAN-CERVICAL THYMIC CYST-CASE REPORT

**Golu Ioana¹, Melania Balas², Daniela Amzar², Icma Ioan³,
Marioara Cornianu⁴, Vlad Mihaela¹**

1. University of Medicine and Endocrinology "Victor Babes" Timisoara, Department II, Endocrinology,
2. University of Medicine and Endocrinology "Victor Babes" Timisoara, Department II, Endocrinology,
3. Contry Hospital Timisoara, Clinic of Surgery III, 4. University of Medicine and Endocrinology "Victor Babes"
Timisoara, Department of Morphopatology

Abstract body

Background: Cervical thymic cysts (CTCs) develop from the thymopharyngeal duct, representing less than 0.5% of all neck masses. Most of the cases are diagnosed in the first decade of life, being rarely described in adults. The majority of CTCs are located on the left side, the rest can develop on the right side or in the midline. The mechanisms of CTCs occurrence are still debated, failure of involution of thymopharyngeal duct, arrest in migration or retained thymic tissue during descent, being considered.

Case presentation: We report a case of 49-year-old woman who presented a left laterocervical mass, with rapid growth over several months. The lump was soft, mobile and painless, no other abnormalities were noticed. The ultrasound described an anechoic nodule of 57/38/63 mm at the inferior pole of the left thyroid lobe, raising the suspicion of a parathyroid cyst or branchial cyst. Contrast-enhanced CT scan confirmed the well-defined, cystic lesion of 35/25 mm, located between the trachea and common carotid artery, being delimited inferiorly by the left brachiocephalic vein. The aspiration of the cyst resulted in 40 ml of water-clear fluid, the cytology examination showed no thyroid or parathyroid cells. Surgery was performed, the pathological diagnosis confirmed the CTC.

Conclusion: Although the thymic cyst is a very rare cause of a cervical mass in adult, the diagnosis should be kept in mind, based on clinical presentation, ultrasound and CT features, respectively aspirated fluid characteristics.

References

Fiorella Calabrese et al. The Rarest of Rare Thymic Lesions: A 10-Year Surgical Pathology Experience. Cancers 2021, 13(16), 4056;

DYNAMICS OF ULTRASOUND PARAMETERS OF CAROTID ATHEROSCLEROSIS IN PATIENTS WITH MODERATE SCORE RISK: 7-YEAR FOLLOW-UP DATA

**Olga Pogorelova¹, Maria Tripoten¹, Leyla Khamchieva¹, Ivan Melnikov¹,
Sergey Kozlov¹, Tatyana Balakhonova¹**

1. NATIONAL MEDICAL RESEARCH CENTRE OF CARDIOLOGY NAMED
AFTER ACADEMICIAN E.I. CHAZOV.

Abstract body

Aim. To assess the dynamics of atherosclerotic plaque burden and echogenicity of carotid plaques (CP) in patients with moderate SCORE risk based on a 7-year follow-up.

Methods. 80 patients (47m/33f) 53.1±5.8 years old with 1-4% SCORE risk, LDL-C 2.7-4.8 mmol/l, and subclinical CA atherosclerosis (<50% stenosis) were studied. All patients received atorvastatin 10-40 mg to achieve LDL-C level <2.6 mmol/l and were followed up for 7 years. CP number, total stenosis, plaque score, visual greyscale morphology, and grey-scale median (GSM) were measured at baseline and after 7 years.

Results. There was a significant increase in the number of CP from 188 to 251, the plaque score from 5.63±4.28 to 7.58±4.71 mm, the average number of CP per patient from 2.4±1.3 to 3.1±1.5, total stenosis from 69±47 to 92±52% ($p<0.05$ for all). Visual greyscale morphology assessment showed a significant increase in the number of echogenic CPs ($p=0.00001$), calcified CPs ($p=0.02$), CPs with smooth surface ($p=0.06$), and a decrease in the number of echolucent CPs ($p=0.03$). Analysis of GSM measurements demonstrated a significant increase in GSM from 65 to 74 ($p<0.0001$), Δ GSM was 5.1, Δ GSM% 7.7%. There was no significant dependence of Δ GSM on Δ LDL-C and baseline level hsCRP, Δ GSM% on Δ LDL-C% ($p>0.05$ for all).

Conclusion. Stabilization of the structure of CPs was noted with an increase in atherosclerotic plaque burden for patients with subclinical carotid atherosclerosis and moderate SCORE risk.

References

Ibrahimi P. et al. Ultrasound assessment of carotid plaque echogenicity response to statin therapy: a systematic review and meta-analysis. Int J Mol Sci 2015, 16, 10734-10747.

CEUS LI-RADS AND QUANTIFICATION SOFTWARE: EVALUATION OF THE AGREEMENT IN CLASSIFYING LIVER NODULES INTO LI-RADS CLASSES

***Alice Giamperoli*¹, Eleonora Terzi², Antonella Forgione¹, Vito Sansone³, Lorenzo Mulazzani⁴, Fabio Piscaglia¹**

1. Department of Medical and Surgical Sciences, University of Bologna, 40138 Bologna, Italy, 2. Division of Internal Medicine, Hepatobiliary and Immunoallergic Diseases, IRCCS Azienda Ospedaliero Universitaria di Bologna, 40138 Bologna, Italy, 3. Department of Medical and Surgical Sciences, University of Bologna, 40138 Bologna, Italy, 4. Emergency Dept, Medicina d'Urgenza e Pronto Soccorso, IRCCS Azienda Ospedaliero-Universitaria di Bologna, Bologna, Italy

Abstract body

Actuality and aim

CEUS LI-RADS scheme categorizes liver nodules in high-risk patients according to their degree of risk to be HCC. LI-RADS algorithm classifies nodules in various groups according to their enhancement in comparison with liver parenchyma in different vascular phases¹. We used a prototype of software to quantify the enhancement during the CEUS acquisition to estimate intra-operator, inter-operator and software-operator agreement in classifying liver nodules into LI-RADS classes.

Material and Methods

We analyzed 30 nodules submitted to CEUS in our Center. CEUS clips and images were judged by two operators on two occasions visually then with the software quantification analysis. The ratio between the nodule's enhancement and that of the parenchyma provided by the software was classified as hyperenhancement for a ratio ≥ 1.2 , isoenhancement for a ratio between 0.8 and 1.2 and hypoenhancement for a ratio ≤ 0.8 .

Using Cohen's kappa coefficient (κ) of reproducibility we compared CEUS LI-RADS intra-operator, inter-operators and software-operator agreements.

Results

Intra-operator agreement in evaluating LI-RADS classes was almost perfect for each operator, with $\kappa > 0.8$ ($p < 0.001$). Interobserver agreement in adjudicating CEUS-LI RADS resulted almost perfect, with $\kappa > 0.8$. The agreement between each operator's impression and software's analysis in evaluating LI-RADS classes was moderate for operator 1 ($\kappa = 0.42$) and substantial for operator 2 ($\kappa = 0.77$).

Conclusions

The reproducibility of the operators' visual impression in CEUS evaluating liver nodules was high. However, there was some discordance between an operator's impression and software quantification. Further assessments are needed to verify whether the software quantification improves diagnostic accuracy.

References

1. <https://www.acr.org/Quality-Safety/Resources/LIRADS>

CAROTID SUBCLINICAL ATHEROSCLEROSIS AND ADVERSE CARDIOVASCULAR EVENTS: DATA FROM A 10-YEAR FOLLOW-UP

***Olga Pogorelova*¹, Maria Smirnova¹, Tatyana Fofanova¹, Maria Tripoten¹, Olga Svirida¹, Zoya Blankova¹, Elena Yarovaya¹, Fail Ageev¹, Tatyana Balakhonova¹**

1. NATIONAL MEDICAL RESEARCH CENTRE OF CARDIOLOGY NAMED
AFTER ACADEMICIAN E.I. CHAZOV

Abstract body

Aim. To assess the contribution of subclinical atherosclerosis to CVD development in patients at low-to-moderate SCORE risk.

Methods. We studied 379 patients with low-to-moderate SCORE risk (51,1±7,5 years, 82 male, 297 female). In 2009, all patients underwent clinical and carotid ultrasound examination. Plaques were counted along common carotid arteries (CCA), CCA bifurcations, and internal carotid arteries. Total stenosis was the sum of stenoses in 6 CA segments(%). IMT in the distal CCA far wall was automatically measured using QLab extended module.

Results. During the 10-year observation period, 22,4% patients experienced various CVEs (CVE+). Plaques 20-50% were detected in 79,94%. CVE+ and CVE- patients differed in systolic BP and triglycerides but not in diastolic BP, lipid profile, smoking, sex, age. The CVE+ had significantly higher CCA IMT (0,65[0,64;0,70] vs 0,62[0,62; 0,66] mm, p<0,05), total CA stenosis (102,5 [88,1; 120,8] vs 80[72,5; 88,1]%, p=0,01), plaque frequency (87,1% vs 77,9 %, p=0,06) and CA plaque number (4,0[2,8; 3,9] vs 3,0[2,6; 3,1], p=0,01). A ROC-analysis revealed a cut-off point of 82,5% for total CA stenosis (AUC=0,598, 95%CI 0,5243-0,673, p<0,05), 25% for right CCA stenosis of 25% (AUC=0,593, 95%CI 0,516-0,670, p<0,05), 25% for left CCA stenosis (AUC=0,604, 95%CI 0,529-0,678, p<0,05).

Total CA stenosis was an independent predictor of CVEs when adjusted for sex, age, SBP, DBP ($\beta=0,149$; p<0,05). Total CA stenosis>82,5% increases the risk of CVEs by 79%(OR 1,79(1,103-3,125)).

Conclusion. The total CA stenosis predicted CVEs in patients with low-to-moderate SCORE risk on 10-year follow-up.

References

Sillesen H., Muntendam P. et al. JACC Cardiovasc Imaging. 2012;5:681-9.

ECHOGENICITY OF ATHEROSCLEROTIC PLAQUES OF CAROTID ARTERIES AND PROGNOSIS OF CARDIOVASCULAR EVENTS

Maria Tripoten¹, **Olga Pogorelova**², **Dinara Guchaeva**², **Roman Shakhnovich**²,
Mikhail Ruda², **Tatyana Balakhonova**²

1. NATIONAL MEDICAL RESEARCH CENTRE OF CARDIOLOGY NAMED AFTER
ACADEMICIAN E.I.CHAZOV, 2. NATIONAL MEDICAL RESEARCH CENTRE
OF CARDIOLOGY NAMED AFTER ACADEMICIAN E.I.CHAZOV.

Abstract body

Aim: evaluate atherosclerotic carotid plaque (ASP) GSM in patients with acute coronary syndrome (ACS) and GSM prognostic implications for MACE risk.

Methods: 143 patients with ACS (32-83 years) were evaluated. The first carotid ultrasound examination was on days 1-5 following admission to the hospital, the second after 1-1.5 years. GSM of ASP was assessed on the computer semi-automated workstation (Fig.1).

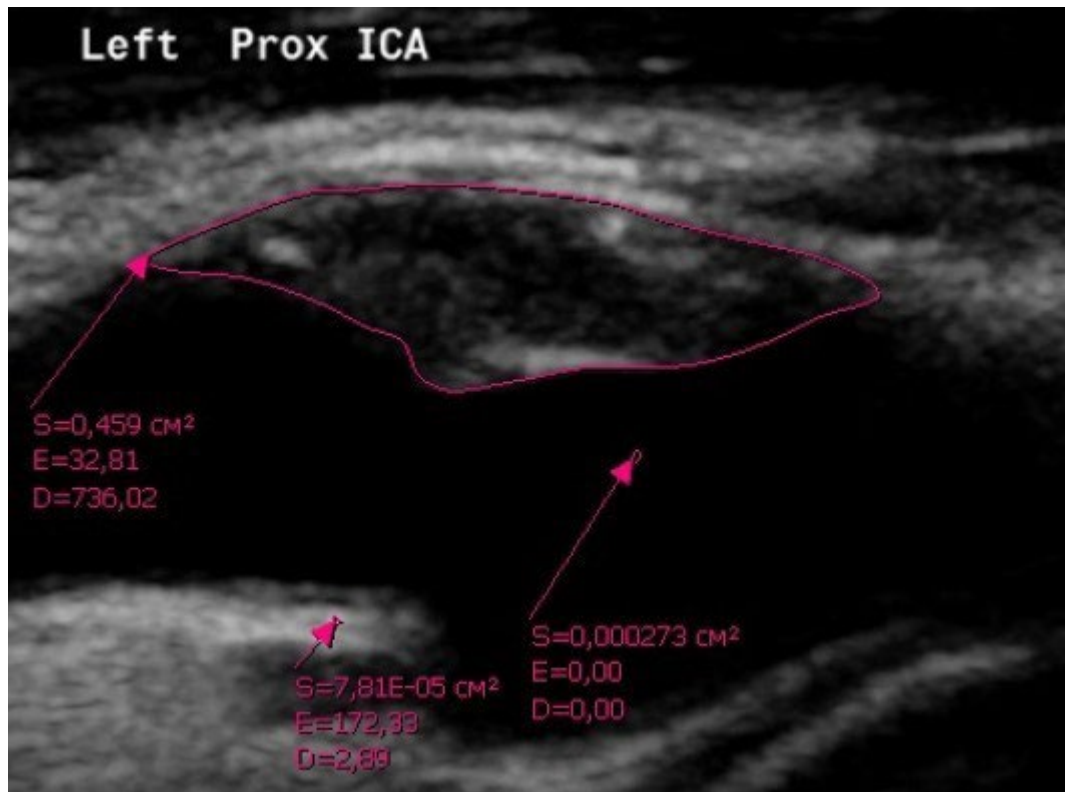
Results: We have reviewed 379 ASP. Analysis of GSM measurements on visits 1 and 2 demonstrated a significant increase of carotid plaque GSM: 49.3[39.7;63.6] vs 50.7[40.1;66.5], $p<0.05$. During the observation period 23% patients experienced various MACE (e.g. MI). Comparative assessment of changes in carotid plaque GSM in patients with or without MACE showed significant differences: plaque GSM decrease in patients with MACE, by 3.33 (7.8%, $p<0.05$) vs plaque GSM increase in patients without MACE, by 2.75 (6.1%, $p<0.05$). ROC analysis showed that a relative reduction GSM by predicts an adverse outcome with the sensitivity of 53.5% and specificity of 71.1% (AUC 0.628 ± 0.0465 (95% CI 0.556 – 0.696), $p=0.006$). The risk of MACE increased 2.16-fold with carotid plaque GSM decrease by $\geq 6.96\%$ (HR=2.16; 95% CI=1.331-3.507; $p=0.009$).

Conclusions: our data indicate the importance of assessment of the echogenicity of ASP in carotid arteries in dynamics in patients who underwent ACS. Decrease of carotid plaque echogenicity over time in post-ACS patients may predict adverse outcomes and should justify treatment adjustments.

References

Honda O. et al. Echolucent carotid plaques predict future coronary events in patients with coronary artery disease. J Am Coll Cardiology. 2004;43:1177-84.

ECHOGENICITY OF ATHEROSCLEROTIC PLAQUES OF CAROTID ARTERIES AND PROGNOSIS OF CARDIOVASCULAR EVENTS



Determination of the echogenicity of the carotid atherosclerotic plaque.

EFFECT OF NANO-SCALED PHASE CHANGE AGENT ACTIVATION ON HEPATOCELLULAR CARCINOMA TUMOR ENVIRONMENT

John Eisenbrey¹, ***Hebah Falatah***¹, ***Quezia Lacerda***¹,
Corinne Wessner¹, ***Ji-Bin Liu***¹

1. Thomas Jefferson University

Abstract body

Actuality and aim: Recent studies have used ultrasound-stimulated microbubbles (USMB) to target tumor vasculature to alter tumor blood flow and enhance the effect of both chemo- and radiation therapy. These combination treatments have shown an improvement in both preclinical and clinical trials. While the size of MB (1-8 μm) allows them to pass pulmonary capillaries, they are still restricted to the vasculature. Nano-scale phase change contrast agents (n-PCCA) are small enough to extravasate to the tumor interstitial space due to their size and the enhanced permeability and retention effect. Hence the purpose of this study was to investigate the impact of n-PCCA on hepatocellular carcinoma (HCC) tumor environment. Methodology: Definity (Lantheus Medical Imaging) was condensed to prepare n-PCCA. For proof of concept, two nude mice with HCC were injected with n-PCCA and activated by ultrasound ($\text{MI} > 0.5$). Volumetric photoacoustic and power Doppler imaging was performed using a Vevo 3100 system before and after treatment to analyze changes in tumor vascularity and oxygen saturation. Results: n-PCCA activation was well visualized in the tumors following ultrasound-triggering. The average oxygen saturation and fractional vascularity were decreased after treatment from $74.0 \pm 56\%$ to $58.9 \pm 3.0\%$ and $27.9 \pm 6.0\%$ to $9.1 \pm 2.4\%$, respectively, indicating substantial alteration of the tumor microenvironment. Conclusion: This work demonstrated that n-PCCA mediated the tumor environment using ultrasound which may be beneficial for augmenting therapy in future trials. Acknowledgment: Funding for this work was provided in part by the United States National Institute of Health grant R01 EB026881

References

LIVER AND SPLEEN SHEAR-WAVE ELASTOGRAPHY IN THE DIAGNOSIS AND SEVERITY STAGING OF PHILADELPHIA-NEGATIVE MYELOPROLIFERATIVE DISEASES AND MYELOFIBROSIS

Vito Sansone¹, Giuseppe Auteri², Francesco Tovoli¹, Camilla Mazzoni², Simona Paglia², Daniela Bartoletti², Christian Di Pietro², Nicola Vianelli², Michele Cavo², Francesca Palandri², Fabio Piscaglia²

1. Division of Internal Medicine, Hepatobiliary and Immunoallergic Diseases, IRCCS Azienda Ospedaliero-Universitaria di Bologna; Department of Medical and Surgical Sciences (DIMEC), University of Bologna, 2. IRCCS Azienda Ospedaliero-Universitaria di Bologna, Istituto di Ematologia "Seràgnoli", Bologna, Italy; Dipartimento di Medicina Specialistica, Diagnostica e Sperimentale, Università di Bologna, Bologna, Italy

Abstract body

Actuality and aim: Spleen and liver stiffness, investigated by transient elastography (TE), have been proved different between myeloproliferative neoplasms (MPNs): Myelofibrosis (MF), polycythemia vera (PV) and essential thrombocythemia (ET), and can be assessed by point and 2D shear wave elastography (pSWE and 2DSWE). Aims of this study are: 1) identify TE differences between MPN pts, cirrhotics and healthy volunteers (HV); 2) establish a correlation with bone marrow fibrosis (BMF) grade in MPN patients.

Methods: MPN, cirrhotics, pts and HV received elastometric evaluation of spleen and liver stiffness by pSWE and 2DSWE, along with a full US evaluation.

Results: Patients characteristic are shown in Figure 1.

Compared to HV, ET and PV patients, MF patients had greater spleen stiffness and liver stiffness ($p < 0.001$) (Figure 2 and 3)

Notably, higher liver and spleen stiffness were associated with increased BMF grade: in low (0-1) ($n=81$, 60.4%) versus high grade fibrosis (2-3) ($n=42$, 39.6%), is evident a higher median stiffness in patients with higher grades of bone marrow fibrosis both for liver (pSWE 5.2 vs 6.65 kPa; 2DSWE 5.1 vs 6.05 kPa) and spleen (pSWE 27.2 vs 37.9 kPa, 2DSWE 21.7 vs 30.75 kPa - $p < 0.001$ in both tests).

Conclusions: TE evaluation effectively distinguishes MF pts from HV and ET/PV and is significantly associated with prognostically relevant features, helping in MPN diagnosis and providing guidance, being associated with known prognostic factors.

References

Iurlo et al, Br J Haematol. 2015

Webb et al, Ultrasound Q. 2015

Benedetti et al, J Clin Med. 2020

LIVER AND SPLEEN SHEAR-WAVE ELASTOGRAPHY IN THE DIAGNOSIS AND SEVERITY STAGING OF PHILADELPHIA-NEGATIVE MYELOPROLIFERATIVE DISEASES AND MYELOFIBROSIS

Characteristic	MF (n=68)	PV (n=33)	ET (n=46)
Median age, yrs (range)	71.9 (44-83.6)	62.4 (27-81)	66.4 (20.8-86.6)
Male sex, n (%)	38 (55.9%)	22 (66.7%)	19 (41.3%)
Leukocyte (x10 ⁹ /L)	12 (1.8-60.2)	8.3 (2.1-18.3)	7.1 (3.4-15.6)
Hemoglobin (g/dL)	10.4 (6.7-16.9)	13.9 (10.9-16.6)	13.3 (9.4-16.9)
Platelet (x10 ⁹ /L)	210 (18-79)	386 (136-479)	369 (19-180)
Previous thrombosis, no (%)	15 (22.1%)	3 (9.1%)	10 (21.5%)
Previous splenic vein thrombosis, no (%)	9 (13.2%)	2 (6.1%)	1 (2.2%)
Marrow fibrosis, no (%) as available			
grade 0	1/56 (1.8%)	12/17 (70.6%)	23/34 (67.6%)
grade 1	14/56 (25.0%)	3/17 (17.6%)	11/34 (32.4%)
grade 2	18/56 (32.1%)	0	0
grade 3	22/56 (39.3%)	0	0
Ongoing therapy, no (%)			
Cytoreductive	10 (14.7%)	20 (60.6%)	36 (78.3%)
Interferon	1 (1.5%)	3 (9.1%)	2 (4.3%)
JAK2 inhibitor	25 (36.8%)	2 (6.1%)	0
No therapy	10 (14.7%)	8 (24.2%)	8 (17.4%)
Median total symptom score	15 (0-48)	3 (0-15)	-
DEFS, no (%)			
low	5 (7.4%)	-	-
intermediate-1	22 (32.4%)	-	-
intermediate-2	18 (26.5%)	-	-
high	7 (10.4%)	-	-
Palpable spleen, cm BCLM	5 (0-28)	0 (0-8)	0
≥1 BCR mutation, no	11/23	-	-
Median time from diagnosis, mo	3.7 (1-25.3)	4.1 (1.3-37.1)	6.6 (1-260.7)
Median PVD (mm)	12 (3.7-21.4)	10.7 (6.6-18)	8.4 (7.1-13.8)
Median STD (mm)	8.2 (4.7-22.7)	7.3 (4.2-20)	7.2 (4-11)

Figure 1

LIVERPOINTSWE (kPa)					LIVER2DSWE (kPa)				
Aetiology	N	MEAN	MEDIAN	95% CI MEDIAN LOWER UPPER	MEAN	MEDIAN	95% CI MEDIAN LOWER UPPER		
MF	64	7,72±4,2	6,65	6,40	7,00	6,96±3,2	6,10	5,60	6,80
HV	75	5,52±3,5	5,00	4,50	5,90	5,01±2,2	4,62	4,30	5,00
PV	33	5,73±3,5	5,40	4,90	6,20	5,32±3,1	5,00	4,90	6,00
TE	46	5,44±2,5	4,85	4,70	5,70	5,23±2,3	4,85	4,40	5,30
CIR	18	20,57±2,38	17,65	14,00	26,20	19,94±3,04	15,05	11,80	24,20

Figure 2

SPLEENPOINTSWE (kPa)					SPLEEN2DSWE (kPa)				
Aetiology	N	MEAN	MEDIAN	95% CI MEDIAN LOWER UPPER	MEAN	MEDIAN	95% CI MEDIAN LOWER UPPER		
MF	64	40,9±2,138,0	41,4	33,1	34,9±2,1	31,7	26,2	34,3	
HV	75	26,3±1,423,4	25,2	21,4	20,1±,7	18,7	17,6	21,1	
PV	33	31,5±2,131,1	33,1	26,0	24,6±1,5	22,3	19,7	26,5	
TE	46	26,7±1,626,4	29,3	21,7	22,8±1,2	21,1	19,2	25,2	
CIR	18	45,6±4,849,5	63,0	35,2	39,4±3,0	40,9	33,4	45,7	

Figure 3

DIAGNOSTIC LESSONS FROM RAPHAEL'S “LA FORNARINA” POINT TO THE POTENTIAL FOR E-DIAGNOSIS IN CONTEMPORARY CASES OF BREAST CANCER

***Marcin Śniadecki*¹, Paulina Jaworek¹, Weronika Ciećko², Zuzanna Boyke³,
Ewa Bandurska², Paweł Guzik⁴, Maria Stasiak⁵, Marcin Liro⁵, Jakub Szalek⁶**

1. Department of Gynecology and Obstetrics, Medical University of Gdansk, 2. Center for Competence Development, Integrated Care and e-Health, Medical University of Gdansk, Poland, 3. Department of Art History, Faculty of History, University of Gdansk, 4. Clinical Department of Gynecology and Obstetrics, City Hospital Rzeszow, Poland, 5. Department of Gynecology and Obstetrics, Medical University of Gdansk, Poland, 6. Faculty of Social Sciences, Pontifical University of John Paul II in Krakow, Poland

Abstract body

A little over 500 years ago, Raphael created one of his last paintings, La Fornarina. Whether consciously or not, this portrait of his mistress Margarita Luti poignantly indicates possible breast cancer, starting a diagnostic discussion that has lasted to the present. Almost at the same time, Albrecht Dürer sent a self-portrait indicating where he was in pain to his doctor. Therefore, these Renaissance images attract scrutiny through the dual prisms of art and medicine. Looking at each, we see that beyond portraiture, the images also communicate information about symptoms of a disease for the purpose of remote diagnosis; a practice that underpins today's telemedicine and e-diagnostics. Even the historic painting processes used to create La Fornarina have their parallels in modern medical research methods. Although we have very advanced diagnostic tools today, our diagnoses are still based on similar visual stimuli as in the past, including the use of colours (hues and tints) as the basic means of communication. However, we have also gone much further with new imaging techniques, as in Jagiellonian Positron Emission Tomography (J-PET) tomography for instance. Our article also emphasizes new insights gained about the value of remote diagnostics through recent experience of the coronavirus disease 2019 (COVID-19) pandemic. We look to the future, and to the potential for new e-diagnosis opportunities that include technology-assisted self-examination and self-portraiture by patients. Finally, e-diagnostics can address the growing number of young breast cancer patients who choose remote communication tools more often than previous generations.

References

References in poster

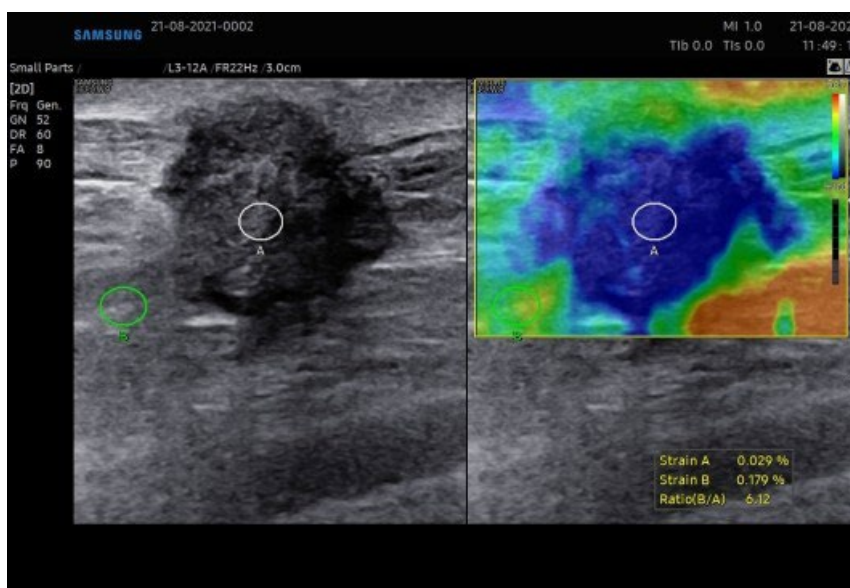
DIAGNOSTIC LESSONS FROM RAPHAEL'S “LA FORNARINA” POINT TO THE POTENTIAL FOR E-DIAGNOSIS IN CONTEMPORARY CASES OF BREAST CANCER



Rafael Sanzio, “La Fornarina”, oil on wood panel, 1520



Albrecht Dürer, self-portrait, pen, brown India ink and watercolor on paper, 1509-1515



B-mode; hypoechoic lesion with blurred margins, Tsukuba grade 5; strain ratio: 6.12; NOS

COMPLEX BREAST CYSTS (CBC): ULTRASOUND (US) OR PNEUMOCYSTOGRAPHY (PCG)

Oleksii Aksonov¹, Olena Aksonova², Gennady Belonenko²

1. National Cancer Institute, Kiev, 2. T. Shevchenko National University, Kyiv, Ukraine

Abstract body

Actuality. CBCs are characterized by a high probability of malignancy and require a biopsy, usually under US guidance. However, with atypical echosemiotics, difficult positioning, and, above all, with the disappearance of the visualization of the CBC after fine-needle aspiration, the possibilities of US guidance for core-needle biopsy (CNB) are reduced. The navigational capabilities of the GPC have not been studied. The aim of this publication was to analyze the effectiveness of US and PCG in CBC.

Material and methods. In 112 adult women with CBC, the results of US and PCG were analyzed. Diagnostic efficiency indicators were calculated using standard formulas. The reference method was cytology.

Results. A high (21.4%) frequency of false-negative US results was revealed. The frequency of false-negative results (22.3%), diagnostic accuracy (58.9%) and predictive value of a negative result (69.5%) of PCG were inferior to those with US by 0.9 - 5.4 and 2.6%, respectively.

In 8 patients, in the presence of technical obstacles for US-guided CNB, stereotaxis under the control of PCG was performed. X-ray signs of malignancy (thickened walls, internal septa, filling defects) were used as targets for navigation. The histopathology findings were benign, which avoided an open biopsy.

References

Conclusion. In CBCs, the diagnostic performance of US and PCG is quite comparable. In limitations of US-guided CNB, PCG-guided stereotaxis may be an alternative. Further research is needed on the possibilities of PCG for preoperative verification of CBC without open biopsy.

CRYSTAL DEPOSITIONS ASSESSED BY ULTRASOUND AND DECT DECREASE DURING TWO YEARS OF TREAT-TO-TARGET TREATMENT

Hilde Berner Hammer¹, Lars F. Karoliussen¹, Tron H. Eskild¹, Lene Terslev²,
Espen H. Haavardsholm¹, Till Uhlig¹

1. Diakonhjemmet Hospital, Oslo, 2. Rigshospitalet, Glostrup, Copenhagen

Abstract body

Background

Gout is caused by depositions of monosodium uric acid crystals in joints/tissues which triggers highly painful flares. Serum urate lowering treatment(ULT) reduces the number of flares.

Objective

To explore the change of crystal depositions assessed by ultrasound and dual energy computer tomography (DECT) for two years, and its associations with flare during the first year of ULT.

Methods

Patients with recent crystal-proven gout and serum uric acid(sUA) level ($>360\mu\text{mol/L}$) were consecutively included [1], ULT given to achieve $\text{sUA}<360\mu\text{mol/L}$ and flare prophylaxis 3-6 months. Comprehensive ultrasound assessments (GE-E9) performed at baseline, 12 and 24 months (semi-quantitative scoring of double contour(DC), tophi and aggregates) and DECT (GE-Discovery CT750/HD) of both feet. Comparisons were performed by Wilcoxon/Mann-Whitney. Logistic regression explored prediction of flare.

Results

209 patients were included (mean age 56.4years, disease duration 7.9years, 95.5% men). Patients with flares had higher US and DECT scores ($p<0.05$). The total sum scores of US(DC, tophi and aggregates) and DECT decreased during the study ($p<0.001$ for all, table 1). Figure1 shows the parallel decrease of depositions in feet by US and DECT (all changes $p<0.001$). At least one flare was seen in 81% the first year, but only in 26% the second year. Baseline DC/ sum score predicted flare the first 3 months ($p=0.031/0.047$) and baseline DECT predicted flare at 3/12 months ($p=0.014/0.010$).

Conclusion

Crystal depositions in both imaging modalities decreased substantially during ULT as did occurrence of flare. Baseline US and DECT depositions predicted flare during follow-up.

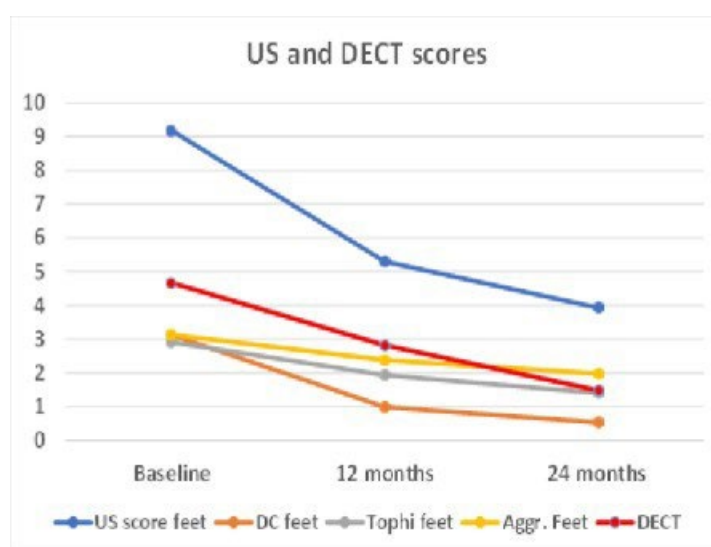
References

1. HammerHB et al. AnnRheumDis-2020

CRYSTAL DEPOSITIONS ASSESSED BY ULTRASOUND AND DECT DECREASE DURING TWO YEARS OF TREAT-TO-TARGET TREATMENT

Sum scores	Baseline	12 months	24 months
Ultrasound - Double contour	4.3 (3.5)	1.3 (2.2)	0.7 (1.4)
Ultrasound - Tophi	6.5 (6.5)	3.8 (5.2)	2.4 (3.7)
Ultrasound - Aggregates	9.3 (5.6)	6.7 (5.1)	5.5 (4.7)
Ultrasound - Double contour, Tophi, Aggregates	20.0 (13.9)	11.7 (11.3)	8.6 (8.8)
Dual energy computer tomography (DECT)	4.7 (6.4)	2.8 (4.8)	1.5 (3.2)

Mean (SD) of ultrasound and DECT scores.



Ultrasound scores and DECT only from feet.

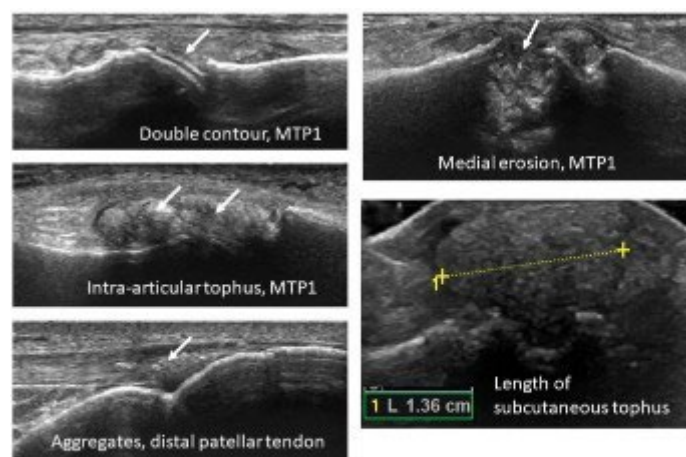


Figure 1.
Double contour in MTP1 (score 3), tophus in MTP1 (score 3), intratendinous aggregates distal patellar tendon (score 2), erosion medially MTP1 (score 3) and measurement of the length of a subcutaneous tophus superficial to PIP of the 2.toe.

Ultrasound elementary lesions of crystal depositions.

NOT ALL THAT TWINKLES IS GOLD

Rykiel Levine¹, William Jian¹

1. University Hospitals Cleveland Medical Center

Abstract body

53 year old male presented to the emergency department for decreased urinary stream. While evaluating the patient, point of care ultrasound was performed of the renal system and demonstrated no hydronephrosis bilaterally and a bladder with approximately 110 ml urine. It also demonstrated a small hyper echoic object noted with connection to the bladder with a positive twinkle sign.

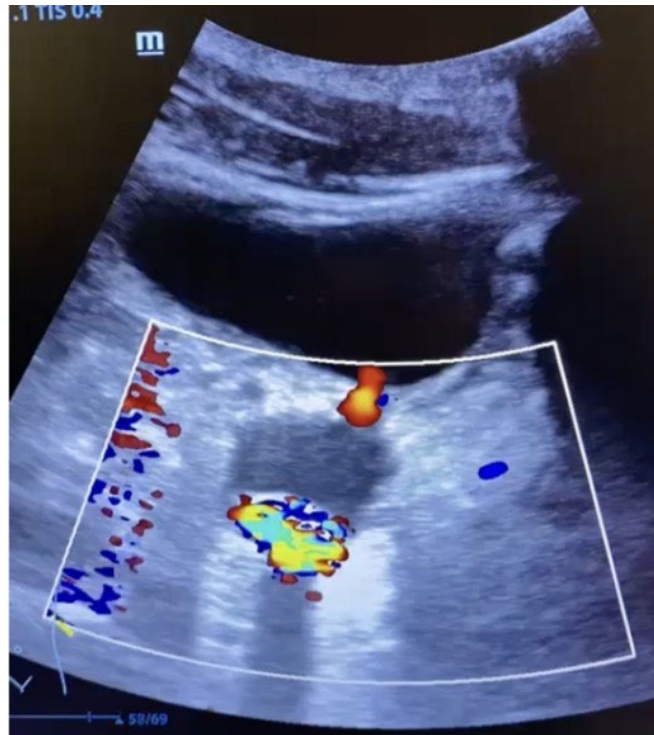
The man with difficulty voiding was found to have a hyper echoic object that was “twinkling” when color flow doppler was applied. This twinkle artifact, which focuses on alternating colors behind a rough reflective object appearing as turbulent flow, allowed the providers to conclude that this object was a large stone obstructing urinary outflow. The twinkle sign has been studied in other pathology, however it is most noteworthy in use for nephrolithiasis, indicating a calcified object that may not have acoustic shadowing or may not otherwise be clear due to surrounding greyscale. There are other applications of using the twinkle sign for diagnosis, and recognizing it and correlating clinically can help save patients time, radiation, and further discomfort in the emergency department.

With the added benefit of a twinkle sign, the providers were able to recognize a bladder stone and consult the appropriate specialists. Though ultimately a CT scan was obtained, the diagnosis was made by POCUS and the patient was given appropriate care as a result. This patient was having decreased urine output due to large amounts of urine trapped behind the stone which is completely novel and uncommon.

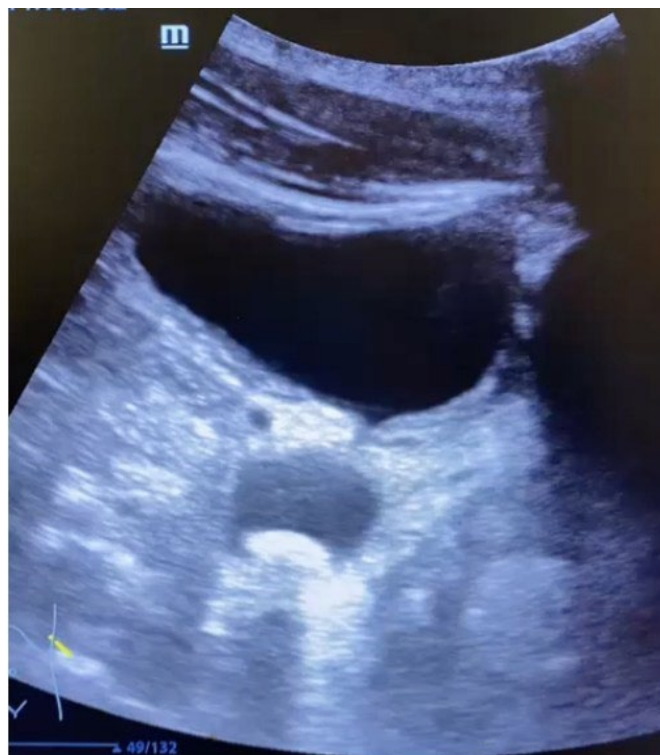References

<https://www.sciencedirect.com/science/article/pii/S0378603X14000254>

NOT ALL THAT TWINKLES IS GOLD



Twinkle sign on stone.



Bladder diverticulum stone isolated.

ULTRASOUND BASED MACHINE LEARNING APPROACH FOR DETECTION OF NON-ALCOHOLIC FATTY LIVER DISEASE

**Aylin Tahmasebi¹, Shuo Wang², Corinne Wessner², Ji-Bin Liu², Flemming
Forsberg², Jesse Civan¹, Flavius Guglielmo², John Eisenbrey²**

1. Thomas Jefferson university, 2. Thomas Jefferson University

Abstract body

Actuality and aim, this prospective study explored the use of ultrasound with artificial intelligence for the detection of non alcoholic fatty liver disease (NAFLD).

Methods, One hundred and twenty subjects with clinical suspicion of NAFLD and 10 healthy volunteers consented to participate in this IRB-approved study. Subjects were categorized as NAFLD and Non-NAFLD according to MR proton density fat fraction (PDF) findings as the reference standard with >6.4% indicative of NAFLD. Ultrasound images from 10 different locations in the right and left hepatic lobes were collected following a standard protocol. A supervised machine learning model was developed for assessment of NAFLD. To validate model performance, a balanced testing dataset of 24 subjects was used. Sensitivity, specificity, positive predictive value, negative predictive value and overall accuracy with 95% confidence interval (CI) were calculated.

Results, A total of 1,119 images from 106 participants was used for model development. The internal evaluation achieved an average precision of 0.941, recall of 88.2% and precision of 89.0%. In the testing set AutoML achieved a sensitivity of 72.2% (63.1-80.1%), specificity of 94.6% (88.7-98.0%), PPV of 93.1% (86.0-96.7%), NPV of 77.3% (71.6-82.1%) and accuracy of 83.4% (77.9-88.0%). The average agreement for an individual subject was 92%.

Conclusion, An ultrasound-based machine learning model for identification of NAFLD showed high specificity and PPV in this prospective trial. This approach may in the future be used as an inexpensive and noninvasive screening tool for identifying NAFLD in high-risk patients.

Acknowledgement, GE Healthcare

References

n/a

MULTIPARAMETER CONTRAST-ENHANCED ULTRASOUND FOR DIFFUSE AND FOCAL LESIONS OF LIVER PARENCHYMA IN PATIENTS WITH DIABETES MELLITUS

***Rostyslav Bubnov*¹, Oleksandr Mukhomor¹**

1. Clinical hospital "Pheophania"

Abstract body

Background and Aims

Diabetes mellitus (DM) can cause diffuse and focal lesions of liver. Enhancing ultrasound (US) with modalities like sonoelastography and contrast-enhanced ultrasound (CEUS) can dramatically increase its quality.

The Aim was to study relevance of CEUS to evaluate liver parenchyma in patients with DM type 2.

Methods

We included 43 patients (22 females; aged 23 to 72 years): 23 patients with DM2 and fatty liver (NAFLD; LF1-3); and 20 healthy controls. Patients with cancer, chronic hepatitis, bile stones, obstructive jaundice were excluded from the study. All patients underwent general clinical, lab tests; multiparameter US of liver, Doppler, noninvasive flow evaluation, measuring SWE of liver parenchyma (Applio). In 2 patients, who presented heterogenic pattern of liver parenchyma and suspicious to lesions we did CEUS (SonoVue, Bracco Imaging).

Results

We detected common US signs of fatty liver: right liver lobe size was 166 ± 9 mm vs 133 ± 8 mm in controls; SWE was 7.4 ± 1.7 kPa (6-13 kPa) vs 4.2 ± 0.8 kPa in controls; in focal lesions isoechoic in grey scale CEUS showed contrast cumulation in venous phase, and SWE showed increased stiffness to 8-11 kPa. CEUS and noninvasive flow evaluation helped to display complex vasculature, low vascularization, visualize vascular flow in areas of heterogeneity on grey scale.

Conclusions

Multiparameter US is effective for evaluating liver parenchyma in patients with DM type 2. CEUS helped in accurate diagnosis in both diffuse and focal lesions in particular to detect hidden lesions.

References

1. Bubnov R, Mukhomor O. <https://doi.org/10.5152/tjg.2019.050919>

STEATOSIS ASSESSMENT BY ULTRASOUND DERIVED FAT FRACTION IN PATIENTS WITH ALD

Radu Cotrau¹, Anca Ariana Plopeanu¹, Alina Popescu¹, Raluca Lupusoru², Renata Bende¹, Camelia Foncea¹, Felix Bende¹, Roxana Sirli¹, Adrian Burdan¹, Darius Heredea¹, Ioan Sporea¹

1. Department of Gastroenterology and Hepatology, Department of Internal Medicine II, Center for Advanced Research in Gastroenterology and Hepatology "Victor Babes" University of Medicine and Pharmacy Timisoara 2 Center for Advanced Hepatology Research of the Academy of Medical Sciences, Timisoara, 2. Department of Gastroenterology and Hepatology, Department of Internal Medicine II, Center for Advanced Research in Gastroenterology and Hepatology "Victor Babes" University of Medicine and Pharmacy Timisoara 2 Center for Advanced Hepatology Research of the Academy of Medical Sciences, Timisoara 3 Center for Modeling Biological Systems and Data Analysis, Department of Functional Sciences, "Victor Babes" University of Medicine and Pharmacy Timisoara

Abstract body

Actuality and aim: Alcohol-associated liver disease (ALD) remains one of the leading causes of liver disease globally. Consequently, early detection and staging of steatosis is very important. The aim of our study was to evaluate a novel method for the diagnosis of steatosis by Ultrasound Derived Fat Fraction (UDFF) using CAP as a reference method.

Methods: A prospective study was conducted in which liver steatosis was assessed in 72 patients with ALD (92% males, mean age 56.63). In the same session we evaluated with Siemens ACUSON Sequoia using (Deep Abdominal Transducer-DAX) UDFF and FibroScan Compact M 530 (M and XL probes) with CAP, respectively. For CAP, reliable measurements were defined as the median value of 10 measurements with IQR/M<0.3. The cut-off value of 260 dB/m by CAP was considered as indicative for at least significant steatosis (S2-S3) [1].

Results: Reliable measurements by CAP and UDFF were obtained in 100% of cases. A good correlation was found between UDFF and CAP, $r=0.76$, $p<0.0001$. Using CAP as the reference method, 20% (15/74) of the subjects had S2 steatosis, and 45% (33/74) had S3 steatosis. The optimal UDFF cut-off values for predicting S2-S3 steatosis was $>6\%$ (AUROC=0.99, $p<0.0001$, Se=97.1%, Sp=100%, PPV=100%, NPV=94.7%).

Conclusion: Evaluation of steatosis using Siemens Acuson Sequoia UDFF is a feasible method for patients with ALD and correlates well with CAP measurements.

References

1. Thiele M et al. Controlled attenuation parameter and alcoholic hepatic steatosis: Diagnostic accuracy and role of alcohol detoxification. J Hepatol [Internet]. 2018;68(5):1025-32. Available from: <https://doi.org/10.1016/j.jhep.2017.12.029>

QUANTITATIVE ULTRASOUND METHODS FOR THE ASSESSMENT OF LIVER STEATOSIS IN PATIENTS WITH ALD

Anca Ariana Plopeanu¹, ***Alina Simona Popescu***¹, ***Renata Bende***¹, ***Radu Cotrau***¹,
Adrian Burdan¹, ***Darius Heredea***¹, ***Camelia Foncea***¹, ***Felix Bende***¹, ***Roxana Sirli***¹
, Daniela Trip¹, ***Ioan Sporea***¹

1. Department of Gastroenterology and Hepatology, Department of Internal Medicine II, Center for Advanced Research in Gastroenterology and Hepatology "Victor Babes" University of Medicine and Pharmacy Timisoara, Romania

Abstract body

Actuality and aim: The aim of our study was to evaluate the feasibility of two new quantitative ultrasound (QUS) parameters, TSI (tissue scatter-distribution imaging) and TAI (tissue attenuation imaging) for the rule in of steatosis in patients with ALD considering CAP as reference.

Methods: A prospective study was conducted in which liver steatosis was assessed in 50 patients with ALD (92% males, mean age 58.45), evaluated in the same session by QUS and CAP implemented on the following systems: Samsung Medison RS85 (CA1-7A probe) and FibroScan Compact M 530, respectively. For CAP, reliable measurements were defined as the median value of 10 measurements with IQR/M<0.3. For QUS, five consecutive measurements of TAI and TSI were acquired by a color-coded map overlaid on B-mode ultrasound. Reliable measurements were defined as, R2 over 0.6. The cut-off value of 260 dB/m by CAP was considered as indicative for at least significant steatosis (S2-S3)[1].

Results: Moderate correlations between steatosis assessment methods were observed: TAI vs. CAP, $r=0.75$, TSI vs. CAP, $r=0.31$, TSI vs. TAI, $r=0.47$. The best TAI rule-in and rule-out cut-off values to identify at least significant steatosis (S2-S3) were: >0.76 (AUROC=0.86, $p<0.0001$, PPV=94.1%, NPV=33.3%) for rule-in, and <0.55 (AUROC=0.86, $p<0.0001$, PPV=82.2%, NPV=80.1%) for rule-out, respectively. The best TSI rule-in and rule-out cut-off values for identifying significant steatosis were: >102.8 (AUROC=0.70, $p<0.0001$ PPV=92.9%, NPV=31.4%) for rule-in and <91.3 (AUROC=0.70, $p<0.0001$, PPV=75.6%, NPV=25.1%) for rule-out, respectively.

Conclusion: QUS measurements TAI/TSI are feasible methods for rule-in/ rule-out at of significant steatosis in ALD.

References

ENDOSCOPIC ULTRASOUND-GUIDED PANCREATIC PSEUDOCYST DRAINAGE: RETROSPECTIVE STUDY

Sebastiana Atzori¹, Rita Pinna¹, Gianpaolo Vidili¹

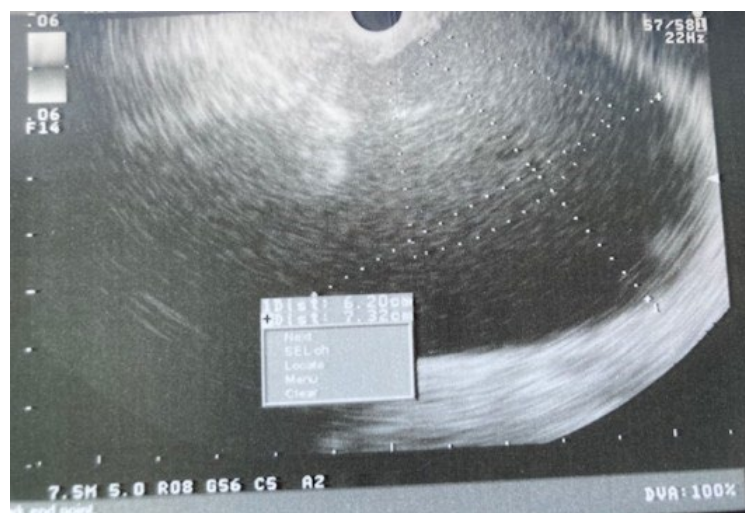
1. Azienda Ospedaliero Universitaria Sassari

Abstract body

Actuality and aim: Pancreatic pseudocysts (PPC) are fluid collections with a wall that persist for more than 4 weeks inside or around the pancreas as a result of pancreatic inflammation. We aimed to evaluate the safety and efficacy of EUS-guided drainage of PPC using a double-pigtail plastic stents following the insertion of a Lumen Apposing Metal Stent (LAMS). **Methods:** This is a retrospective review of patients with pancreatic pseudocysts, who underwent EUS-guided endoscopy from 2018 to 2022. Liver stiffness (LS) was assessed in all patients with a two-dimensional shear wave elastography (2D-SWE) technique using an Aixplorer ultrasound machine (SuperSonic Imagine, Aix-en-Provence, France) before the procedure and after two months of follow up. Statistical analyses were performed using SPSS version 29. **Results:** Nine patients (mean age, 61.5±15.12 years) were included. The aetiologies for PPC were acute biliary pancreatitis and chronic alcoholic pancreatitis. The mean pseudocyst size was 8.9±4.56 cm. No adverse events occurred. The technical success rate was 100%. Pseudocyst recurrence was identified in one patient (9%) at 12 weeks after drainage. Median LS values were higher before the pseudocyst drainage (8.2 kPa) to those obtained after two months follow up (7.7 kPa) but this was not statistically significant (p=0.299). **Conclusions:** EUS-guided drainage of PPC using a double-pigtail plastic stents following the insertion of a LAMS is safe and effective with high technical and clinical success rates.

References

Han D, Inamdar S, Lee CW, et al. Lumen apposing metal stents (LAMSs) for drainage of pancreatic and gallbladder collections: a meta-analysis. J Clin Gastroenterol 2018;52(9):835-44.



THE CAROTID INTIMA-MEDIA THICKNESS AND THE PULSE WAVE ANALYSIS: NON-INVASIVE METHODS OF EVALUATION OF THE VASCULAR DAMAGE IN OBESE CHILDREN

***Monica Simina Mihuta*¹, *Andreea Borlea*², *Corina Paul*³, *Cristina Mihaela Roi*¹, *Dana Stoian*²**

1. Department of Doctoral Studies, Victor Babes University of Medicine and Pharmacy, 300041 Timisoara, Romania, 2. 2nd Department of Internal Medicine, Victor Babes University of Medicine and Pharmacy, 300041 Timisoara, Romania, 3. Department of Pediatrics, Victor Babes University of Medicine and Pharmacy, 300041 Timisoara, Romania

Abstract body

Actuality and Aims

Vascular damage is fueled by processes like atherosclerosis and arterial stiffness. This begins in early childhood, but obesity is a significant accelerating factor. Our aim is to explore the usefulness of the carotid intima-media thickness and pulse wave analysis in evaluating the vascular damage of obese children.

Methods

The study included 75 children (48 obese and 27 controls). CIMT was measured with an Aixplorer MACH30 and the PWA was performed with a Mobil-O-Graph (pulse wave velocity, peripheral and central BP, HR, central pulse pressure). Complete clinical examination. Blood work: lipid panel, triglycerides, fasting glucose, GOT, GPT, 25-OH-Vitamin D, TSH, 8 am cortisol.

Results

BMI and WC are linked to increased CIMT, PWV, and BP. HDL-c, LDL-c, total cholesterol, and triglycerides are correlated to CIMT. The triglycerides/HDL-c ratio is a predictor of CIMT and LDL-c, a predictor of PWV, SBP, cSBP, and cDBP. The triglycerides, non-HDL-c, triglycerides/HDL-c ratio, and total cholesterol/HDL-c ratio are correlated to the PWV, SBP, MAP, and cSBP. Fasting glucose is not correlated to the CIMT or PWA parameters. GPT and GOT are both correlated with PWV, SBP, DBP, MAP, and cDBP. 25-OH-Vitamin D negatively correlates with CIMT, PWV, SBP, and MAP.

Conclusions

Obese children present higher values for the CIMT and arterial stiffness markers.

Abnormal values of the lipid panel, transaminase levels, and 25-OH-Vitamin D are linked to higher CIMT values, increased arterial stiffness, and high BP.

References

-Mihuta MS, et al (Appl. Sci. 2021). <https://doi.org/10.3390/app112210721>

-Mihuta MS, et al (J. Clin. Med. 2022). <https://doi.org/10.3390/jcm11175078>

SIGNIFICANT RISK FACTORS FOR THE INCREASE OF ARTERIAL STIFFNESS AND SUBCLINICAL ATHEROSCLEROSIS IN OBESE CHILDREN.

***Monica Simina Mihuta*¹, *Andreea Borlea*², *Corina Paul*³, *Cristina Mihaela Roi*¹,
*Dana Stoian*⁴**

1. Department of Doctoral Studies, Victor Babes University of Medicine and Pharmacy, 300041 Timisoara, Romania, 2. 2nd Department of Internal Medicine, Victor Babes University of Medicine and Pharmacy, 300041 Timisoara, Romania, 3. Department of Pediatrics, Victor Babes University of Medicine and Pharmacy, 300041 Timisoara, Romania, 4. 2nd Department of Internal Medicine, Victor Babes University of Medicine and Pharmacy; Center of Molecular Research in Nephrology and Vascular Disease, Faculty of Medicine, Victor Babes University of Medicine and Pharmacy; 300041 Timisoara, Romania

Abstract body

Actuality and Aims

Childhood obesity increases the risk of early increased arterial stiffness, high BP, and subclinical atherosclerosis. Individual risk factors can aggravate these processes. Our aim is to assess the value of the intima-media thickness and pulse wave analysis in the presence of such risk factors.

Methods

The study included 75 children (48 obese and 27 controls). An Aixplorer MACH30 was used for acquiring the CIMT and a Mobil-O-Graph was used for the PWA (pulse wave velocity, augmentation index, peripheral and central BP, HR, central pulse pressure). Clinical examination: BMI, waist circumference, Tanner stage. Risk factors: the mother's health during pregnancy, birth weight, postnatal nutrition, family history of cardiometabolic risk, sedentariness, cigarette smoke, sleep deprivation.

Results

BMI and WC are linked to increased CIMT, PWV, SBP, DBP, cSBP, cDBP. CIMT correlates with Tanner stages. High peripheral BP correlates with higher CIMT, regardless of the BMI. Significant risk factors for higher CIMT and arterial stiffness are: a cardio-metabolically risky pregnancy (higher CIMT, PWV, AIX, SBP), family history of cardiometabolic disorders (higher CIMT), exposure to smoke (higher CIMT, PWV, SBP, cSBP, cDBP), sleep deprivation (higher PWV, SBP, cSBP) and sedentariness (higher PWV, AIX, peripheral and central BP).

Conclusions

Childhood obesity aggravates the progression of atherosclerosis and arterial stiffness.

A risky pregnancy, family history of cardiometabolic risk, cigarette smoke, sleep deprivation, and sedentariness are linked to the progression of atherosclerosis, arterial stiffness, and high BP.

References

-Mihuta MS, et al (Appl. Sci. 2021). <https://doi.org/10.3390/app112210721>

-Mihuta MS, et al (J. Clin. Med. 2022). <https://doi.org/10.3390/jcm11175078>

CEUS IN THE EVALUATION OF THYROID NODULES – PRELIMINARY RESULTS

**Andreea Borlea¹, Felix Bende¹, Alexandru Popa¹, Ioan Sporea¹,
Alina Popescu¹, Dan Alin Brebu¹, Ion Icma¹, Dana Stoian¹**

1. University of Medicine and Pharmacy Victor Babes Timisoara

Abstract body

Contrast-enhanced ultrasound (CEUS) is a widely used method to visualize blood perfusions in organs, especially in liver lesions; its thyroid applications are currently not so well studied. We aimed to evaluate the performance of CEUS in diagnosing malignant thyroid nodules.

Ninety-eight patients were evaluated by classic ultrasound (US) and consecutively CEUS between September 2021-March 2022, of which 68 cases had a pathology report and were included in the analysis. The evaluation was made using a SuperSonic Mach30 (Hologic, USA). For the CEUS evaluation, 1.6 ml SonoVue (Bracco, Italia) was injected for each examination. The enhancement was described in relation to the healthy thyroid parenchyma, qualitatively, for 5 minutes post-administration.

Thyroid cancer was detected in 17 patients (25%): 1 follicular thyroid cancer, 12 papillary cancers and 4 papillary micromarcinomas. Regarding CEUS characteristics, a complete, peripheral enhancing ring and homogeneous enhancement was the observed parameters with the best predictive value for benignity (AUC=0.80, and 0.83; Se=91.67% and 74.36%; Sp=69.23% and 91.67%). Inhomogeneous enhancement (AUC=0.83; Se=74.36% Sp=91.67%) and a major enhancing defect, usually central (AUC=0.73, Se=50%, Sp=97.4%) were predictive for malignant thyroid nodules. We did not observe specific patterns for microcarcinomas, but inhomogeneous enhancement was observed in 3/4 cases.

In conclusion, benign and malignant thyroid nodules present distinctive patterns in qualitative CEUS thus its addition to the classic US models may improve the current algorithms.

References

Sidhu PS, Cantisani V, Dietrich CF, Gilja OH, Saftoiu A, Bartels E, et al. The EFSUMB guidelines and recommendations for the Clinical Practice of Contrast-Enhanced Ultrasound (CEUS) in non-hepatic applications: update 2017 (long version) *UltraschallMed.* 2018;39:e2-e44.

2D-SWE FOR THE DIAGNOSIS OF LIVER FIBROSIS USING VCTE AS REFERENCE METHOD IN A MIXED COHORT

Camelia Foncea¹, Renata Bende¹, Ioan Sporea¹, Radu Cotrau¹, Roxana Sirli¹, Alina Popescu¹

1. "Victor Babes" University of Medicine Timisoara

Abstract body

Background: Liver fibrosis is a progressive process leading to liver cirrhosis. Several non-invasive elastography techniques were developed for liver stiffness measurements (LS) as a marker of liver fibrosis. The aim of this study was to evaluate the performance and feasibility of 2D-Shear Wave Elastography (2D-SWE) for liver fibrosis (LF) assessment using Vibration Controlled Transient Elastography (VCTE) as the reference method.

Material and methods: 275 subjects were included, 59% (162) males, mean age 55.9 ± 12.2 , in which LS was evaluated in the same session by TE (FibroScan Compact M 530) and 2D-SWE (Samsung-Medison RS85). Reliable LS measurements were defined for VCTE the median value of 10 measurements with an $IQR/M \leq 30\%$, while for 2D-SWE the median value of 10 measurements, with a reliability measurement index (RMI) ≥ 0.5 and $IQR/M \leq 30\%$.

For classification of LF severity we used VCTE as reference method with cut-off value $\geq 7 \text{ kPa}$ for at least significant liver fibrosis (1).

Results: Reliable measurements by VCTE and 2D-SWE were obtained in all 275 cases. A positive correlation was found between 2D-SWE and VCTE, $r=0.31$ ($p<0.0001$). The best cut-off value for 2D-SWE in identifying at least significant fibrosis ($F \geq 2$) was $>7.9 \text{ kPa}$ [AUROC=0.90, 95% CI (0.85;0.93), $p<0.0001$, Se=77.6%, Sp=87.8%, PPV=78.4%, NPV=87.3%].

Conclusion: 2D-SWE is a feasible method for assessing liver fibrosis, that strongly correlates with VCTE results.

References

1. Tsochatzis EA, Gurusamy KS, Ntaoula S, Cholongitas E, Davidson BR, Burroughs AK. Elastography for the diagnosis of severity of fibrosis in chronic liver disease: a meta-analysis of diagnostic accuracy. J Hepatol. 2011 Apr;54(4):650-9. doi: 10.1016/j.jhep.2010.07.033. Epub 2010 Sep 24. PMID: 21146892

SONOGRAPHIC EVALUATION OF RENAL TRANSPLANT COMPLICATIONS: A PICTORIAL REVIEW

Nur Zakiah Sidek¹, Angela Anthony¹, Siti Atiqah Aziz¹, Hui Lin Wong¹

1. Singapore General Hospital

Abstract body

Introduction:

Renal transplant is the treatment of choice for end-stage renal disease patients[1]. However, urologic and vascular complications may occur[2]. This pictorial review aims to highlight the role of ultrasound in diagnosing potential complications in post-renal transplantation.

Objectives:

To illustrate and discuss:

1. Scanning techniques, interpretation and potential pitfalls
2. Various types of renal transplant complications and its ultrasound features

Methodology:

Electronic medical records of patients referred to Singapore General Hospital with post-renal transplant ultrasound requests from January 2018 to December 2022 were reviewed. Ultrasound and cross-sectional imaging, surgical notes and laboratory tests were reviewed and collated.

Results:

With correct probe manouvre, use of low-velocity color detection flow and contrast-enhanced ultrasound; optimum assessment of post renal transplant can be achieved. Potential imaging pitfalls such as increased intrarenal resistive index due to pressure exerted by operator can be avoided. Post-renal transplant complications include vascular complications such as artery stenosis, infarction, arteriovenous fistula, pseudoaneurysm and renal vein thrombosis as well as urologic complications such as urinomas, peritransplant fluid collections, hematoma, lymphoceles and abscesses.

Conclusion:

Ultrasound plays a key role in routine surveillance of post-renal transplant patients as well as in management of acute or chronic transplant dysfunction. Awareness of the imaging spectrum of complications is vital to improve early diagnosis early intervention and prolong graft survival.

References

1. Akbar, S. et al (2005). Complications of renal transplantation. Radiographics, 25(5), 1335-1356.
2. Shoskes, D. A. et al (1995). Urological complications in 1,000 consecutive renal transplant recipients. The Journal of Urology, 153(1), 18-21.

CEREBRAL HEMODYNAMICS IN THE PATIENTS WITH VARIOUS FORMS OF MIGRAINE

***Olga Pushkarenko*¹, *Valeriy Kalashnikov*²**

1. Uzhhorod National University, 2. Kharkiv Medical Academy of Postgraduate Education

Abstract body

The usage of ultrasound methods of vascular diagnostics gains great importance for the study of migraine. The aim of the study was to Doppler sonography study of the structural and functional state of head magistral cerebral arteries in the patients with various forms of migraine.

We conducted the Doppler sonography examination (Ultima PA ultrasound device, RADMIR, Ukraine) of 106 young patients (18-45 years old) with migraine without aura (MwA - 54 patients), migraine with aura (MA - 52 patients)

Results. The presence of extravasal compressions of vertebral arteries (VA) is typical for the patients with migraine, as well as for some cases of the hypoplasia of the VA in patients with MA. In the patients with MA was a decrease in the velocity values in the extracranial VA segments. The velocity values in the external carotid arteries (ECA) were slightly reduced in both groups. The most significant were the changes in the hemodynamics in the middle cerebral arteries (MCA), which were manifested by the pattern of the excessive perfusion in the patients with MwA and the pattern of the hampered perfusion in the MCA in the patients with MA.

Conclusions. In the patients with MA, a decrease in the velocity values in the extracranial segments of the VA was observed, in some cases combined with the hypoplasia of the vertebral artery, the hampered perfusion in middle cerebral arteries.

The excessive perfusion in MCA is the most critical hemodynamic pattern in the patients with MwA.

References

1. <https://pubmed.ncbi.nlm.nih.gov/28857642/>
2. <https://pubmed.ncbi.nlm.nih.gov/35982093/>
3. <https://pubmed.ncbi.nlm.nih.gov/12620598/>

PRE-SURGICAL DIAGNOSTIC SOLID LESIONS OF THE SKIN

Iryna Mota¹, Yaryna Zaychenko¹

1. ukrainian

Abstract body

Analyze the volume of preoperative high-resolution ultrasound, to compare indicators and to justify the expediency of using a double diagnostic test "Dermatoscopy + ultrasound" to determine the indications for surgery.

Both ultrasound and dermatoscopic indices confirm the diagnosis of lesions, establish penetration depth, the documented dimensions make possible to resolve the issue of optimal surgical intervention.

References

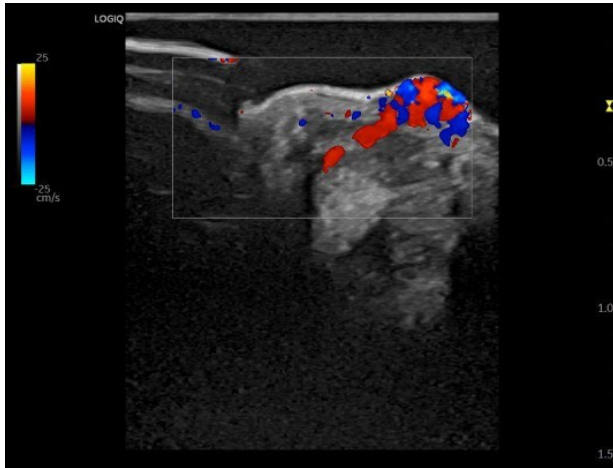
Wortsman X, Carreño L, Morales C. In: Dermatologic ultrasound with clinical and histologic correlations. Wortsman X, editor. New York NY USA: Springer; 2013. Skin cancer: the primary tumors; pp.249-282.

Dubois J, Alison M. Vascular anomalies: what a radiologist needs to know. *Pediatr Radiol* 2010; 40:895-905.

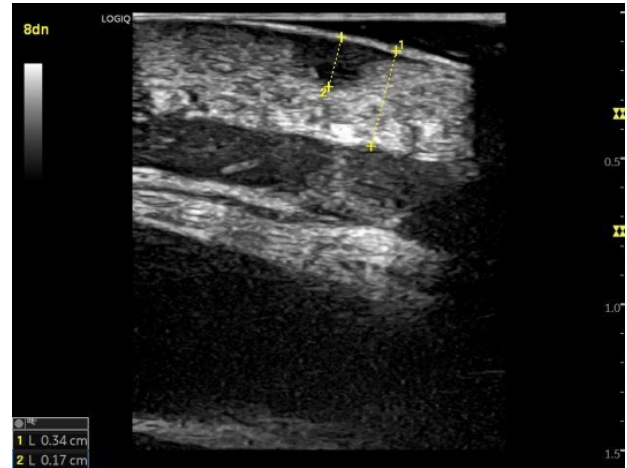
Wortsman X, Alfageme F, Roustan G, et al. Guidelines for performing dermatologic ultrasound examinations by the DERMUS group. *J Ultrasound Med* 2016; 35:577-580.

Forsea AM, Marmol V, Vries E, et al. Melanoma incidence and mortality in Europe: new estimates, persistent disparities. *Br J Dermatol*. 2012;167:1124-30.

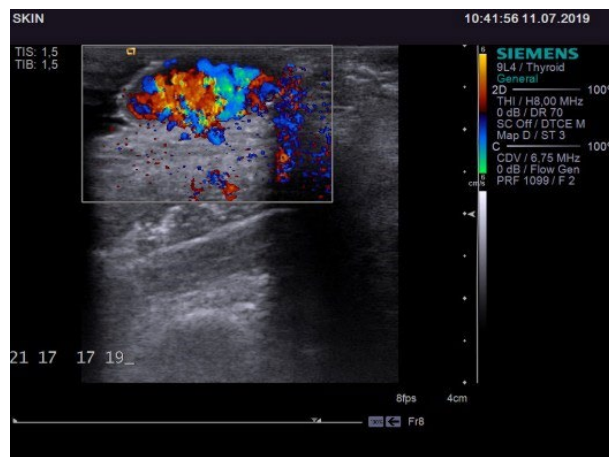PRE-SURGICAL DIAGNOSTIC SOLID LESIONS OF THE SKIN



Hemangioma of the upper lip.



Nevus on the back.



Melanoma on the shoulder.

A BLENDED LEARNING APPROACH FOR TEACHING CHEST RADIOLOGY TO MEDICAL STUDENTS: A PROOF-OF-CONCEPT STUDY

Johannes Matthias Weimer¹, Lukas Müller², Andreas Weimer³, Yang Yang²,
Phyllis Gerstenmeier¹, Michael Ludwig⁴, Jonas Lauff¹, Alina Weil¹, Fabian Stöhr²

1. Rudolf-Frey Lernklinik, Department of Medicine, University of Mainz, Mainz, Germany, 2. Department of Diagnostic and Interventional Radiology, University of Mainz, Mainz, Germany, 3. Center for Orthopedics, Emergency Surgery, and Paraplegics, Department of Medicine, University of Heidelberg, Heidelberg, Germany, 4. German Army Hospital Berlin

Abstract body

Aim: The best way of transferring knowledge to medical students is still unclear. However, medical students are highly interested in innovative approaches including online learning. Thus, we designed a flipped classroom concept in chest radiology including both onsite and online modules (blended learning approach). We aimed 1. to investigate students' attitudes towards this specific course design and 2. to test whether it improves their knowledge about chest radiology (including ultrasound imaging).

Methods: We conducted this prospective study at our university medical center; 145 fourth-year medical students completed this course. Before a face-to-face onsite class was given, students had to acquire knowledge autonomously by completing a dedicated online course. Before and after the course, students had to complete 1) questionnaires using a 7-point Likert scale to investigate their attitudes and 2) an objective test to assess their knowledge.

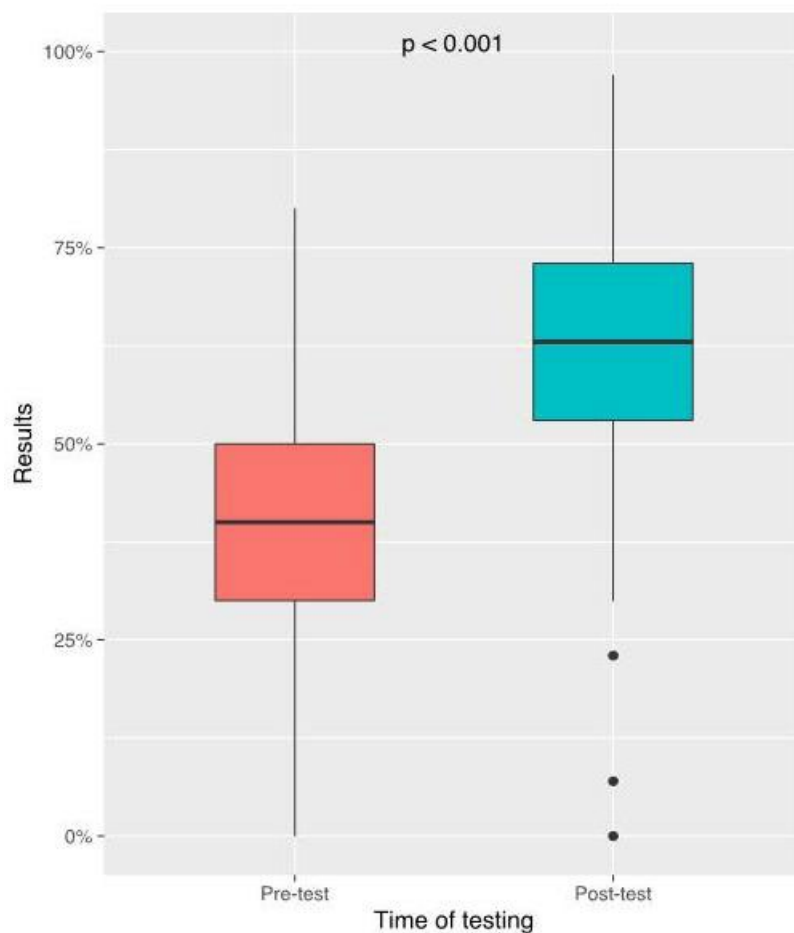
Results: The course led to an improvement regarding all times compared to baseline, exemplary: knowledge in the objective test (pre-course: 40% vs. post-course: 63% correct answers), interest in chest radiology (pre-course 5.2 vs. 5.4 post-course) and fulfillment of requirements on teaching content (4.5 pre-course vs. 6.2 post-course). Furthermore, the great majority of our participants wished for more online learning offers in the future (88%).

Conclusion: This study demonstrates the positive impact of a dedicated blended learning course on understanding and knowledge about chest radiology (including ultrasound imaging). Furthermore, it reveals the positive attitude of medical students towards such innovative learning concepts.

References

<https://doi.org/10.1186/s13244-019-0804-9> <https://doi.org/10.1371/journal.pone.0257394>.

A BLENDED LEARNING APPROACH FOR TEACHING CHEST RADIOLOGY TO MEDICAL STUDENTS: A PROOF-OF-CONCEPT STUDY



Pre-post-course results of the participant.

AUTOMATED BREAST VOLUME SCANNING AND VIRTUAL TOUCH IMAGING QUANTIFICATION IN DIFFERENT TYPES OF BREAST CANCER

Lucan Eugenia Laura¹, Vancu Mihaela¹

1. The Center of Excellence of Ultrasonography DOCTOR VANCU

Abstract body

Aim

This study correlates advanced ultrasound techniques, ABVS and VTIQ, with different types and subtypes of breast cancer.

Methods

In our group practice, ABVS and Share Wave Elastography (SWE) are performed by two physicians using ACUSON S2000 HELX, with over ten years experience.

From a sample of 3459 patients (2016-2022), 25 to 80 years old, a selection of 116 cases with BI-RADS: 5, confirmed by needle biopsy with biomarkers profiles, was analysed.

We performed VTIQ and we measured the stiffness in healthy tissue compared with breast lesions. We evaluated the differences of the speeds of velocity in different types of breast cancer.

Results

In 92% of cases, hormone dependent breast cancer is associated with coronal view retraction on ABVS, with high specificity (90%) to triple negative breast cancer (TNBC), including ki-67 expression. The microcalcifications and irregular shapes in ABVS were more specific for HER positive breast cancer.

Also, we found high stiffness with mean velocity 6.20m/s in hormone dependent breast cancer, compared with a mean velocity of 3.40 m/s for TNBC. Hard stiffness with mean velocity of 5.20m/s was more specific for HER positive cancer.

Conclusions

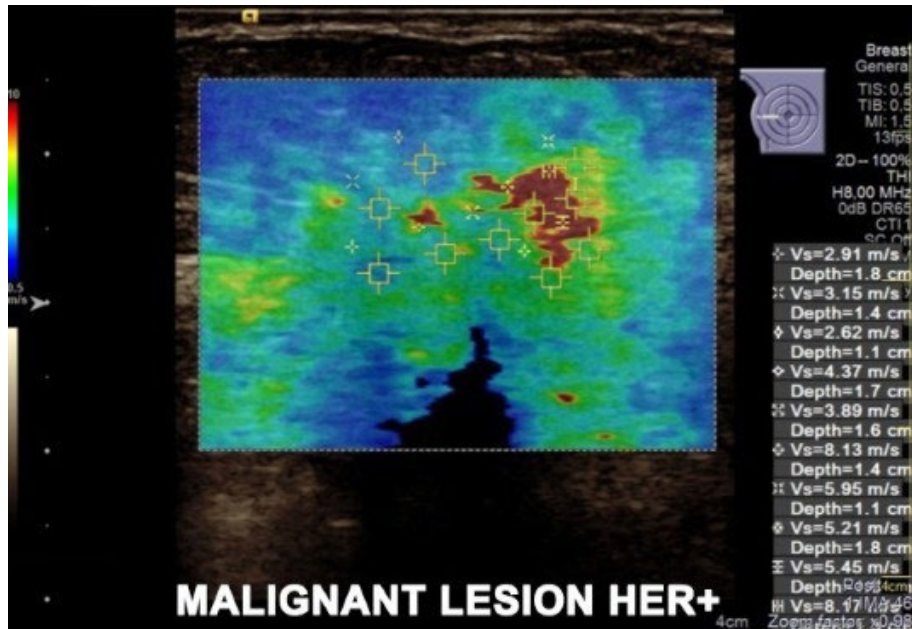
ABVS and VTIQ are complementary techniques which bring long-term benefits for surgical and oncological approach, being useful in personalized treatment of breast cancer.

These methods guarantee high patients safety, have a higher reproducibility, without irradiation and no injection contrast substances, increasing the confidence to monitor the lesions during oncological treatment.

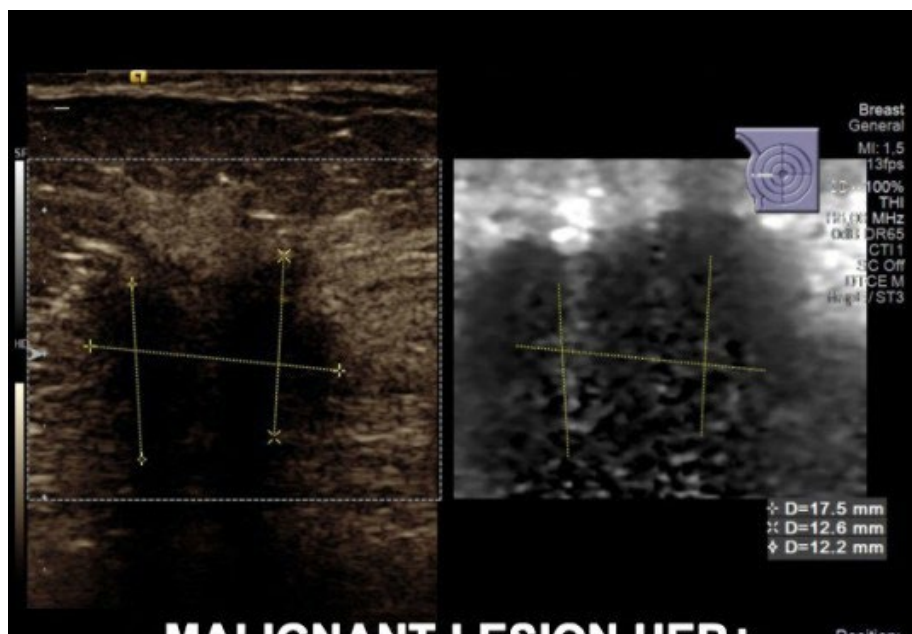
References

Richard Gary Barr, Future of Breast Elastography, Ultrasonography 38(2) April 2019

AUTOMATED BREAST VOLUME SCANNING AND VIRTUAL TOUCH IMAGING QUANTIFICATION IN DIFFERENT TYPES OF BREAST CANCER

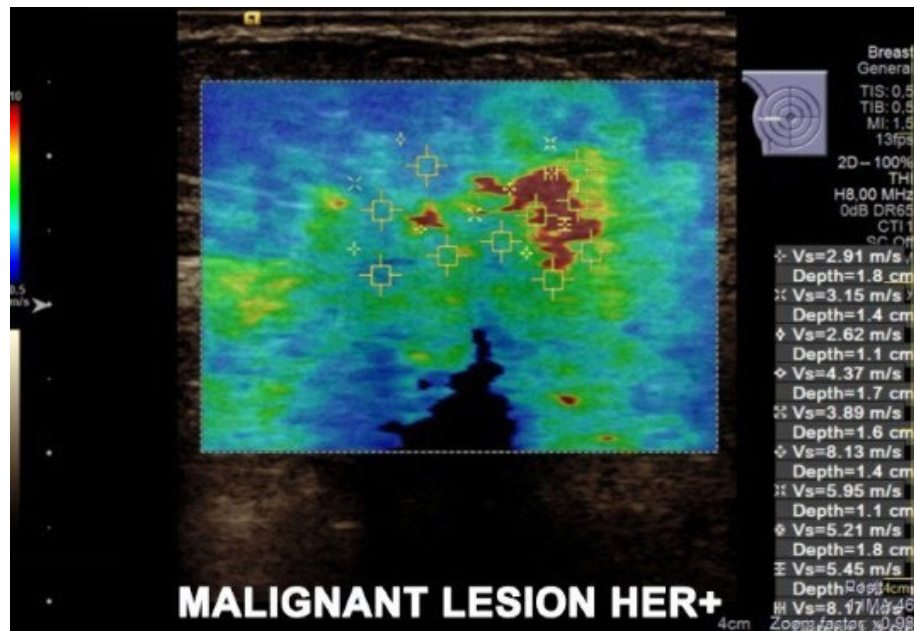


Malignant lesion HER2+ (VTIQ)



Malignant lesion HER2+ (VTI)

AUTOMATED BREAST VOLUME SCANNING AND VIRTUAL TOUCH IMAGING QUANTIFICATION IN DIFFERENT TYPES OF BREAST CANCER



Malignant lesion HER2+ (ABVS)

PROSTATE TUBERCULOSIS MIMICKING PROSTATE CANCER: MULTIDISCIPLINARY DIAGNOSTIC IMAGING AND REVIEW OF THE LITERATURE

YU Li¹

1. Affiliated Hospital of North Sichuan Medical College

Abstract body

ABSTRACT: In male reproductive system tuberculosis, prostate tuberculosis (PTB) has no specific symptoms, insidious presentation, and is difficult to find in the early stage. When PTB develops to the late stage, it will lead to disease progression and irreversible organ and tissue damage. At present, the imaging manifestations of prostate tuberculosis vary and are not well known to imaging physicians and urologists. This case is a PTB patient, whose main manifestation was elevated serum prostate-specific antigen (PSA) and the diagnosis was confirmed by ultrasound-guided prostate biopsy. We analyzed the imaging performance of various imaging techniques, and summarized and explored the imaging characteristics reported in the previous literature, The aim was to improve the early detection rate and provide evidence-based practice for early regular antituberculosis treatment in PTB disease.

References

- [1] Muneer A, Macrae B, Krishnamoorthy S, et al. Urogenital tuberculosis - epidemiology, pathogenesis and clinical features.[J]. Nature reviews. Urology, 2019,16(10):573-598.
- [2] Muttarak M, ChiangMai W N, Lojanapiwat B. Tuberculosis of the genitourinary tract: imaging features with pathological correlation.[J]. Singapore medical journal, 2005,46(10):568-574, 575.
- [3] Tajima H, Tajima N, Hiraoka Y, et al. Tuberculosis of the prostate: MR imaging.[Z]. Radiation medicine, 1995, 13(4), 171-173.
- [4] Lee S, Wolfe K, Acher P, et al. Multiparametric MRI appearances of primary granulomatous prostatitis.[Z]. The British journal of radiology, 2019, 92(1098), 20180075

COMPARISON OF CORACOHUMERAL DISTANCE MEASUREMENT BY SHOULDER ROTATION USING ULTRASONOGRAPHY AND MRI

JONG UK SON¹

1. Seoul national university bundang hospital

Abstract body

PURPOSE

Cracohumeral distance (CHD) is one of the main causes of shoulder impingement syndrome. The value of CHD depends on the shoulder rotation, and it is known as the narrowest measure of internal rotation. The measured CHD using the Ultrasound is compared to the CHD obtained from MRI.

MATERIAL AND METHOD

In this study, normal volunteer (case = 28) without previous history of shoulder and history of operation were considered. Ultrasonography was conducted using EPIQ 7G (Philips Medical System) and linear probe 12-5. The images were acquired by rotating the shoulder joint with Neutral Rotation (NR), Internal Rotation (IR) and external rotation. MRI was performed using 3.0 Tesla (Ingenia, Philips Medical System) and 8 channel shoulder coils. T1 fat suppression axial images were obtained for NR and IR, respectively. The measured CHD was subjected to a corresponding paired sample t-test SPSS ver.24 was used for statistical analysis.

RESULTS

In shoulder joint rotation, the measured CHD using ultrasound was NR 13.89 ± 2.5 mm, IR 11.04 ± 2.5 mm. The measured CHD by MRI was 13.32 ± 2.7 mm for NR and 10.08 ± 2.5 mm for IR. There was no statistically significant difference in CHD changes between the two studies.

CONCLUSIONS

There was no significant difference between ultrasonography and MRI measurements by the measured CHD values.

References

Measurement of Coracohumeral Distance in 3 Shoulder Positions Using Dynamic Ultrasonography: Correlation With Subscapularis Tear (Arthroscopy: The Journal of Arthroscopic and Related Surgery, Vol 32, No 8 (August), 2016: pp 1502-1508)

ROLE OF 3D USG IN EVALUATION OF MORPHOLOGY AND FUNCTION OF GALLBLADDER

Manavjit Sandhu¹, Raghuraman Soundararajan², Usha Dutta², Anmol Bhatia², Pankaj Gupta², Anish Bhattacharya², Uma Nahar², Lileswar Kaman²

1. PGIMER, Chandigarh, 2. PGIMER, Chandigarh, India

Abstract body

Actuality and aim:

To compare the role of 2D and 3D ultrasonography (USG) with cholescintigraphy in the assessment of gallbladder function in patients with gall stone disease and non-ulcer dyspepsia.

Methods:

A total of 97 patients were chosen, comprising of 51 patients with symptomatic gallstone disease and 46 patients having dyspepsia without gallbladder disease (controls). All were subjected to 2D-USG and 3D-USG for the assessment of gallbladder morphology, volume, and gallbladder ejection fraction (GBEF). All patients with gallstone disease were subjected to cholescintigraphy for the estimation of gallbladder function.

Results:

Among cases, mucosal distinction of gallbladder wall was seen in 61.5% and 88.5% on 2D-USG and 3D-USG respectively. 53.8% patients had multiple gallstones. Gallbladder stasis (defined as best GBEF < 40%) was present in 69.2% and 46.1% cases on 2D and 3D-USG respectively, and in 15.4% on cholescintigraphy. Gallbladder volumes measured by 2D-USG at different time intervals were consistently higher than that measured by 3D-USG in both cases and controls ($p < 0.01$). Although there was positive correlation between the GBEF measured by 2D-USG and 3D-USG, they were significantly lower than that measured by cholescintigraphy ($p < 0.03$). The peak gallbladder emptying was seen at 60 minutes on 2D-USG and 3D-USG, however, at 30 minutes on cholescintigraphy.

Conclusion:

3D-USG precisely measures gallbladder volume, leading to better categorization of gallbladder stasis, in comparison with 2D-USG.

Acknowledgments:

None

References

Xu H-X, Yin X-Y, Lu M-D, et al. Comparison of three- and two-dimensional sonography in diagnosis of gallbladder diseases: preliminary experience. J Ultrasound Med. 2003;22:181-91

POLY(LACTIC ACID) FILM POCKET FOR ULTRASOUND-CONTROLLED PROPHYLAXIS AGAINST SPINAL INFECTIONS: IN VITRO EVALUATIONS

Flemming Forsberg¹, Selin Isguven¹, Lauren J. Delaney¹, Hebah Falatah¹,
Noreen J. Hickok²

1. Department of Radiology, Thomas Jefferson University,
2. Department of Orthopaedic Surgery, Thomas Jefferson University

Abstract body

Actuality and Aim

Infection after spinal implant surgery occurs in up to 21% of the cases; a devastating complication given the need for continuous spinal stability. There is a need for more effective antibiotic prophylaxis. A poly(lactic acid) (PLA) film pocket has been designed for delayed local delivery of prophylactic antibiotics and was evaluated in vitro.

Methods

PLA pockets with one rupturable film (0.5-1.2 g PLA) and one foundational film (3-5 g PLA) encompassing a ~3mL internal reservoir were assembled. To increase the likelihood of rupture, 10-50 mg of Vancomycin (VAN) powder (Athenex) was incorporated into the PLA films. Pockets were loaded with methylene blue (MeB; Sigma Aldrich) solution and cavitation nuclei, 0.6-1.5 mL of Sonazoid microbubbles (GE Healthcare) or 2-3 mL of nanodroplets derived from Definity microbubbles (Lantheus). Pockets were submerged in a water bath and insonated with either clinical ultrasound using an S50 scanner (SonoScape) with a curvilinear C1-6 probe or high intensity focused ultrasound (HIFU) using an SU-101 probe (Sonic Concepts). Pocket rupture was compared for PLA films with embedded VAN vs no VAN.

Results

53 pockets were tested for ultrasound-triggered rupture. Eleven out of the 13 pockets (85%) containing a film with VAN ruptured successfully as indicated by marked MeB release. Of the 40 pockets made with a film without VAN, 9 (23%) achieved rupture, which was significantly lower than for the VAN pockets ($p=0.0001$).

Conclusions

Results demonstrate the ability to use a pocket made of VAN-embedded PLA film for ultrasound-triggered drug delivery.

Acknowledgements:

NIH-R01AR069119

References

N/A

POSSIBILITIES OF GASTROINTESTINAL ULTRASOUND IN DIAGNOSIS OF PARASITIC INVASIONS OF GASTROINTESTINAL TRACT

Elene Khmaladze¹

1. Tbilisi State University Clinic Vivamed

Abstract body

Introduction:

Recently GIUS has been gaining power in the world medical practice in the diagnosis of various pathological processes. Among other common causes of organic and functional lesions of the digestive tract are parasitic invasions, which remain unrecognized for years. Patients undergo courses of treatment with gastroenterologists, but relapses occur, the true cause of which remains unknown for years

Methods:

Method includes ultrasound and laboratory diagnostic :

1. ultrasound examination using oral water contrast after preparation:

- protein diet
- drugs against flatulence
- fasting before the study.

2. Laboratory diagnostics includes:

- a general blood test (hypohemoglobinemia and eosinophilia)
- complex PCR analysis of feces

Results:

During ultrasound examination of the gastrointestinal tract it is possible to identify:

1. Direct signs of parasites presence

- linear and sinuous inclusions indicating the presence of small and medium-sized parasites
- rounded, larger inclusions - the heads and bodies of large parasites tapeworms

2. Indirect signs

- smallbowel pneumatosis
- valvular insufficiency
- swelling mucose
- mixed dyskinesia

And in almost all cases, parasites were confirmed by feces PCR-test.

Conclusion:

GIUS is a very valuable method in diagnosis of gastrointestinal parasitic invasions.
The technique guides the patient to the adequate treatment.

This technique has a number advantages over other diagnostic methods

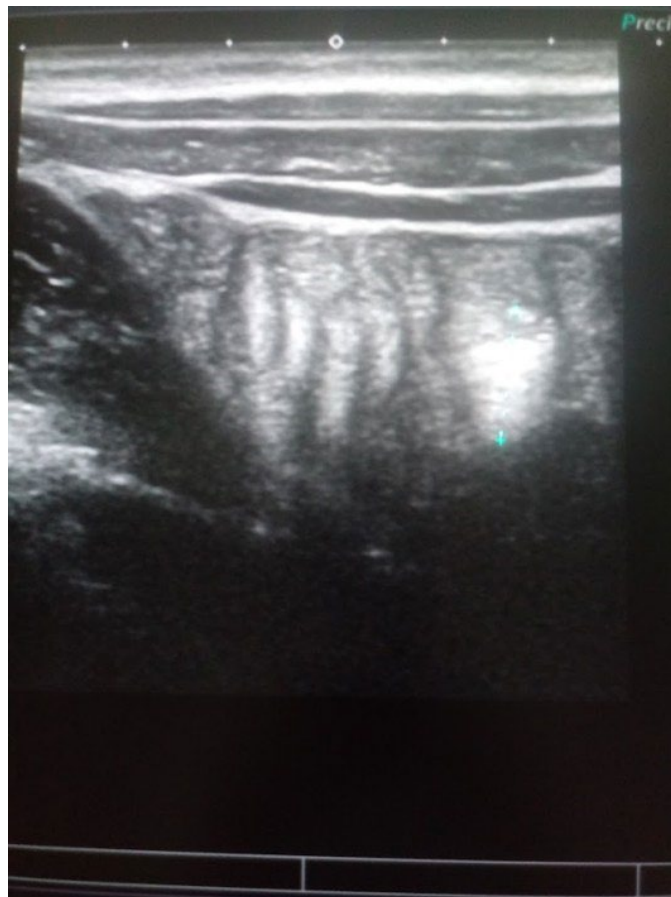- non-invasiveness
- no radiation exposure
- low buget

GIUS deserves close attention from US-specialists

References

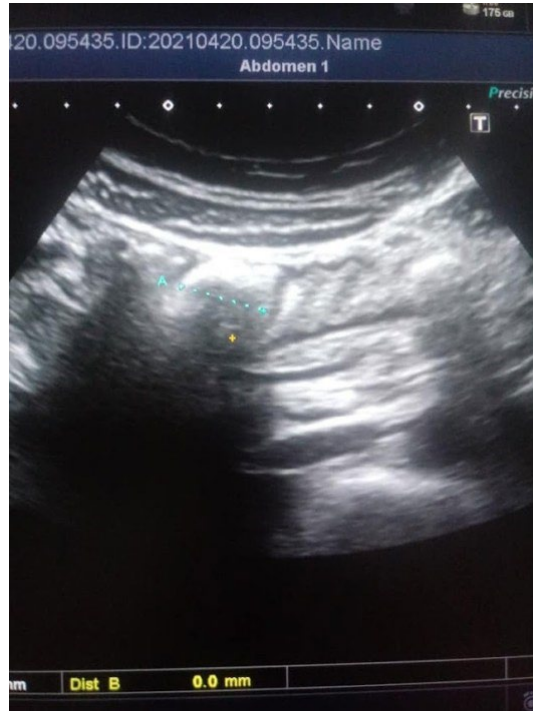Indirect effects of parasites in invasions

Alison M. Dunn, Mark E. Torchin, Melanie J. Hatcher, Peter M. Kotanen, Dana M. Blumenthal, James E. Byers, Courtney A.C. Coon, Victor M. Frankel, Robert D. Holt, Ruth A. Hufbauer

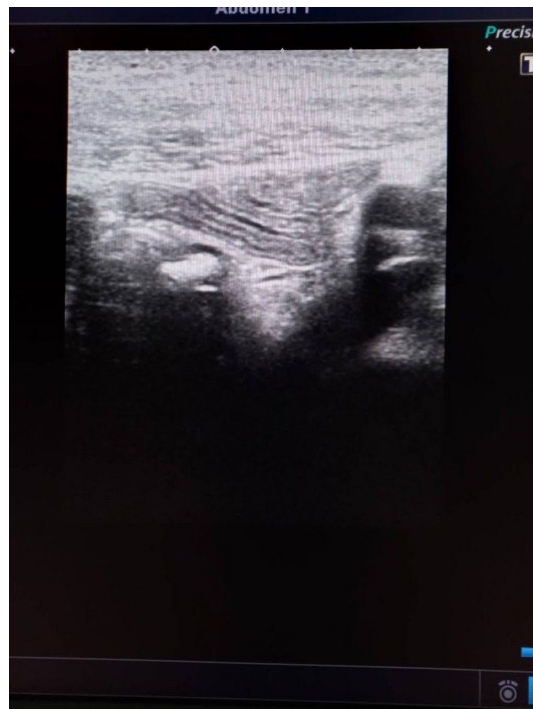

Tapeworm *Taeniarhynchus saginatus*.

POSSIBILITIES OF GASTROINTESTINAL ULTRASOUND IN DIAGNOSIS OF PARASITIC INVASIONS OF GASTROINTESTINAL TRACT



Tapeworm *Taenia solium*.



Toxocara cati.

TESTICULAR MICROLITHIASIS – AN OVERVIEW

Malene Roland Pedersen¹

1. Lillebaelt Hospital, Vejle Hospital, Department of Radiology, Beriderbakken 4, DK-7100 Vejle, Denmark

Abstract body

Ultrasound is the preferred and widely accepted first choice image modality for evaluating the scrotum. Testicular microlithiasis is an incidental finding during scrotal ultrasound and is a common finding. It is characterized by the presence of calcifications without acoustic shadowing within the testicular tissue. Testicular microlithiasis is of unknown origin with a typically size of 1 mm. It is a painless condition.

There seems to be uncertainty in the literature on testicular microlithiasis as a benign or a potential pre-malignant condition. The prevalence varies in various populations and have been reported from 2% up to 16% in the healthy population. In populations with genetic disorders the testicular microlithiasis prevalence have been reported up to 36%. A Danish study investigated patients with testicular tumors and reports testicular microlithiasis was seen in 19-40 % of the patients.

Current recommendation is yearly ultrasound scans in males with testicular microlithiasis and additional risk factors.

This presentation will provide history overview, prevalence, ultrasound follow-up, definition of testicular microlithiasis, risk factors and testicular cancer.

References

Pedersen et al. Testicular microlithiasis and testicular cancer: review of the literature. Int Urol Nephrol 2016, 48:1079-1086. DOI 10.1007/s11255-016-1267-2

USE OF CONTRAST-ENHANCED ULTRASOUND IMAGING TO EVALUATE THE EFFECT OF AN EXERCISE PROGRAM ON ROTATOR CUFF DISORDERS

***Priscilla Machado*¹, Jayati Anand¹, Suzanne Long¹, Philip McClure², Kshamata Shah², Levon Nazarian¹, Flemming Forsberg¹**

1. Thomas Jefferson University, 2. Arcadia University

Abstract body

Actuality and Aims: To examine the effect of a 6-week exercise program on muscle, tendon and bursa vascularity in patients with rotator cuff disorder compared to healthy volunteers.

Methods: This IRB-approved study enrolled 5 volunteers and 5 patients. Subjects underwent 2 ultrasound examinations 6 weeks apart, patients underwent a 6-week exercise program. Contrast-enhanced ultrasound (CEUS) examination of supraspinatus tendon, supraspinatus muscle, deltoid muscle and bursa area was performed before and after a fatigue protocol using an Aplio i800 scanner (Canon Medical Systems USA) with an 18L5 probe. The contrast agent Lumason (Bracco) was administered IV (dose: 2.4ml). CEUS clips were acquired with off-line data analysis to determine baseline intensity (BI), peak intensity (PI), and perfusion (Per; as the slope of the wash in) pre and post fatigue.

Results: 5 volunteers completed the first exam, while 4 also completed the second exam. All 5 patients completed both exams. The volunteer data showed statistical significance differences in PI for muscle and tendon post fatigue exam1 vs exam2 ($p \leq 0.04$) and Per for bursa pre fatigue exam1 vs exam2 ($p = 0.008$). In the patient group, there was statistically significant differences for BI for muscle and tendon pre and post fatigue ($p < 0.01$). Comparison between volunteers and patients showed significant statistical differences for BI and PI for muscle and tendon ($p \leq 0.02$).

Conclusion: CEUS evaluation of the vascularity in the muscles, tendons and bursa in individuals with rotator cuff disorder showed increased vascularity after a 6 week exercise program; albeit in a small sample size.

Acknowledgements: N/A.

References

N/A.

USING LYMPHOSONOGRAPHY TO EVALUATE THE BREAST LYMPHATIC DRAINAGE TO THE INTERNAL THORACIC (INTERNAL MAMMARY) SYSTEM

Priscilla Machado¹, Ji-Bin Liu¹, Laurence Needleman¹, Christine Lee²,
Flemming Forsberg¹

1. Thomas Jefferson University, 2. Mayo Clinic

Abstract body

Actuality and Aims: Around 15-25% of the breast lymphatic drainage goes through the internal thoracic (internal mammary) lymphatic system, draining the inner quadrants of the breast. Therefore, it was expected that the internal thoracic (internal mammary) system would also drain breast cancers located in the inner quadrants. The objective of the study was to use lymphosonography to identify sentinel lymph nodes (SLNs) in the axillary lymphatic system and the internal thoracic lymphatic system in patients with breast cancer.

Methods: 79 subjects completed this IRB-approved study. Subjects underwent subcutaneous Sonazoid (total: 1.0ml; GE Healthcare) injections around the tumor. Lymphosonography was employed to identify SLNs using a S3000 HELX scanner (Siemens Healthineers).

Results: In 65 of 79 subjects (82.3 %) the tumor was located in the outer quadrants of the breast and in 14 of 79 subjects (17.7%) the tumor was located in the inner quadrants of the breast. Lymphosonography identified a total of 217 SLNs in the 79 subject; an average of 2.7 SLNs/subject. All the 217 identified SLNs in the 79 subjects were located in the axillary lymphatic system; none of the identified SLNs in this study were located in the internal thoracic (internal mammary) lymphatic system even though 2-4 subjects (i.e., 4-11 SLNs) were expected.

Conclusion: Results implied that SLNs associated with breast cancers are predominantly located in the axillary lymphatic system. This would suggest that the LNs in the internal thoracic (internal mammary) lymphatic system are part of the secondary and tertiary lymphatic systems.

Acknowledgements: NIH-R01CA172336.

References

N/A.

THE USE OF ULTRASOUND IN BATTLEFIELD ENVIRONMENT DURING THE RUSSIAN INVASION OF UKRAINE

Vitalii Lukianchuk¹, Oleh Dynnyk²

1. Ministry of Defense of Ukraine, military hospital, 2. Medical Director of the Institute of Elastography, President of the Ukrainian Association of Ultrasound Diagnostics.

Abstract body

On December 24, 2022, the Russian Federation invaded Ukraine, starting a war. Like any armed conflict, these events have a large number of victims.

In order to understand the utility of tactical ultrasound it is important to understand the battlefield environment, the military medical system and combat medicine. The purpose of combat medicine is to return the greatest number of military members to combat and to preserve life, limb and eyesight in those who must be evacuated from the battlefield.

Accurate and reliable diagnostic capability is essential in deployed healthcare to aid decision-making and mitigate risk. This is important for both the patient and the deployed healthcare system, especially when considering the prioritization of scarce aeromedical evacuation assets and frontline resources.

We describe the use of emergency ultrasound in austere environments to guide tactical decision-making. We describe the use of tactical ultrasound, which is the use of emergency ultrasound to guide decision-making in the diagnosis, treatment and disposition of patients when resources are scarce and testing is severely limited. It is the use of emergency ultrasound in an environment that is inherently different than routine daily practice in emergency departments in the developed world. Tactical ultrasound provides critical information that justifies the utilization of limited resources and the significant risk involved in evacuating a patient to higher levels of care. Battlefield medicine is the primary venue where tactical ultrasound is useful, however, these same principles apply to civilian mass casualty incidents.

References

THE LUNG ULTRASOUND (LUS) OF PULMONARY OEDEMA IN DIFFERENT TYPES OF HEART FAILURE (HF)

Mikheil Tsverava¹, Dimitri Tsverava²

1. Chapidze Heart Center, 2. Ivane Javakhishvili Tbilisi State University

Abstract body

Pulmonary congestion (PC) in HF is important finding. LUS becomes attention in the detection of PC. There are 3 phenotypes of HF HF with reduced Ejection Fraction (EF) - HFrEF (EF<41%), HF with mid range - HFmrEF (EF=41-40%), HF with preserved EF - HFpEF (EF>49%).

The aim of study was to establish the role of LUS in patients with different tips of HF

Material Methods. We studied 430 patients with II-IV NYHA class HF (230 Patients with HFrEF, 108 patient - HFmrEF, 92 patient -HFpEF) and 155 patients without HF (control). LUS was done from 10 points of thoracic wall which corresponded to the projection of lung lobes.

Results: In patients with HF we significantly often found the "B lines". The count of B line registration points correlated with HF NYHA class ($r=0.57$), left ventricular systolic ($r=0.43$), diastolic ($r=0.34$) diameters and EF ($r=-0.44$). In 89.6% of HF patients B lines was registered from > 3 points, in HFrEF in 93.5%, in HFpEF in 82.6%, in HFmrEF in 88%. If we take >3 points as reference value, the sensitivity of sign was 83.5%, specificity – 97.6%. In HF group B lines was protracted and multiple, while in control - single and short lasting. After diuretic therapy B lines disappear or the registration area reduced

Conclusion: LUS is accurate method for evaluation and monitoring of PC in HFrEF, HFmrEF and HFpEF.

References

Comet tail artefact in diagnosis of pulmonary congestion in patients with diastolic HF. Georgian.Med.News 2010 Oct;28-35

ENERGY CONSUMPTION OF ULTRASOUND DEVICES AND THE POTENTIAL TO SAVE ENERGY IN GERMAN HOSPITALS

Mark M. haenle¹, Paula Linhart¹, Wolfgang Kratzer¹

1. Ulm University Hospital, Department of Internal Medicine I, Ulm

Abstract body

Actuality and Aim: Against the background of climate change, saving energy is gaining in importance. The energy consumption of ultrasound units is much lower than that of CT or MRI scanners. This might be of relevance on a global scale, due to the large number of ultrasound units in daily use worldwide. This is the first study, which aims to assess energy consumption of 9 different ultrasound devices in a hospital setting and to compare it with manufacturers' data. Additionally, user behaviour towards "switching off" ultrasound machines after use and saving energy in general was assessed in a representative sample of German hospitals.

Methods: The power consumption of 9 different ultrasound devices was measured in off-mode, stand-by, ready-to-scan and scan-modes with different settings and probes and compared with manufacturers' information. A random sample of 10% of all German hospitals was surveyed with an online questionnaire on user behaviour towards saving energy in ultrasonography.

Results: Preliminary results show significant differences in energy consumption in stand-by and ready-to-scan modes between different manufacturers. In stand-by mode energy consumption is still relatively high. The results of the online survey of German hospitals will be available soon.

Conclusions: Preliminary results show significant differences in energy consumption between different ultrasound units and relatively high energy-consumption in stand-by-mode indicating a huge potential for reducing energy waste.

References

ULTRASOUND EVALUATION OF INFLAMMATORY BOWEL DISEASE IN CHILDREN

Rasa Augustiniene¹

1. Section of Ultrasound, Department of Pediatric Radiology, Centre of Radiology and Nuclear Medicine, Vilnius University Hospital Santaros Clinics

Abstract body

ACTUALITY AND AIM

Ultrasound is a primary method for investigating abdominal pain in children. A high-quality ultrasound allows to avoid more complicated examinations. Inflammatory bowel disease (IBD) can be evaluated by ultrasound.

MATERIAL AND METHODS

In this study, we present our clinical experience of using ultrasound to evaluate children with IBD. We conducted a retrospective analysis of 150 children with various IBD who underwent ultrasound examination using B-mode, colour Doppler, and in selected cases elastography, hydrocolonosonography and contrast-enhanced ultrasound (CEUS) between 2019 and 2022.

135 children had findings in the gastrointestinal tract, including bowel wall thickening > 3 mm, hypervascularity, prominent stratification and elasticity < 2.0 m/s, associated lymphadenopathy. These features decreased during recovery or remission. No abscesses nor perforations observed.

RESULTS

The sensitivity and specificity of the ultrasound examination were 90%. The ultrasound findings correlated with clinical and endoscopic exams and were reliable for diagnosis and monitoring of the dynamics of the disease.

CONCLUSIONS

Ultrasound is a reliable informative technique for evaluating and monitoring IBD in children, reducing the need for more complicated examinations.

References

1. Intestinal Ultrasound for the Pediatric Gastroenterologist. JPGN •Volume 76, Number 2, February 2023
 - 2.E.A. van Wassenae et al. Intestinal Ultrasound in Pediatric Inflammatory Bowel Disease: Promising, but Work in Progress, Inflammatory Bowel Diseases, 28 (2022): 783-787
 - 3.Contrast -Enhanced Ultrasound in Pediatric Imaging, 2021.
- Paul S.Sidhu et al. Contrast -Enhanced Ultrasound in Inflammatory Bowel Disease.
- Damjana Ključevšek
- 4.I.Limantoro et al. Spectrum of bowel wall thickening on ultrasound with pathological correlation in children, Pediatric Radiology (2022) 52:1786-1798

ULTRASOUND OF CONGENITAL LIVER VASCULAR SHUNTS

Andrius Čekuolis¹

1. Vilnius University, Faculty of Medicine, Institute of Clinical Medicine, Clinic of Obstetrics and Gynaecology; 2. Department of Pediatric Radiology, Centre of Radiology and Nuclear Medicine, Vilnius University Hospital Santaros Klinikos

Abstract body

ACTUALITY AND AIM. Congenital hepatic arteriovenous malformations (AVM) and pathological vascular shunts (PVS) are rare lesions associated with significant morbidity and mortality, mostly from high output cardiac failure. There is still no unified classification nor standardized treatment.

AVM and PVS can be single or multiple.

METHODS. We share our clinical experience in 4 patients with rare congenital hepatic vascular anomalies.

Patient A (newborn 1 day) had huge AVM. Patient B (newborn 1 day) had persistent ductus venosus and multiple anomalies. Patient C (aged 2 weeks) had anomalous hepatic vasculature associated with biliary atresia. Patient D with anomalous portosystemic junction was diagnosed lately.

RESULTS Despite severity, liver AVM and PVS are curable conditions. Patient A successfully treated by step-by-step embolisation. Patient B successfully embolized in one step, but died later due to multiple anomalies. Patient C required no vascular treatment, the outcome was unfavorable due to biliary atresia. Patient D underwent successful reconstructive vascular surgery.

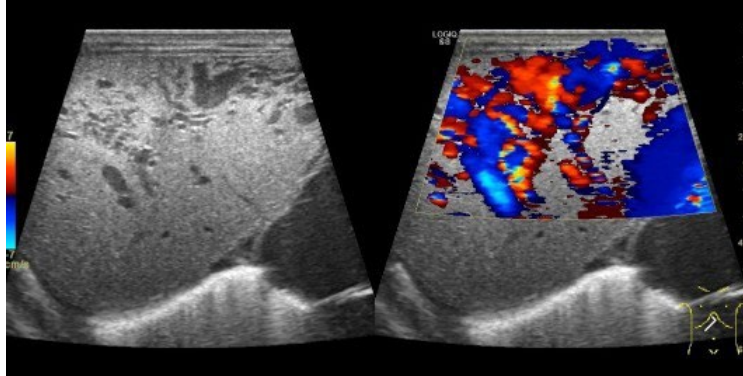
CONCLUSIONS AVM and PVS should be suspected in every newborn with congenital anomalies and/or high output cardiac failure. Ultrasound is the first modality to recognize the problem and point to the appropriate diagnostic and therapeutic actions

ACKNOWLEDGEMENTS All the team of Interventional Radiology

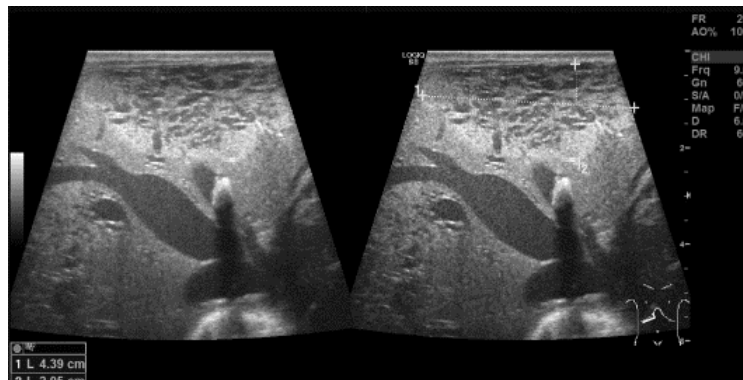
References

1. Hiroyuki et al. The classification based on intrahepatic portal system for congenital portosystemic shunts. J.Ped.Surg.50 (2015) 688-695
2. C.Gallego et al. Congenital Hepatic Shunts. Radiographics, May 2004:755-772
3. A.Chaturvedi et al. Ultrasound with Doppler evaluation of congenital hepatic vascular shunts. Pediatric Radiology (2018) 48:1658-1671
4. M.Papamichail et al. Congenital portosystemic venous shunt. Europ.J.of Pediatrics (2018) 177:285-294

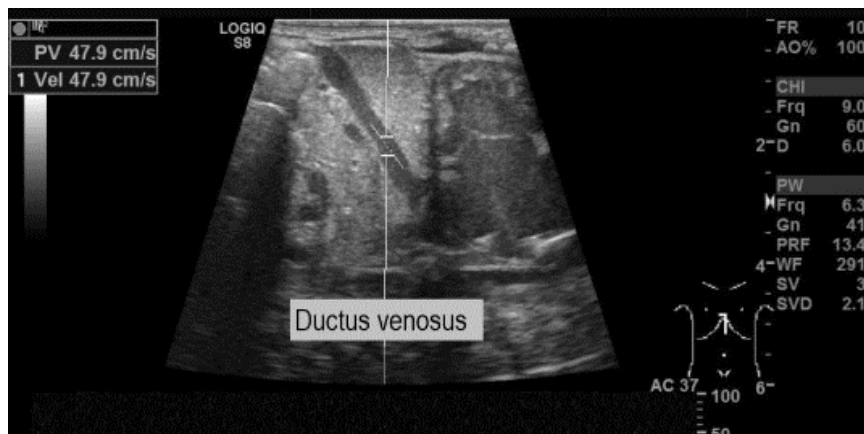
ULTRASOUND OF CONGENITAL LIVER VASCULAR SHUNTS



Liver AVM ultrasound.



Liver AVM ultrasound post 1st stage of embolisation.



Persistent ductus venosus Arantii.

USEFULNESS OF ULTRASOUND EXAMINATION IN THE DETECTION OF MEDULLARY THYROID CARCINOMA, IN PATIENTS WITH GRAVES' DISEASE

**Mihaela-Maria Vlad¹, Ioana Golu¹, Marioara Cornianu², Flore Varcus³,
Oana Popa¹, Andreea Toma¹**

1. Discipline of Endocrinology, "Victor Babes" University of Medicine and Pharmacy, Timisoara,
2. Discipline of Morphopathology, "Victor Babes" University of Medicine and Pharmacy, Timisoara,
3. 2nd Department of Surgery, "Victor Babes" University of Medicine and Pharmacy, Timisoara

Abstract body

Background: The detection of thyroid nodules in a patient with Graves' disease (GD) is not rare and ultrasound exam is useful for this. This paper describes the peculiarities of three cases with GD and a concurrent medullary thyroid carcinoma (MTC), a rare form of thyroid cancer derived from C cells.

Case 1: A 64-year-old woman was admitted in 2015 into our clinic due to severe thyrotoxicosis. Thyroid ultrasound revealed a diffuse low echogenicity of parenchyma and a small nodule of 1 cm in the left lobe (fig.1). Calcitonin level was mild increased (49 pg/ml, NV<11.5 pg/ml), raising the suspicion of MTC. Surgical therapy was recommended and the pathology revealed MTC of 0.7/0.9cm, on a diffuse thyroid hyperplasia (GD).

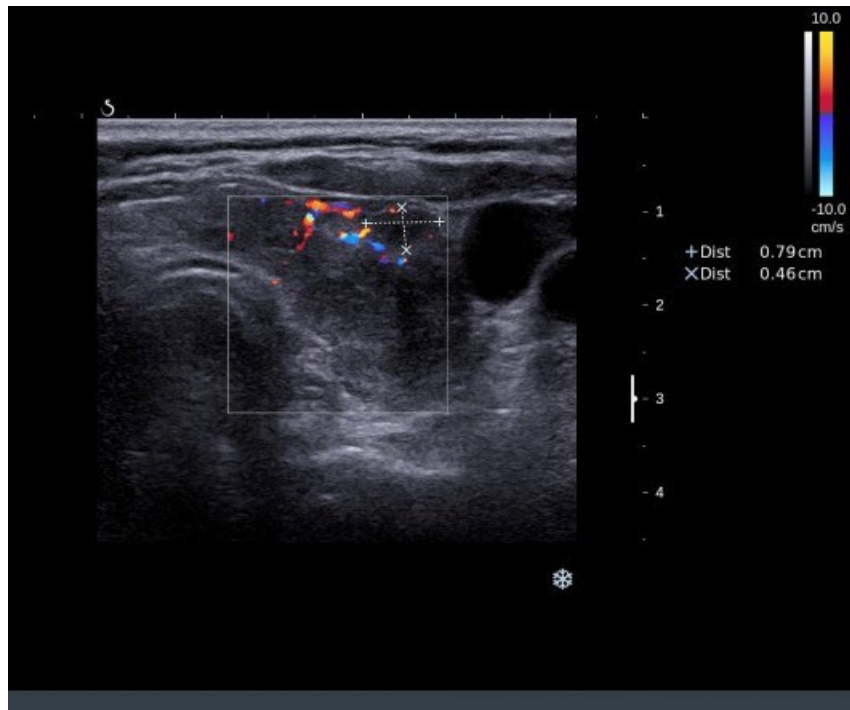
Case 2: A 79-year-old woman was admitted in 2022 into our clinic due to GD. The patient was diagnosed with GD in 2011 and since then she was treated with antithyroid drugs. Thyroid ultrasound revealed a diffuse low echogenicity of parenchyma and multiple nodules in the left lobe, with multiple coarse calcification inside (fig.2). The determination of Calcitonin revealed a significant high value (832 pg/ml), characteristic for MTC. The pathological result after thyroidectomy confirmed the MTC, on a diffuse thyroid hyperplasia (GD).

In conclusion, in these cases, ultrasonography and preoperative determination of calcitonin were useful for detection of the MTC associated to GD.

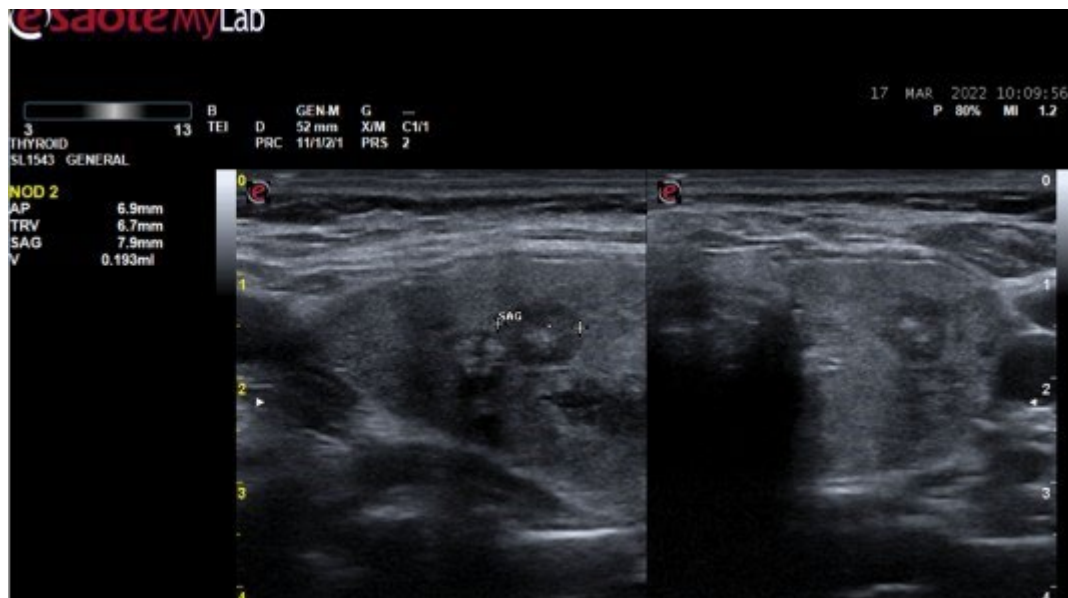
References

1. Sapalidis K, et al. A Rare Coexistence of Medullary Thyroid Cancer with Graves Disease: A Case Report and Systematic Review of the Literature. Am J Case Rep. 2019

USEFULNESS OF ULTRASOUND EXAMINATION IN THE DETECTION OF MEDULLARY THYROID CARCINOMA, IN PATIENTS WITH GRAVES' DISEASE



Nodule in the left thyroid lobe – case 1.



Nodules in the left lobe, with multiple coarse calcification inside.

ULTRASOUND OF ADOLESCENT BREASTS

AndriusČekuolis ¹

1. Vilnius University, Faculty of Medicine, Institute of Clinical Medicine, Clinic of Obstetrics and Gynaecology; 2. Department of Pediatric Radiology, Centre of Radiology and Nuclear Medicine, Vilnius University Hospital Santaros Klinikos

Abstract body

ACTUALITY AND AIM: To determine the need for breast ultrasound in adolescent girls.

METHODS. We share our clinical experience of sonography of breasts of non-symptomatic and symptomatic adolescents in 1999 – 2022, altogether 1274 girls. Healthy volunteers with non-breast problems (1043) and symptomatic girls (pain, mastitis, masses) (231) were included.

The girls were divided into 2 age groups: A: 9 – 13 years (417 girls); B: 14 – 18 years (857 girls), each subdivided respectively into A1(319)/B1(724) as nonsymptomatic, A2(98)/B2(133) symptomatic.

RESULTS. Most girls in A1/B1 presented no complaints related to breasts: 83% in A1, 77% in B1. Specifically asked, girls noted mastalgia (14% – 18% respectively). Nipple discharge, self-palpable masses were rare (<10%). Symptomatic girls complained of pain/mass/swelling. More findings were detected in A1/A2: mostly ductal ectasia and cysts.

Most girls with mastitis had cystic lesions. Most masses („hidden“ or palpable) were fibroadenomas. No malignancies detected.

CONCLUSIONS. Various sonographically detected breast abnormalities were found in >9 % of non-complaining girls. The incidence decreases with breast formation and maturation. Breast masses are rare, but not all girls can recognize the problem. They should be trained for self-checkup, prophylactic breast ultrasound we recommend once in late adolescence.

ACKNOWLEDGEMENTS. For the brave girls

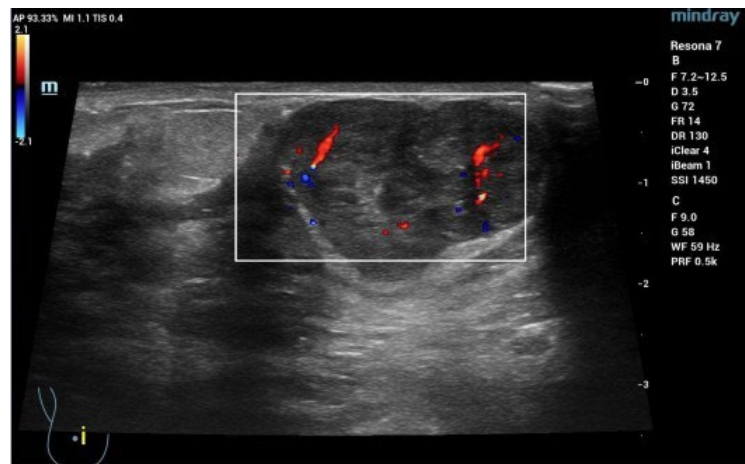
References

Kaneda HJ et al. Pediatric and adolescent breast masses: review of pathophysiology, imaging, diagnosis, and treatment. AJR2013; 200:W204-W212

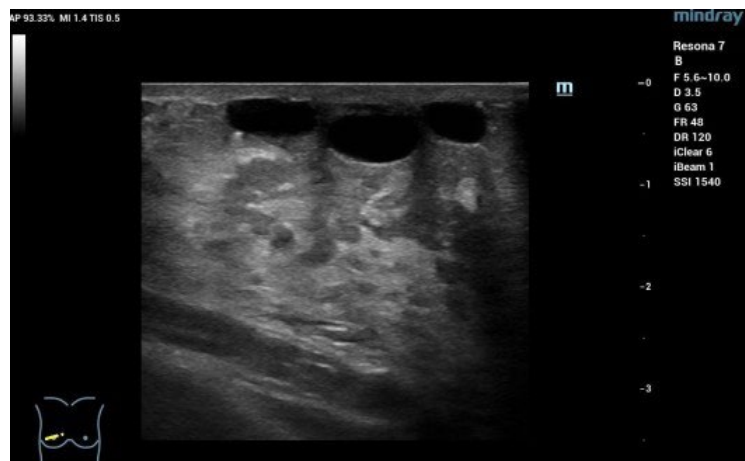Greydanus DE et al. Breast concerns and disorders in adolescent females: a narrative review. Pediatr Med 2019;2:28 |

Siegel MJ et al. Breast masses in children and adolescents. Appl Radiol. 2017;46(9):12-17

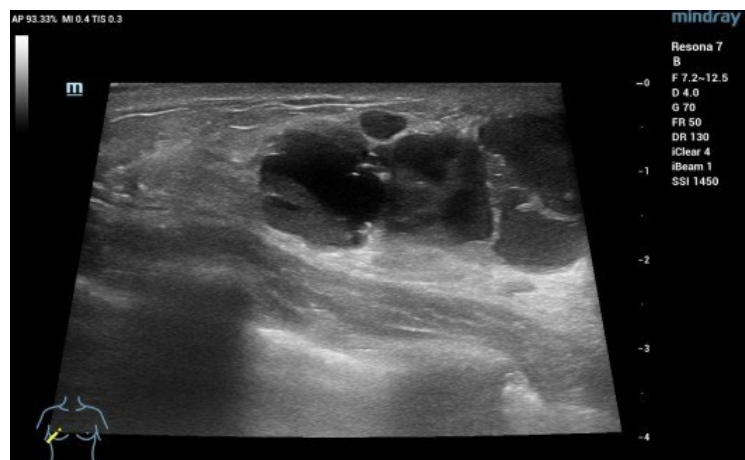
ULTRASOUND OF ADOLESCENT BREASTS



Palpable breast mass.



Breast cysts.



Mastitis and breast cysts.

ULTRASOUND EVALUATION PROTOCOL OF ARTERIOVENOUS FISTULA AND POSSIBLE COMPLICATIONS

Rūta Kliokytė¹

1. Vilnius University Hospital Santaros klinikos

Abstract body

Learning objectives: The use of ultrasound in: 1) pre-fistula evaluation of the site; 2) evaluation and suitability of arterio-venous fistula (AVF) for dialysis; 3) characterizing the most common complications of AVF.

Background: In 2020 there were ~130 incident patients per million population (pmp) accepted for kidney replacement therapy (KRT), however kidney transplantation rate was far lower at ~31 pmp. Haemodialysis is most prevalent KRT and acquired AVF is a method of choice for vascular access in patients under long-term hemodialysis.

Findings: It is preferred to form a radio-cephalic AVF in the non-dominant hand. Accepted vessel calibers for AVF formation: vein more than 2.5 mm and artery more than 2.0 mm. After formation within 6-8 weeks the AVF can be evaluated. The criteria of a mature fistula are: the draining vein should have a minimum diameter of 4 mm with a depth of up to 5 mm from the skin; the volume flow in the associated vessel should be >500 ml/min. Common complications include: stenosis of the anastomosis or any of the vessels used in the formation of the AVF (significant if there's >50% diameter reduction); thrombosis and aneurysms most often seen in the draining vein; perivascular collections; steal syndrome.

Conclusions: ultrasound is indispensable both in the planning and consequent evaluation of AVF during its' lifetime. Early ultrasound diagnosis of complications help to plan appropriate treatment which may prolong AVF patency.

References

References:

1. AIUM Practice Parameter for the Performance of Vascular Ultrasound Examinations for Postoperative Assessment of Hemodialysis Access. *J Ultrasound Med.* 2020 May;39(5):E39-E48. doi: 10.1002/jum.15262. Epub 2020 Mar 12. PMID: 32162362.
2. Lok CE, Huber TS, Lee T, Shenoy S, Yevzin AS, Abreo K, Allon M, Asif A, Astor BC, Glickman MH, Graham J, Moist LM, Rajan DK, Roberts C, Vachharajani TJ, Valentini RP; National Kidney Foundation. KDOQI Clinical Practice Guideline for Vascular Access: 2019 Update. *Am J Kidney Dis.* 2020 Apr;75(4 Suppl 2):S1-S164. doi: 10.1053/j.ajkd.2019.12.001. Epub 2020 Mar 12. Erratum in: *Am J Kidney Dis.* 2021 Apr;77(4):551. PMID: 32778223.
3. Boenink R, Astley ME, Huijben JA, Stel VS, Kerschbaum J, Ots-Rosenberg M, Åsberg AA, Lopot F, Golan E, Castro de la Nuez P, Rodríguez Cambor M, Trujillo-Alemán S, Ruiz San Millán JC, Ucio Mingo P, Díaz JM, Bouzas-Caamaño ME, Artamendi M, Aparicio Madre MI, Santiuste de Pablos C, Slon Roblero MF, Zurriaga O, Stendahl ME, Bell S, Idriji A, Ioannou K, Debska-Slizien A, Galvão AA, De Meester JM, Resić H, Hommel K, Radunovic D, Pålsson R, Lassalle M, Finne P, De Los Angeles-García Bazaga M, Gjorgjievski N, Seyahi N, Bonthuis M, Ortiz A, Jager KJ, Kramer A. The ERA Registry Annual Report 2019: summary and age comparisons. *Clin Kidney J.* 2021 Dec 15;15(3):452-472. doi: 10.1093/ckj/sfab273. PMID: 35211303; PMCID: PMC8862051.

THE PLACE OF ULTRASOUND IN VASCULAR ANOMALIES

***Lina Mickevičienė*¹, Artūras Samuilis², Darius Palionis², Birutė Vaišnytė³**

1. Vilnius university hospital Santaros Clinic, Department of Radiology and Nuclear medicine,

2. Vilnius university hospital Santaros Clinic, Department of Radiology and Nuclear medicine,

3. Vilnius university hospital Santaros Clinic, Department of Vascular Surgery

Abstract body

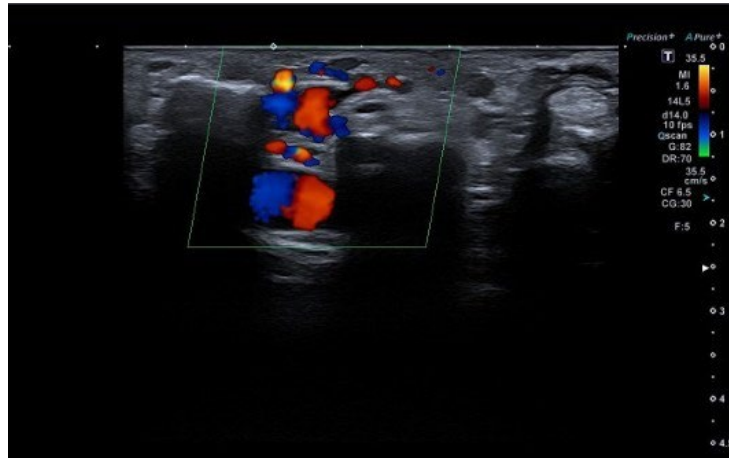
The vascular anomalies have low incidence and heterogenous presentation of clinical and imaging findings. This leads to misdiagnosis and prolonged access of the patient to the necessary specialist causing delayed or inappropriate treatment. The ultrasound examination is the first choice of imaging modality for vascular anomalies due to wide availability, low-cost, non-ionizing technology and the ability to provide lesions' flow characteristics. In this presentation the principles and main findings of ultrasound examination in vascular anomalies will be discussed based on ISSVA (International Society for the Study of Vascular Anomalies) classification and our clinical cases during the 5 years period starting 2018 to 2022. Grayscale sonography along with color and spectral Doppler can accurately diagnose most of the cases together with clinical findings and can be used for dynamic follow up, and for the follow up after treatment. Despite all ultrasound examination advantages the diagnostic accuracy depends on operator's experience, patient's age and constitution, and the most important - location, size and extent of the vascular anomaly. Thus, magnetic resonance imaging has proven advantageous to define extent of the lesions and guide appropriate treatment.

References

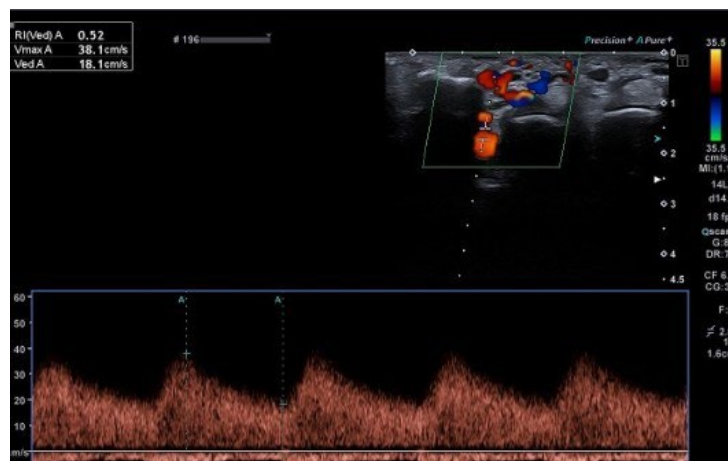
Mittal A, Anand R, Gauba R, Choudhury SR, Abbey P. A Step-by-Step Sonographic Approach to Vascular Anomalies in the Pediatric Population: A Pictorial Essay. Indian J Radiol Imaging. 2021 Jan;31(1):157-171. doi: 10.1055/s-0041-1729486. Epub 2021 May 13. PMID: 34316124; PMCID: PMC8299503.

Kunimoto K, Yamamoto Y, Jinnin M. ISSVA Classification of Vascular Anomalies and Molecular Biology. Int J Mol Sci. 2022 Feb 21;23(4):2358. doi: 10.3390/ijms23042358. PMID: 35216474; PMCID: PMC8876303.

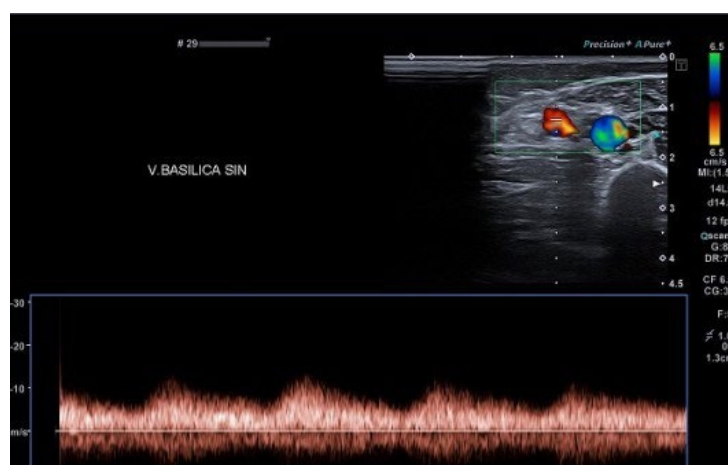
THE PLACE OF ULTRASOUND IN VASCULAR ANOMALIES



An arteriovenous malformation (AVM) of the left hand.



The arteries showed low-resistance flow with a RI of 0,52.



There was arterialization of venous flow in the basilic vein.

ULTRASOUND INTERVENTIONS FOR BEGINNERS: 7 TIPS FOR A SUCCESSFUL FIRST PROCEDURE

Kipras Mikelis¹

1. Vilnius University hospital Santaros klinikos

Abstract body

LEARNING OBJECTIVES

To review the basic theory required to perform ultrasound guided interventions.

BACKGROUND

First time a physician performs an ultrasound guided intervention can be daunting because of a different skill set required in comparison to diagnostic ultrasound procedures.

FINDINGS

The main steps when preparing for an ultrasound guided interventional procedure are a thorough review of patients history, anatomy and blood tests, informing the patient of the upcoming procedure, optimizing imaging quality for the procedure, needle tip visualization, proper anesthesia, being aware of possible complications and practice of these specific skills.

CONCLUSIONS

The number of minimally invasive procedures is increasing as is the number of physicians performing these procedures. A good grasp of theory and practice is required to ensure the safety and good results of ultrasound guided interventions.

ACKNOWLEDGEMENTS

Thank you to Drs. D.Jocius, J.Jarašūnas and E.Dumskis for providing case images for the presentation.

References

-

CEUS IN EARLY FOLLOW-UP AFTER CRYOABLATION OF RENAL CANCER

***Donatas Jocius Jocius*¹, Albertas Cekauskas¹**

1.Vilnius University Hospital Santaros Klinikos

Abstract body

Actuality

Initial follow up using imaging on local ablative therapies are not strictly defined. Usually, it is arranged similar to surgical renal cancer treatment, although it may not be optimal since pathological examination of surgical specimen immediately informs regarding the radicality of the procedure and thus first follow up is set after 6 months. On the other hand, in ablation setting one do not have information on this aspect and earlier follow up may be of value.

Aim

To investigate whether CEUS could be an initial tool for first follow up modality after renal cancer cryoablation treatment.

Materials and methods

We retrospectively analyzed postprocedural CEUS performed at one month after renal tumor cryoablation in our center. Data of over 40 patients was evaluated.

Results

During initial follow-up at one month 23 (out of 42) patients underwent CEUS examination and in 2 cases suspicious findings were present requiring nonplanned CECT. One case confirmed suspicious area in treatment zone and was retreated subsequently.

Conclusions

CEUS may be helpful and safe alternative in early assessment of local ablative therapy such as renal cryoablation only selecting those patients which have suspicious or inconclusive findings omitting unnecessary early CT examination.

References

Guo F, Hu B, Chen L, Li J. Clinical application of contrast-enhanced ultrasound after percutaneous renal tumor ablation. Br J Radiol. 2019 Nov;92(1103):20190183. doi: 10.1259/bjr.20190183. Epub 2019 Oct 1. PMID: 31509441; PMCID: PMC6849667.

THYROID NODULE ABLATION

Donatas Jocius¹, Romena Laukiene¹, Anatolij Ostapenko¹

1. Vilnius University hospital Santaros Klinikos

Abstract body

Actuality and aim

The purpose of our retrospective case series study was to present early outcomes after thyroid nodule microwave ablation.

Materials and methods

We performed a retrospective analysis of patients with benign thyroid nodules treated with microwave ablation. Thyroid nodule ablation procedure was performed under conscious sedation adding local anesthetics.

First follow-up was scheduled one month after the procedure evaluating clinical outcome and contrast enhanced ultrasound (CEUS).

Results

9 patients were enrolled. All patients were referred for thyroid microwave ablation by multidisciplinary team. 8 patients complained of neck deformation and/or neck discomfort and one had autonomous nodule altogether with neck deformation.

Initial average nodule size was 3,26 x 2,71 cm and after thirty days average nodule size decreased to 2,7 x 2,07 cm. Nodule vascularity evaluated by CEUS was also decreased with most of the nodules presenting with central avascular zone. Clinical benefit was present in 6 cases that showed early reduction of neck deformation.

Conclusion

The results of our case series show that even at an early period notable decrease of thyroid nodule size is present in patients treated with microwave ablation. Further evaluation is warranted in this group evaluating late results since literature indicates lesion size decrease up to 6 months.

References

Papini E, Monpeyssen H, Frasoldati A, Hegedüs L. 2020 European Thyroid Association Clinical Practice Guideline for the Use of Image-Guided Ablation in Benign Thyroid Nodules. Eur Thyroid J. 2020 Jul;9(4):172-185. doi: 10.1159/000508484. Epub 2020 Jun 8. PMID: 32903999; PMCID: PMC7445670.

INTERESTING CASES FROM VILNIUS UNIVERSITY SANTAROS CLINICS ULTRASOUND ROOM EXPERIENCE – ACUTE LOWER ABDOMINAL PAIN

Laura Žilevičė¹

1. Vilnius University Faculty of Medicine

Abstract body

Learning objectives: To differentiate acute lower abdominal pain pathologic findings in an emergency department. Outline the most common causes of pelvic pain. Describe interesting imaging findings associated with acute lower abdomen pain. Beyond that, highlight some uncommon cases.

Background: A lower abdomen ultrasound is frequently the first choice, noninvasive diagnostic imaging to assess organ size, anatomical and pathologic changes, and additional structures in the patient pelvis. It allows quick scans with linear and convex transducers for acute lower abdominal pain localization, which is quite a common problem in the emergency department. Pelvic pain can be a quite challenging complaint because of the wide variety of pathologic conditions. The main pain location groups are gynecological, bowel, and urinary pathologies. For the final patient diagnosis, it is crucial to know the full patient's history and additional symptoms.

Findings: We reviewed cases with lower abdomen pathologies in our emergency radiology department at Vilnius University Santaros Clinics for the most interesting cases in patients with acute lower abdominal pain. The most common findings in our emergency department are appendicitis, diverticulitis, ovarian cysts, and those pathology complications. Less commonly seen pathologies are incidental findings such as cancer, tumor abscess, urinary bladder stones, and other acute gynecological entities.

Conclusions: Ultrasound examination is the first choice imaging modality for the initial evaluation of acute pelvic pain cause, especially for female patients.

Acknowledgments: I would like to extend my sincere thanks to all of Vilnius University Santaros Clinics' emergency department team.

References

Cases are from Vilnius University Santaros Clinics.

RENAL DUPLEX EXAMINATION FOR BEGINNERS

Igne Gecaite - Paukste¹

1. Vilnius university hospital Santaros klinikos

Abstract body

Learning objectives: Outline renal vascular anatomy and the most common anatomic variations. Summarize indications for a renal Doppler ultrasound examination for native kidneys. Explain the typical equipment required for a renal Doppler ultrasound, describe patient's preparation and the course of the procedure. Describe classic imaging findings associated with various renal vascular pathology.

Background: The most common Doppler US indications for native renal arteries include hypertension and follow-up of patients with the known renovascular disease who are under medical supervision or after the endovascular intervention. The study is performed using color, power and spectral Doppler, in general the curvilinear transducer is preferred.

Findings: Kidneys should be evaluated with B-mode grayscale imaging, blood flow evaluation with color Doppler images should be performed in the proximal, mid, and distal renal arteries bilaterally, intraparenchymal resistive index (RI) should be measured. Renal artery stenosis represents the most common cause of secondary hypertension. Direct US signs of this pathology are PSV > 200 cm/s (compatible with ≥60% stenosis), increased renal/aortic PSV ratio (>3.5:1), absence of Doppler US signal consistent with occlusion, and aliasing with post-stenotic turbulent flow/spectral broadening.

Conclusions: Doppler US examination of the renal vasculature plays a critical role in the evaluation of native kidneys. US study is highly operator-dependent, therefore knowing renal anatomy, fundamental concepts of the study and nomenclature is crucial.

References

Trunz LM, Balasubramanya R. Doppler Renal Assessment, Protocols, And Interpretation. In: StatPearls [Internet]. Treasure Island (FL): StatPearls Publishing; 2022 [cited 2023 Jan 17]. Available from: <http://www.ncbi.nlm.nih.gov/books/NBK572135/>

NOTES FROM AN INTERVENTIONAL RADIOLOGIST – A BRIDGE BETWEEN A DIAGNOSTIC RADIOLOGIST AND A VASCULAR SURGEON IN A LOWER LIMB VENOUS PATHOLOGY

Rokas Gircius¹

1. Vilnius University Hospital Santaros Clinics

Abstract body

Learning objectives – to point out the essential findings for a routine lower limb venous US examination and look for specific pathology signs to determine the best treatment options.

Background – lower limb venous diagnostic imaging requires an ultimate focus and knowledge of a full physiology and pathology spectrum. Given the nature of patients management and a utility of an ultrasound not only for a diagnostic, but any interventions, diagnostic specialists are prone to find themselves in a position of which findings to prioritize and what to remark.

Findings – during a presentation we will explore most common pathologies such as lower limb venous thrombosis, chronic venous disease, postthrombotic syndrome, venous malformations and look for valuable diagnostic insights.

Conclusions – US is an essential diagnostic and guiding tool for treating lower limb venous pathologies.

References

- Sherry Scovell, MD, FACS. Superficial vein thrombosis and phlebitis of the lower extremity veins, 2022-12, UpToDate.
- Gregory YH Lip, MD, FRCPE, FESC, FACC, Russell D Hull, MBBS, MSc. Overview of the treatment of proximal and distal lower extremity deep vein thrombosis (DVT), 2022-12, UpToDate.
- Lowell S Kabnick, MD, RPhS, FACS, FACPh, Sherry Scovell, MD, FACS. Overview of lower extremity chronic venous disease, 2022-12, UpToDate.
- Susan R Kahn, MD, MSc, FRCPC, Barbara M Mathes, MD, FACP, FAAD. Post-thrombotic (postphlebotic) syndrome, 2022-12, UpToDate
- Laurence M Boon, MD, PhD, Miikka Vikkula, MD, PhD, Emmanuel Seront, MD, PhD. Venous malformations, 2022-12, UpToDate.

ULTRASOUND EVALUATION OF ACUTE SCROTAL PATHOLOGY

Irvinas Muliolis¹

1. Vilnius University Hospital Santara Clinics

Abstract body

Learning objectives:

The main objective is to provide a practical review of the most common ultrasound findings in patients presenting with acute scrotal pain in an emergency setting. Provide information about normal scrotal anatomy and the proper scanning technique. And lastly, highlight some pitfalls and unusual cases.

Background:

When a patient presents with acute scrotal pain, an ultrasound scan is a crucial diagnostic tool for determining the correct diagnosis. The testicles and surrounding structures can be seen in excellent anatomic detail using a high frequency linear array transducer. It can help differentiate the most important causes of acute scrotal pain, such as epididymitis and testicular torsion, and is the imaging technique of choice for acute scrotal trauma. Additionally, color and spectral Doppler analysis allows us to evaluate vascular perfusion which is a key point in determining the urgency of treatment.

Findings:

We performed a literature search and reviewed numerous cases archived in the radiology department of the Vilnius University hospital Santara clinics to find examples that illustrate the common ultrasound findings encountered in patients with acute scrotal pain. In the majority of cases a well performed ultrasound examination suggested a specific diagnosis and enhanced the management of said patients.

Conclusions:

The primary imaging modality for assessing acute scrotal disorders is ultrasonography. It is a safe, cost-effective, easily accessible and reliable technique for displaying scrotal morphology, pinpointing testicular lesions, and assessing vascularity.

References

Numerous cases archived in the radiology department of the Vilnius University hospital Santara clinics.

ADVANCED ULTRASOUND SMI TECHNIQUE FOR THE ASSESSMENT OF ATHEROSCLEROTIC PLAQUE MICROVASCULARIZATION

GALINA BALTGAILE¹

1. Medical Clinic ARS, Riga Stradins University, Neurological Department

Abstract body

Actuality and Aim: Echolucency of carotid atherosclerotic plaques detected using color coded dopplerography (CCDS) and intraplaque microvascularization (IPMV) by contrast-enhanced ultrasound (CEUS) have been identified as potential markers of plaque inflammation and vulnerability. Although IPNV contributes to the progression and rupture of atherosclerotic lesions, there is some conflicting evidence in the literature on a temporal association of intraplaque inflammation, hemorrhage and IPMV. Non-invasive superior microvascular imaging (SMI) designed to overcome the limitations of detection low flow IPMV has been applied to examine symptomatic and non-symptomatic carotid plaques.

Method: 67 patients with symptomatic and non-symptomatic carotid plaques > 2mm have been examined by CCDS with SMI during 3 years. 63 of them used statins and antiaggregants on daily basis. IPMV was graded from 0 to 2 and compared to plaque's echogenicity and growth.

Results: Data of IPMV in 12 patients has been excluded from the analysis due to the difficulty in distinguishing the microvessels image from calcification in plaques. There was strong correlation between the absence of IPMV and the

plaque growth arrest. No statistically significant correlation found between the IPMV and rapid plaque growing, although in all 7 cases with echolucent spots In symptomatic heterogenic plaques, suspicious of intraplaque hemorrhage, 1-2 grades neovascularization has been found.

Conclusion: The limited number of patients in our study and the multifaceted pathophysiology of the atherosclerotic plaque may explain the absence of statistically significant correlation between plaque inflammation and IPMV.

References

X Chen , H Wang , Neovascularization by superb microvascular imaging (SMI): Initial experience, SVM, vol25, is.4, 2020

US IN CHRONIC GRANULOMATOUS DISEASE

Egle Simanauskiene¹, Andrius Cekuolis²

1. Vilnius University, Faculty of Medicine. 2. Vilnius University Hospital Santaros Klinikos, Department of Pediatric Radiology, 2. Vilnius University, Faculty of Medicine, Institute of Clinical Medicine, Clinic of Obstetrics and Gynaecology; 2. Department of Pediatric Radiology, Centre of Radiology and Nuclear Medicine, Vilnius University Hospital Santaros Klinikos

Abstract body

Background

Chronic granulomatous disease (CGD) is a rare genetically predisposed immunodeficiency disorder, usually manifesting in childhood by recurrent bacterial and fungal infections. It features a poor response to antibacterial therapy and granuloma formation.

The disease involves multiple organs and systems. The onset of infection can start at any age from newborn.

Our cases

We had four cases of X linked CGD disease in 2009-2023, all were boys.

In all cases the disease was suspected and diagnosed after unusually frequent bacterial infection and poor response to antibacterial treatment.

Ultrasound was important both for detecting the abscesses and granulomas and for follow-up.

The role of interventions is debatable. Minimally invasive US guided methods are the first choice for aspiration and identification of the causative agent.

Conclusions

Early diagnose is very important for the survival of these patients, and ultrasound specialist can also be the one to suspect the disorder.

References

- Lee M et al. Spectrum of imaging findings of chronic granulomatous disease: a single center experience. *Diagn Interv Radiol*. 2017 Nov-Dec;23(6):472-477.
- Yao Q et al. Imaging findings of pulmonary manifestations of chronic granulomatous disease in a large single center from Shanghai, China (1999-2018). *Sci Rep*. 2020 Nov 9;10(1):19349.
- Leiding JW et al. Chronic Granulomatous Disease. 2012 Aug 9 [Updated 2022 Apr 21]. In: Adam MP, Everman DB, Mirzaa GM, et al., editors. *GeneReviews* [Internet]. Seattle (WA): University of Washington, Seattle; 1993-2022.

CEUS IN KIDNEY PATHOLOGY IN CHILDREN: OPPORTUNITIES AND PROSPECTS

Viktor Zhelov¹, Olga Pushkarenko²

1. Western Ukrainian Specialized Children's Medical Center, Head, Ultrasound & Interventional,

2. Uzhhorod National University, Radiologist

Abstract body

Kidney pathology in children is an area of medicine that is expanding in complexity and importance. However, traditional ultrasound (US) has certain limitations and cannot compete with computed tomographic (CT) and magnetic resonance (MR) imaging.

Contrast-enhanced ultrasound (CEUS) is a newer form of US that uses microbubbles, which are CEUS in kidney pathology in children: opportunities and prospects extremely safe and well-tolerated pure intravascular agents that can be used in renal failure and obstruction, instead of CT and MR contrast agents. Their intravascular distribution allows for quantitative analysis of the microcirculation, and qualitative assessment of tumor vascularity and enhancement patterns.

The aim of this presentation is to offer an overview of the possibilities and potential applications of CEUS in kidney disease in children.

During the period June-December 2022, within the framework of the Ukrainian CEUS Project, we conducted 76 CEUS studies on 53 patients with acute and chronic kidney diseases, kidney tumors, as well as for the purpose of assessing the kidney transplant, voiding cystography and for control after interventions.

The current evidence suggests that CEUS imaging is a reliable and effective tool for the diagnosis and evaluation of pediatric renal pathology. This study has revealed the feasibility of CEUS as a reliable method in evaluating renal microvascular perfusion in native kidney and kidney allograft.

References

1. Antonio Granata, et al. Role of (CEUS) in Native Kidney Pathology: Diagnostics 2021 Jun 8;11(6):1058. doi: 10.3390/diagnostics11061058.
2. Paul S Sidhu, et al. Role of (CEUS) in Paediatric Practice: An EFSUMB Position Statement. Ultraschall Med 2017 Jan;38(1):33-43.

USEFULNESS OF ULTRASOUND IN DIAGNOSIS OF UPPER LIMB NERVE DAMAGE.

***Ludmila Klimchuk*¹, Oxana Haiko¹, Roman Luchko¹**

1. State institution «Institute of traumatology and orthopedics of NAMS of Ukraine»

Abstract body

Objectives: ultrasound is widely used in diagnosis of peripheral nerve pathology: in traumatic injuries and tunnel neuropathies.

Materials: an ultrasound examination was performed on 97 patients aged 14 to 60 years with lesions of the peripheral nerves of the upper limb. All patients underwent sonography on a LOGIQ P9 ultrasound device with 5-12 MHz multi-frequency transducer.

Results: 55 (56.7%) were diagnosed with tunnel neuropathies (carpal and cubital syndrome, Guyon's canal syndrome), and 42 (43.3%) with traumatic injuries of the median, ulnar, and radial nerves of varying severity and location. Carpal tunnel syndrome prevailed among tunnel syndromes, while ulnar nerve injury - among traumatic neuropathies.

In the cases of traumatic neuropathies the level, extent and degree of the injury (changes in the intra-trunk topography of the nerve in the form of a disturbance of the fascicular pattern, the presence of a traumatic neuroma, in the case of neurotmesis the diastasis between the ends) were determined.

In the cases of tunnel neuropathies the following were found: a change in the shape and area of the nerve, a decrease in echogenicity with the structural changes pattern at the level of the corresponding channel.

Conclusions: Ultrasound examination is an objective and highly informative method of diagnosis in case of damage to the peripheral nerves of the upper limb

References

Klymchuk L.I., Haiko O.H., Luchko R.V., Halii Y.I., Tymochenko S.V. Ultrasound examination of the median nerve in the diagnosis of carpal tunnel syndrome. Ортопедия, травматология и протезирование. 2020. No 3 (620):36-43. doi: 10.15674/0030-59872020336-43

UNUSUAL ULTRASOUND APPEARANCE OF GIGANTIC LIVER HYDATID CYST: A CASE REPORT

***Ioanitu Elena Simona*¹, Grasu Mugur², Hrehoret Doina³, Rababoc Razvan⁴, Simu Razvan⁴, Istrate Mircea⁴, Iliescu Elena Laura⁴**

1. „Carol Davila” University of Medicine and Pharmacy, Bucharest; Internal Medicine Clinic, Fundeni Clinical Institute, Bucharest, 2. „Carol Davila” University of Medicine and Pharmacy, Bucharest, Romania; Radiology and Medical Imaging Dept, Fundeni Clinical Institute, Bucharest, Romania, 3. „Carol Davila” University of Medicine and Pharmacy, Bucharest, Romania; General Surgery Clinic, Fundeni Clinical Institute, Bucharest, Romania, 4. „Carol Davila” University of Medicine and Pharmacy, Bucharest, Romania; Internal Medicine Clinic, Fundeni Clinical Institute, Bucharest, Romania

Abstract body

Background. Hydatid disease still remains a public health problem in Romania. Its appearance varies depending on the stage of cyst growth, associated complications and affected tissue, ranging from purely cystic lesions to a completely solid appearance. Ultrasound is the first-line imaging method used for hydatid liver disease diagnosis.

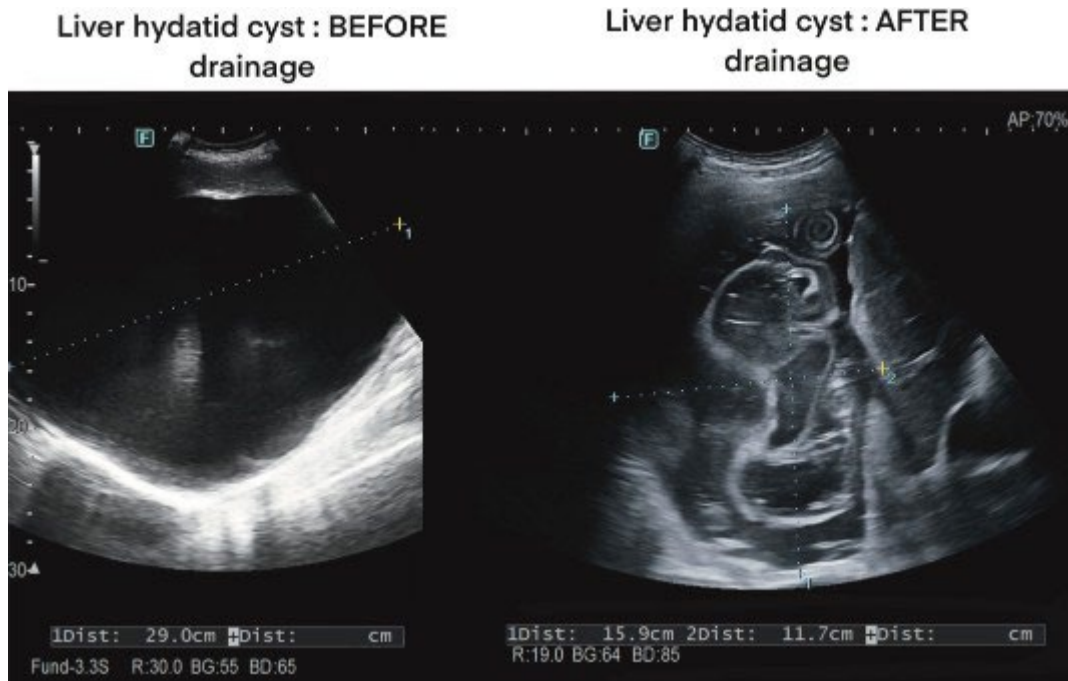
Case report. We present the case of a giant hepatic hydatid cyst in a 52-year-old patient who presented to the hospital with heartburn and pain irradiating to the right upper quadrant and shortness of breath. Symptoms started 7 days before admittance. Both US and computed tomography (CT) showed a purely cystic lesion occupying the entire right liver lobe (29 cm in diameter), with suspicion of a hemorrhagic cyst. After drainage, a hydatid cyst with detached proliger membrane (“waterlily sign”) was revealed on US and CT, classified as CE3 according to WHO-IWGE (Gharbi type 2). Surgical treatment for hydatid cyst complicated with post-drainage bilious fistula was performed. The patient also received oral Albendazole therapy before and after surgery.

Conclusions. This case highlights the diagnosis of hydatid disease can be difficult and that we must pay attention to the patient’s history and post-drainage complications. The hydatid cyst can be asymptomatic for a long time. US and CT are the best imaging techniques for liver hydatid cysts diagnosis. Surgery remains the best treatment option.

References

1. Turgut AT et al. Sonographic spectrum of hydatid disease. *Ultrasound Q.* 2008 Mar;24(1):17-29.
2. Tévez et al. Hydatidosis: Clinical-imaging classification according to Gharbi and the World Health Organization. *Rev Argentina Radiol.* 2022;86(1):41-8.

UNUSUAL ULTRASOUND APPEARANCE OF GIGANTIC LIVER HYDATID CYST: A CASE REPORT



Liver hydatid cyst - before and after drainage.

USEFULNESS OF ELASTOGRAPHY IN PREDICTING INDUCTION TO FULL DILATATION TIME INTERVAL

Natālija Vedmedovska¹, **Laura Rācene**¹, **LīvaĶīse**¹, **Laura Isajeva**²,
Beāte Sārta³, **Agnija Vecvagare**³, **Ieva Pitkēviča**³, **Zane Rostoka**³,
Ļubova Lapidus³, **Dace Rezeberga**⁴

1. Department of Obstetrics and Gynaecology, Rīga Stradiņš University; Riga Maternity Hospital,
2. Department of Public Health and Epidemiology, Faculty of Public Health and Welfare, Rīga Stradiņš University,
3. Faculty of Residency, Rīga Stradiņš University, 4. Department of Obstetrics and Gynaecology, Rīga Stradiņš University; Riga Maternity Hospital; Gynaecology Clinic, Riga East University Hospital

Abstract body

Actuality and Aim

Induction of labour (IOL) is common obstetric procedure. Novel predictive factors for successful IOL are investigated. The aim is to evaluate the impact of cervical tissue stiffness on “induction-to-full dilatation” time interval.

Methods

The study enrolled 50 patients - healthy primiparas, singleton pregnancy, Bishop score ≤ 6 . They were induced by combined method – transcervical Foley catheter and oral misoprostol. Cervical tissue strain elastography was performed prior to IOL on GE Versana Premier ultrasound machine. The cervical canal was visualised in sagittal plane, the elasticity of the internal and external cervical os, and canal was assessed by colour score from red (softest) to blue (hardest). Elasticity index (EI) was calculated by software.

Statistical relationship between preinterventional cervical elastogram and time to full dilatation were analysed. Significance level for Pearson correlation denoted by the alpha of 0.05.

Results

42 females were eligible for the analysis. The median EI of cervical canal, internal, external os were 2.2 (IQR 1.6), 2.9 (IQR 2.5), 2.2 (1.6), respectively. The median colour score of internal and external os – soft, cervical canal – medium soft.

The correlation between EI and time from starting IOL to full cervical dilation was insignificant for all cervical regions ($r = 0.12-0.26$). Correlation coefficient of colour score was also very low ($r = 0.04-0.27$).

Conclusion

The cervical stiffness cannot predict the time interval between the initiation of IOL to full cervical dilatation. Further research in larger population is required.

Acknowledgements

This research is funded by the Latvian Council of Science No. Izp-2021/1-0300.

References

-

THE ROLE OF BREAST ULTRASOUND BREAST CANCER SCREENING

***Jacob Roxana*¹, Stoicescu Emil Robert¹, Manolescu Diana¹**

1. Victor Babes University of Medicine and Pharmacy Timisoara, Discipline of Radiology and Medical Imaging

Abstract body

Actuality and Aim: One of the most prevalent cancers in the world and the leading cause of mortality and suffering in women is breast cancer. Because breast cancer cannot be cured once it has spread to other parts of the body, early detection is essential. The purpose of this research is to show the value of bedside breast ultrasound in the early detection of breast cancer.

Material and Methods: The three-month study included 47 female patients admitted to the “Dr. Victor Babes” Hospital of Pneumoftiziologie and Infectious Diseases in Timisoara. Patients were questioned about their personal history, comorbidities, and family history of breast cancer-related pathologies before being evaluated with bedside ultrasound.

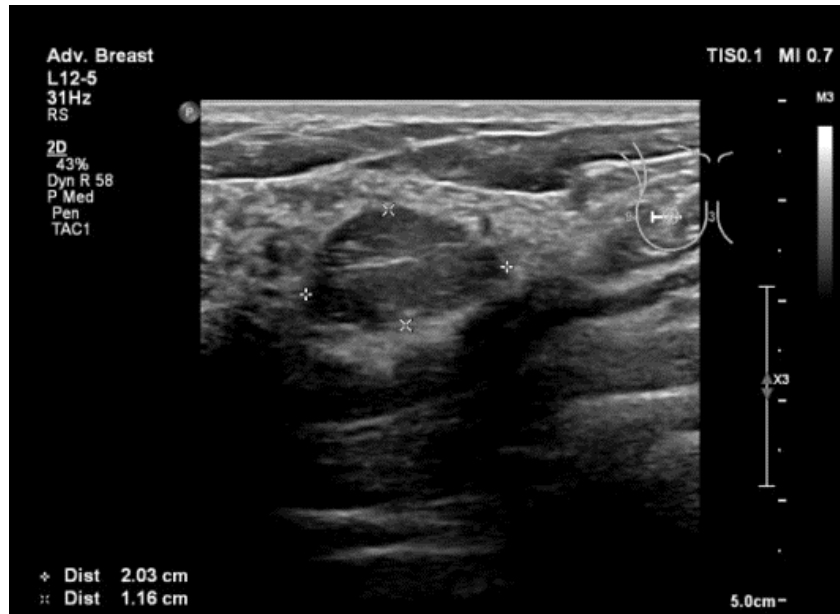Results: Two of the 47 patients were already diagnosed with breast cancer, so they were excluded from the study. Three patients were found with suspicious lesions, one of whom claimed to have symptoms - a palpable mass in the right breast - and two who had neither symptoms nor palpable lumps; they were further evaluated using mammography, breast MRI, and ultrasound-guided breast biopsy. The remaining 5 patients had fibroadenomas-related masses, while 17 had cysts.

Conclusions: Although mammography is the gold standard for breast cancer screening, breast ultrasound is a very useful technique that is more accessible and affordable. Breast ultrasound can detect palpable lesions as well as characterize masses seen on mammography. This imaging technique can also detect axillary adenopathy, which is important in the staging of breast cancer.

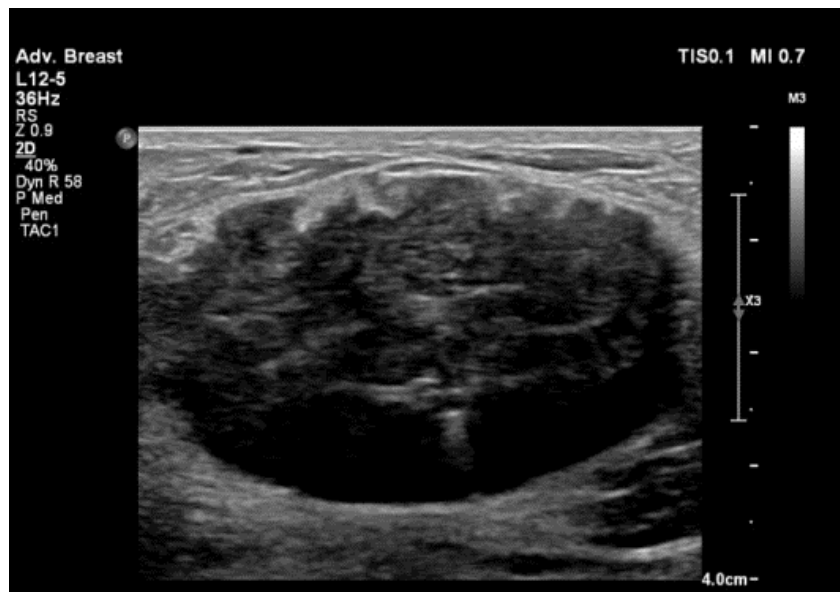
References

Harbeck N., Gnant M. Breast Cancer. Lancet. 2017;389:1134-1150. doi: 10.1016/S0140-6736(16)31891-8.

THE ROLE OF BREAST ULTRASOUND BREAST CANCER SCREENING



Small solid lesion found in the right breast.



Solid lesion that did was not palpable.

PECULIAR ULTRASONOGRAPHIC FINDINGS IN A PATIENT WITH FALCIFORM LIGAMENT NECROSIS FOLLOWING ACUTE CHOLECYSTITIS AND BILIARY PANCREATITIS

***Maria Luigia Vaiano*¹, Christian Jenssen²**

1. Gastroenterology and Endoscopy Department, Luigi Sacco University Hospital, Milan, Italy + EFSUMB Ultrasound Learning Center of Brandenburg Institute for Clinical Ultrasound (BICUS) at Medical University Brandenburg, Neuruppin, Germany, 2. Department of Internal Medicine - Krankenhaus Märkisch Oderland, Strausberg/Wriezen, Germany + EFSUMB Ultrasound Learning Center of Brandenburg Institute for Clinical Ultrasound (BICUS) at Medical University Brandenburg, Neuruppin, Germany

Abstract body

BACKGROUND: Necrosis of the falciform ligament is a rare condition that may be secondary to acute biliary and pancreatic inflammation or intra-abdominal infections but primary forms have also been reported.

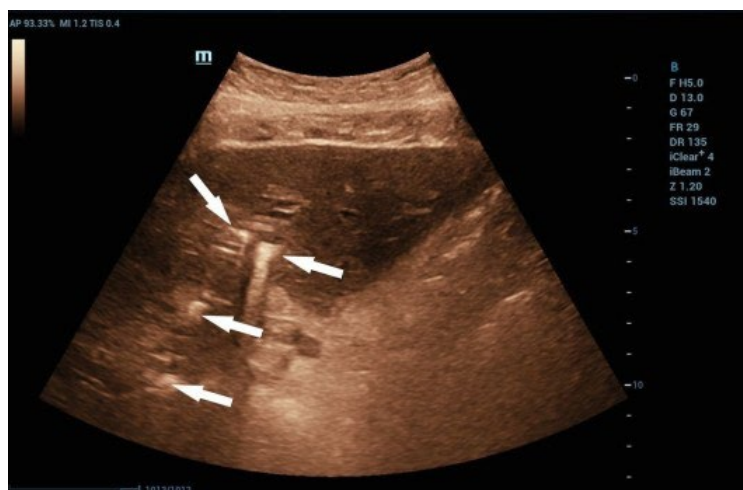
CASE REPORT: We present a 82-year-old woman admitted with acute onset of right abdominal pain and vomiting. Blood tests on arrival showed elevation of inflammatory markers, lipase and liver function tests. Ultrasound revealed acute cholecystitis, dilatation of intra and extrahepatic bile ducts, small amount of ascites and presence of air along the falciform ligament, hepatic hilum and left portal triad. Diagnostic paracentesis showed turbid fluid with significant elevation of white blood cells, cholesterol, albumin and lipase. Urgent endoscopic retrograde cholangiopancreatography (ERCP) was performed with extraction of a small stone impacted in the papilla. Cholangiography showed gas accumulation at the hepatic hilum and along the course but outside the lumen of left bile duct, corresponding well to sonographic findings. The patient underwent diagnostic laparoscopy and necrosis of the falciform ligament with peritonitis from Gram positive rods was found. A complete resection of the ligament and cholecystectomy were performed. Subsequent recovery was gradual and the patient was discharged on postoperative day fourteen.

CONCLUSIONS: Falciform ligament necrosis is challenging to diagnose, especially with ultrasound, due to the fact that there is no typical sonographic pattern. To date only a few cases have been reported and none of these described the presence of air inside the ligamentary structures secondary to infected necrosis, simulating intrahepatic aerobilia (pseudoaerobilia).

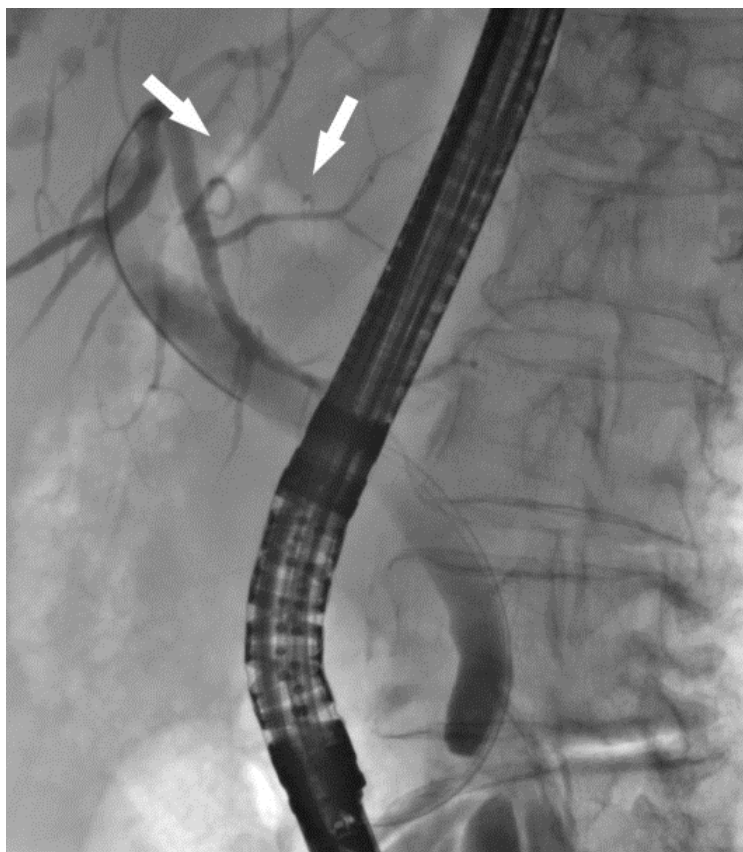
ACKNOWLEDGEMENTS: intraoperative images courtesy of N. Ekwelle.

References

PECULIAR ULTRASONOGRAPHIC FINDINGS IN A PATIENT WITH FALCIFORM LIGAMENT NECROSIS FOLLOWING ACUTE CHOLECYSTITIS AND BILIARY PANCREATITIS

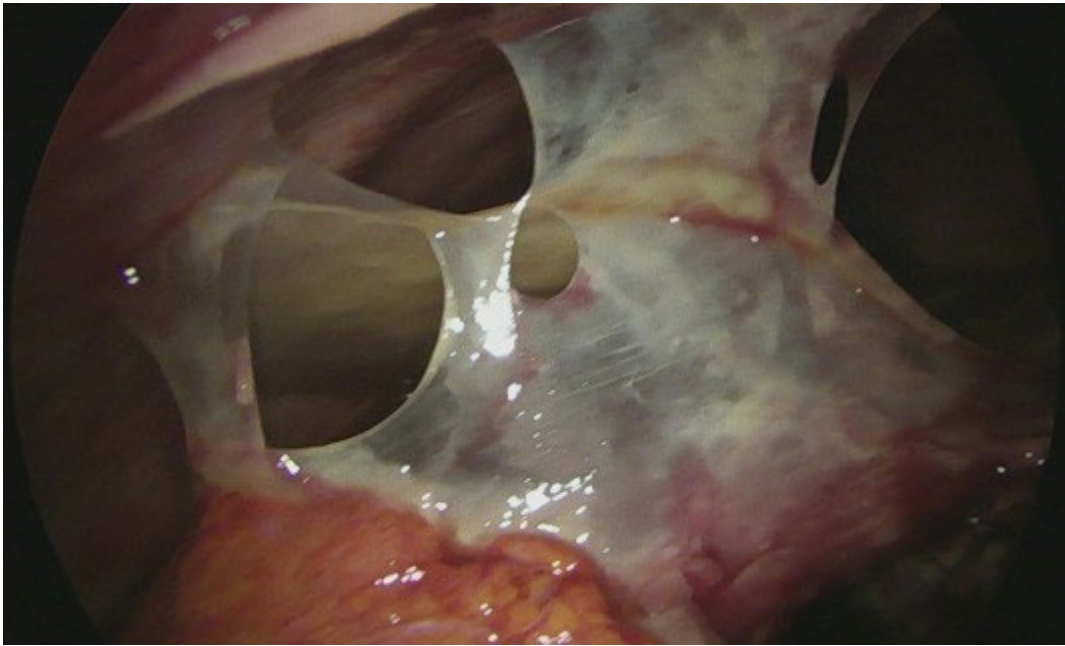


Air along the falciform ligament and left portal triad (arrows).



Gas accumulation outside the left bile duct (arrows).

PECULIAR ULTRASONOGRAPHIC FINDINGS IN A PATIENT WITH FALCIFORM LIGAMENT NECROSIS FOLLOWING ACUTE CHOLECYSTITIS AND BILIARY PANCREATITIS



Intraoperative finding of falciform ligament necrosis

SOFT TISSUE MASS. IS IT BENIGN OR MALIGNANT?

Lavinia Magdalena Fisteica¹

1. Caraiman Clinic Bucharest

Abstract body

70 year old patient presents with a palpable non-tender lump on the internal side of the right arm. She has a history of retro-peritoneal leiomyosarcoma in 2012 for which she has undergone surgery followed by Doxorubicine . She has tumor recurrence in 2022 at T8 vertebral level. Tumor was surgically removed and followed by radiotherapy.

References

1. Jacobson, Jon A. (Jon Arthur). Fundamentals of musculoskeletal ultrasound.
2. Palmer, Philip E. S., Breyer, B., Bruguera, C. A., Gharbi, H. A., Goldberg, B. B. et al. (1995). Manual of diagnostic ultrasound / edited by P. E. S. Palmer. World Health Organization.

Authors Index

Aabenhus, K.	98	Barr, R.	101
Adalbert, S.	99	Bartels, T.	42
Adiotomre, E.	116	Barth, G.	132
Adrian, S.	169	Bartoletti, D.	179
Adrian, V.	99	Batman, A.	93
Agaimy, A.	21	Bay Rask, K.	115
Agcaoglu, O.	90	Beilstein, B.	149
Ageev, F.	175	Belonenko, G.	183
Akiyama, I.	26	Bende, F.	75, 79, 190, 191, 195
Aksonova, O.	183	Bende , R.	75, 190, 191, 196
Aksonov, O.	183	Berek, J.	45
Alina Daniela, T.	169	Berger, A.	32
Altuntaş, Y.	93	Bernardes, R.	29
Amina, B.	22	Berzigotti, A.	78
Amzar, D.	91, 172	Besevicius, A.	142
Anand, J.	214	Bespalo vaite, L.	142
Ancusa, O.	170	Bhatia, A.	208
André, A.	29, 152	Bhattacharya, A.	208
Andrea, G.	117	Bieniek, J.	85
Anthony, A.	197	Binda, C.	65
Antil, N.	20, 45	BiondićŠpoljar, I.	46
Araceli, T.	106	Blackman, R.	41, 73
Atzori, S.	192	Blankova, Z.	175
Augustiniene, R.	219	Blehschmidt, R.	27
Auteri, G.	179	Bohr, C.	106, 109
Aydın, S.	48	Bojanić, K.	46
Aygün, N.	93	Borbe, T.	146
Aziz, S.	197	Borlea, A.	94, 155, ,159, 165, 167, 193, 194, 195
Babii,O.	67	Bossa , F.	68
Balakhonova, T.	173, 175, 176	Boten, D.	133, 149
Balas, M.	91, 172	Boyke, Z.	181
Baltgaile, G.	236	Bradigan, K.	41
Bandurska, E.	181	Brandt, M.	106

Brebu, D.	195	Cornianu, M.	172, 222
Briede, I.	55	Cortellini, F.	65
Brkljačić, B.	46	Coskun, E.	90
Brodzisz, A.	140, 141	Cotrau, R.	75, 190,
Bubnov, R.	162, 189	Cristian, O.	80
Buda, E.	163	Cruz, A.	29
Budzyńska, J.	140, 141	Cubisino, R.	68
Bulum, A.	46	Czarnecki, A.	135
Bulum, M.	46	Czeczewski, M.	135
Bura, A.	100	Daniela, I.	80
Burdan, A.	75, 127, 190, 191,	Daum, N.	131, 132, 133, 134, 149, 160
Cadar, A.	136	Debreceeni, O.	76
Calamar-Popovici, D.	170	Decheva, A.	104
Çamurcuoğlu, E.	93	De Chiara, F.	59, 71,
Cantisani, V.	59, 71, 88, 92, 101	de Hoop, H.	119
Carparelli, S.	68	DE, J.	124
Castanheira, J.	152	Delaney, L.	28, 33, 209
Cavo, M.	179	Del Gaudio, G.	88, 92
CB, L.	124	De Lucia, D.	59, 71
Cekauskas, A.	230	Diana Luminita, M.	38, 80
Cekuolis, A.	237	Diana, M.	243
Čekuolis, A.	220, 224	Di Bella, C.	92
C, F.	124	Dietrich, C.	120, 121
Chatzioannou, M.	129	Di Pietro, C.	179
Cheda, M.	54	Di Serafino, M.	59, 71
Cheng, J.	58	Divjak, E.	46
Chirilă, C.	136	Dogan, B.	32
Christian, K.	31	Dogan, H.	90
Ciećko, W.	181	Doina, H.	240
Cil, B.	90	Dolcetti, V.	88, 92
Civan, J.	188	Dominik Antonius, S.	134
Cocomazzi, F.	68	Dong, Y.	23
Codreanu, S.	136	Drelich, K.	140, 141
Coelho, R.	126	Drelich-Zbroja, A.	54, 125, 130, 147
Colakoglu, B.	90	Drożdż, D.	85
Coluccio, C.	65	Durães, R.	29

Durmaz, S.	93		
Dutta, U.	208	FS, R.	124
Dynnyk, O.	35, 49, 67, 72, 74, 216	Fedusenko jr., A.	49
Eberhard, K.	98	Fedusenko, O.	49
Eder, N.	134, 160	Fedusenko, O.	74
Eisenbrey, J.	178, 188	Galev, I.	104
Ekmekcioglu, Ö.	93	Gallo, A.	166
Elena Laura, I.	240	Garrido, I.	126
Elena Simona, I.	169, 240	Gecaite - Paukste, I.	144, 233
Eleonora, P.	88	Georgescu, D.	170
Emil Radu, I.	80	Gerstenmeier, P.	201
Emil Robert, S.	38, 80, 243	Giamperoli, A.	174
Emil, Z.	31	Gilja, O.	64
Engl, P.	42	Giorgia, P.	88
Esengur, O.	90	Giovanni, D.	88
Eskild, T.	184	Gircius, R.	234
Esposito, C.	151	Gittinger, F.	120
Eugenia Laura, L.	95, 203	Giuseppe, L.	88
Evans, R.	28	Gliga, M.	136
Fabbri, C.	65	Golu, I.	78, 172, 222
Falatah, H.	178, 209	Grinbergs, P.	55
Fallon, S.	32	Guchaeva, D.	176
Felix-Mihai, M.	99	Guglielmo, F.	188
Fetzer, D.	73, 78	Gunduz, Y.	108
Figueiredo, J.	152	Guneyli, S.	90
Finch, L.	73	Gupta, P.	208
Fisher, G.	420	Guzik, P.	181
Fisteica, L.	248	Haavardsholm, E.	184
Flaviu, B.	99	Haenle, M.	27, 218
Florin, B.	38	Haiko, O.	239
Fofanova, T.	175	Hammer, H.	184
Folkins, A.	45	Harrison, G.	103
Foncea, C.	75, 79, 127, 190, 191, 196	Harwood, M.	41
Forgione, A.	174	Hassoy, H.	90
Forsberg, F.	25, 28, 32, 33, 41, 151, 188, 209, 214, 215	Heredea, D.	190, 191
		Hickok, N.	28, 33, 209

Hilliard, R.	28	Kamaya, A.	20, 73, 78
H.J. van Hal, V.	119	Karin, H.	31
Hofmann, T.	131, 132	Karoliussen, L.	184
Holst Hahn, C.	17	Khamchieva, L.	173
Horlenko, O.	62	Khan, A.	116
Hoy, M.	2416	Khmaladze, E.	60, 210
Hristov, D.	20	Kim, G.	151
Hulson, O.	116	Kimyonok, H.	108
Icma, I.	172, 195	Ķīse, L.	242
Ioan, S.	79, 94	Klimchuk, L.	239
Ionita, I.	170	Kliokytė, R.	226
Ippolito, A.	68	Klitmøller Agander, T.	17
Isajeva, L.	242	Kobyliak, N.	72, 74
Isguven, S.	28, 33, 209	Kokenge, M.	27
Ivanac, G.	46	Kono, Y.	73, 78
Jakowlew Wessman , M.	115	Kopyto, E.	135
Jankauskas, A.	100	Kopyto, M.	135
Jargielto, T.	125	Kosiak, W.	113
Jaworek, P.	51, 181	Kozioł, I.	140, 141
Jenderka, K.	42	Kozlov, S.	173
Jenssen, C.	134, 148, 160, 245	Kraft, W.	25
Jesper, D.	21	Kratzer, W.	27, 218
Jian, W.	186	Kraus, B.	103
Jocius, D.	230, 231	Kristensen, T.	115
Jorge, S.	152	Krutz, A.	132, 146
Jung, C.	65	Kuczyńska, M.	54, 125, 130, 135, 147
Jung, E.	109	Kuhn, E.	106
Jurevicius, T.	102	Künzel, J.	106, 109
K, A.	124	Kurtz, S.	28, 33
Kabaalioglu, A.	90	Kurz, E.	42
Kada, h.	22	Lacerda, Q.	33, 178
Kaffas, A.	4, 4, 29, 29	Lācis, A.	55
Kalashnikov, V.	198	Lapham, R.	116
Kaliy, V.	76	Lapidus, I.	242
Kaltoft, M.	17	Lauff, J.	201
Kaman, L.	208	Laukiene, R.	231

Lavinia, L.	169	Malça, C.	29
Lazar, M.	32	Mancianti, N.	117
Ledas, G.	144	Marinov, V.	104
Lee, C.	215	Marra, A.	68
Lekienė, I.	145	Massimo, B.	117
Leśniewska, M.	140, 141	Matafome, P.	152
Levine, R.	186	Materek, M.	54
Liao, L.	19	Matuszek, M.	135
Liepa, M.	123	Mayer, H.	151
Lighezan, D.	170	Mazzoni, C.	179
Ligia, P.	99	McClure, P.	214
Linhart, P.	218	Medellin , A.	73, 78
Lioznovs, A.	55	Melchioris, J.	98
Liro, M.	181	Melling, P.	116
Liu, J.	25, 32, 178, 188, 215	Melnikov, I.	173
Liu, K.	25	Melnichenko, Y.	72
Liverani, E.	65	Memiş, B.	93
Livkutnyk, O.	72	Meyer, T.	42
Li, Y.	206	Mickevičienė, L.	227
Lo, H.	133	Mielnik, W.	130, 140, 141
Longacre, T.	45	Mihaela, V.	95, 203
Long, S.	214	Mihuta, M.	193, 194
Lopata, R.	119	Mikelienė, M.	139
Luchko, R.	239	Mikelis, K.	229
Ludwig, M.	201	Mikelsone, M.	123
Lukianchuk, V.	35, 216	Miklaszewska, M.	85
Luksaite - Lukste, R.	62, 138	Mikos, E.	135
Lupusoru , R.	79, 127, 190	Mircea, I.	240
Lutz, A.	20, 45	Mitraite, D.	100, 168
Lyoncheva-Kaneva, K.	104	Moczulska, A.	85
Lyshchik, A.	41, 78	Moga, T.	75, 91, 127
Macedo , G.	126	Moisa Luca, L.	167
Machado, P.	25, 28, 32, ,33, 151, 214, 215	Mondelli, A.	166
Mahmutoglu, A.	108	Morrell, A.	116
Makarova, Z.	49	Mota , I.	199
Makouei , F.	17, 115	Mugur, G.	240

Mukhomor, O.	162, 189	Pitkēviča, I.	242
Mulazzani, L.	174	Planz, V.	78
Muliulis, I.	235	Ploeanu, A.	190, 191
Muller, J.	119	Pogorelova, O.	173, 175, 176
Müller, L.	201	Pomeranz, C.	41
Nahar, U.	208	Pomiećko, A.	82
Narbutis, Z.	123	Popa, A.	155, 159, 165, 167, 195
Nassisi, V.	68	Popa, O.	222
Nazarian, L.	41, 214	Popescu, A.	75, 79, 91, 127, 155, 159, 165, 190, 191, 195, 196
Needleman, L.	32, 215	Poskus, T.	62
Nepomniaščis, D.	138	Prakash, M.	163
Niciporuka, R.	123	Prieditis, P.	123
Nieoczym, K.	135	Pucetaite, M.	168
Nitta, N.	26	Puiu, A.	137
Nulle, K.	43, 52	Pushkarenko, O.	76, 198, 238
Nürnberg, D.	133, 134, 148, 160	Pushkarenko, V.	76
Nylund, K.	64	Pustelniak, O.	140, 141, 147
Oraevska, I.	74	Rācene, L.	242
Ostapenko, A.	231	Radu, C.	75, 79, 127, 190
Özel, A.	93	Radzina, M.	55, 123
Ozolins, A.	123	Rajski, R.	34
Pacini, P.	88, 92	Ratniece, M.	123
Paglia, S.	179	Razvan, R.	240
Palandri, F.	179	Razvan, S.	169, 240
Palionis, D.	227	Remus, C.	134, 146
Palmino, S.	117	Renda, M.	92
Pascu, A.	75, 127	Rezeberga, D.	242
Paul, C.	193, 194	Ribeiro, A.	29
Pavlovics, S.	123	Rifu, K.	26
Pedersen, M.	103, 213	Rink, M.	109
Perri, F.	68	Rodgers, S.	73, 78
Petkevicius, J.	102	Roi, C.	193, 194
Pierre, S.	116	Rosca, C.	170
Pinna, R.	192	Roseiro, L.	29
Pirmoazen, A.	20	Rostoka, Z.	242
Piscaglia, F.	73, 78, 174, 179		

Roxana, I.	38, 80, 157, 243	Simona, C.	38
Ruda, M.	176	Sinha, A.	163
Ryskiene, S.	168	Sirli, R.	75, 79, 127, 155, 159, 190, 191, 196
Sack, I.	42	Slobodníková, J.	50
Saenger, S.	131, 132	Smedemark, S.	124
Sakalauskas, A.	171	Smirnova, M.	175
Samuilis, A.	227	Smith, J.	116
Sandhu, M.	208	Sniadecki, M.	51, 181
Sänger, S.	149	Sojka, M.	125
Sansone, V.	174, 179	Solaini, L.	65
Santos, F.	29	Solito, C.	92
Santos, R.	103	SON, J.	207
Sārta, B.	242	Soundararajan, R.	163, 208
Sasanuma, H.	26	Sporea, I.	75, 79, 94, 127, 155, 159, 165, 167, 190, 191
Sbrancia, M.	65	Squatrino, G.	68
Schaer, T.	28	Stanczak, M.	25
Schebsch, K.M.	106	Stan Voicu, M.	75
Schellhaas, B.	21	Stasiak, M.	181
Schiefke, I.	120	Stępnia, K.	135
Schultz, M.	42	Stevens, W.	116
Schulze, S.	42	Stöhr, F.	201
Schwab, H.	119	Stoian, D.	94, 165, 167, 193, 194, 195
Schwesig, R.	42	Strobel, D.	21
Seckinger, D.	134	Svirida, O.	175
Şenbil, D.	48	Szalek, J.	181
Serbetci, E.	108	Tahmasebi, A.	32, 188
Serednia, I.	72	Takayama, N.	26
Sergio, T.	117	Tanco, M.	24, 107
Serra, C.	65	Taniguchi, N.	26
Shah, K.	214	Tarasevicius, R.	168
Shakhnovich, R.	176	Tavares, J.	152
Shevchenko, B.	67	Teresius, N.	62
Sidek, N.	197	Terracciano, .	68
Sidhu, P.	78	Terslev, L.	184
Silva, M.	29	Terzi, E.	174
Simanauskiene, E.	237		

Tezelman, S.	90	Weimer, A.	201
Tichauer, K.	25	Weimer, J.	201
Todsen, T.	17, 98, 115	Wessel, I.	17
Tofolean, I.	24, 107	Wessner, C.	41, 73, 178, 188
Toft Kristensen, T.	115	Wieczorek, T.	120
Toma, A.	91, 110, 222	Willis, A.	32
Tovoli, F.	179	Wilson, S.	73, 78
Trip, D.	191	Wong, H.	197
Tripoten, M.	173, 175, 176	Woźniak, M.	140, 141
Tsverava, D.	217	Xavier, W.	29
Tzonev, R.	104	Yang, Y.	201
Tzschätzsch, H.	42	Yarovaya, E.	175
Uhlig, T.	184	Yer, M.	108
Uludağ, M.	93	Yerokhovych, V.	72
Vaiano, M.	245	Yuzvenko, V.	72
Vaičiūnienė, R.	100	Zachwieja, K.	85
Vaišnytė, B.	227	Zakrevska, S.	74
Vaitkus, S.	168	Zarajczyk, A.	54
Vallone, G.	59, 71	Zaychenko, Y.	199
Valvano, R.	68	Zbroja, M.	130, 140, 141
van Sambeek, M.	119	Zeiger, I.	146, 148, 160
Varcus, F.	222	Zhaivoronok, M.	72, 74
Vecvagare, A.	242	Zhelov, V.	238
Vedmedovska, N.	242	Žilevičė, L.	232
Venclauskiene, A.	102	Zundler, S.	21
Vianelli, N.	179		
Vidili, G.	192		
Vlad, M.	91, 110, 172, 222		
Volodkoviciene, D.	70		
Vu, T.	151		
Walisiewicz, P.	82, 113		
Wallace, K.	151		
Wang, H.	45		
Wang, S.	188		
Warm, J.	98		
Weil, A.	201		